Preliminary Results of the Use of a Robotic System in Spine Surgery

Resultados preliminares da utilização do sistema robótico na cirurgia da coluna vertebral

Helton Luiz A. Defino[1] Vinicius Marques Carneiro[2] Matheus Pippa Defino[1] Rian Souza Vieira[1] Thiago Dorigão[1] Denylson Sanches Fernandes[2]

[1] Department of Orthopedics and Anesthesiology, Faculdade de Medicina de Ribeirão Preto, Universidade de São Paulo, Ribeirão Preto, SP, Brazil
[2] Neurosurgery Division, Department of Surgery and Anatomy, Faculdade de Medicina de Ribeirão Preto, Universidade de São Paulo, Ribeirão Preto, SP, Brazil

Address for correspondence Helton Luiz A. Defino, Departamento de Ortopedia e Anestesiologia, Faculdade de Medicina de Ribeirão Preto, Universidade de São Paulo, Avenida Bandeirantes 3.900, Ribeirão Preto, SP,CEP: 14049-900, Brazil (e-mail: hladefin@fmrp.usp.br).

Rev Bras Ortop 2026;61(4):s00461825768.

Abstract

Objective To evaluate the preliminary results of the use of the robotic system in spinal surgery.

Methods The current prospective study included patients undergoing spinal surgery since the introduction of the robotic system (Mazor X Stealth Edition, Medtronic plc). The study evaluated the time to record the patient's anatomy, the fluoroscopy time, radiation dose, implant insertion time, implant accuracy, and complications.

Results The study assessed 67 patients who received 415 pedicle screws (98 thoracic, 284 lumbar, 1 in a transitional vertebra, and 32 sacral). The time to record the patient's anatomy ranged from 4 to 71 (mean: 16.93 ± 12.49) minutes. The fluoroscopy time ranged from 2.3 to 71.20 (mean: 12.91 ± 11.52) seconds. The amount of radiation administered during the surgical procedure ranged from 0.38 to 12.89 (mean: 3.78 ± 3.29) mGy. The time required for implant insertion into the pedicles ranged from 102 to 323 (mean: 147.90 ± 45.09) seconds. In the axial plane, 95.65% of the implants were types A or B on the Gertzbein-Robbins scale, and, in the sagittal plane, 96.38%. No cases required abandonment of the robotic system. As a complication, one patient developed a neurological deficit.

Conclusion The robotic system demonstrated high accuracy in implant placement and, with increasing experience in its use, was associated with reductions in fluoroscopy time, intraoperative radiation exposure, and the time to record the patient's anatomy.

Keywords
- pedicle screw
- robotics
- robotic surgical procedures
- spine

* *Study performed at the Department of Orthopedics and Anesthesiology, Faculdade de Medicina de Ribeirão Preto, Universidade de São Paulo, Ribeirão Preto, SP, Brazil.*

received
November 30, 2025
accepted
January 30, 2026

DOI https://doi.org/10.1055/s-0046-1825768.
ISSN 0102-3616.

© 2026. The Author(s).
This is an open access article published by Thieme under the terms of the Creative Commons Attribution 4.0 International License, permitting copying and reproduction so long as the original work is given appropriate credit (https://creativecommons.org/licenses/by/4.0/)

Thieme Revinter Publicações Ltda., Rua Rego Freitas, 175, loja 1, República, São Paulo, SP, CEP 01220-010, Brazil

Resumo

Objetivo Avaliar os resultados preliminares da utilização do sistema robótico na cirurgia da coluna vertebral.

Métodos Realizamos um estudo da série de pacientes operados prospectivamente desde a introdução do sistema robótico (Mazor X Stealth Edition, Medtronic plc) na cirurgia da coluna vertebral. Foram avaliados o tempo de registro da anatomia do paciente, o tempo de fluoroscopia, a quantidade de radiação, o tempo de inserção dos implantes, a acurácia dos implantes e as complicações.

Resultados Foram avaliados 67 pacientes, nos quais foram implantados 415 parafusos pediculares (98 torácicos, 284 lombares, 1 em vértebra de transição e 32 sacrais). O tempo de registro da anatomia do paciente variou de 4 a 71 (média: 16,93 ± 12,49) minutos. O tempo de fluoroscopia variou de 2,3 a 71,20 (média: 12,91 ± 11,52) segundos. A quantidade de radiação utilizada durante o procedimento cirúrgico variou de 0,38 a 12,89 (média: 3,78 ± 3,29) mGy. O tempo da inserção dos implantes no interior dos pedículos variou de 102 a 323 (média: 147,90 ± 45,09) segundos. No plano axial, 95,65% dos implantes eram dos tipos A ou B na escala de Gertzbein-Robbins, e no plano sagital, 96,38%. Não houve abandono do sistema robótico em nenhum paciente. Déficit neurológico foi observado em um paciente.

Conclusão A utilização do sistema robótico apresentou grande precisão na colocação dos implantes, tempo reduzido da utilização da fluoroscopia, quantidade reduzida da radiação intraoperatória, e o tempo de registro da anatomia do paciente apresentou redução com a aquisição de experiência com a utilização do sistema robótico.

Palavras-chave

- coluna vertebral
- parafusos pediculares
- procedimentos cirúrgicos robóticos
- robótica

Introduction

Robotic systems were originally developed to increase the accuracy of pedicle screw placement in the spine.[1,2] The advent of minimally-invasive spine surgery further accelerated their development, leading to the introduction of several platforms.[2–4] The robotic systems most frequently used for pedicle screw placement are the ExcelsiusGPS (Globus Medical, Inc.), Mazor X (Medtronic plc), and ROSA One (Zimmer Biomet)[5–7] (►**Fig. 1**).

Robotic systems have enabled implant placement within the vertebral pedicle with greater accuracy and a significant reduction in radiation exposure due to decreased use of intraoperative fluoroscopy.[8–11] Additional advantages, including shorter recovery time, lower complication rates compared to traditional open surgery, shorter hospital stay, and lower infection rates, have also been reported.[4,5,12,13]

The implementation of robotic systems in spine surgery requires a learning period, with a recommendation for an acclimatization period with the equipment to facilitate their adoption.[12,14,15]

Our institution began using a robotic system in spine surgery in June 2024. The objective of the current study was to evaluate the preliminary results of its consecutive use in different spine procedures and conditions.

Methods

The Local Research Ethics Committee approved the present cross-sectional study under the number CAAE 88934425.9.0000.5440. The study included 67 consecutive patients undergoing spinal surgery using the robotic system (Mazor X Stealth Edition; Medtronic plc) from June 2024 to July 2025.

The robotic system used in the current study (►**Fig. 1**) is an enhanced version of the system originally developed in Israel in 2018.[7] This system integrates robotic guidance with the intraoperative navigation system. The platform features a robotic arm with six degrees of freedom, which guides surgical instruments during pilot hole preparation, tapping, and implant placement. Preoperative planning enables the selection of implant dimensions and placement within the vertebra (►**Fig. 2**). During surgery, the reference device (clamps or Schanz pins) is attached to the spinous processes or the posterior superior iliac spine. After system setup, image registration, and image fusion, the surgical plan is transferred into the robotic system. Next, the target vertebra is selected, and the robotic arm prepares the pilot hole and places the implant. The robotic arm is also integrated with the navigation system to monitor the surgical steps related to pilot-hole preparation and implant placement (►**Fig. 3**).

Preoperative planning for implant use (length, diameter, and position within the vertebral pedicle) and final assembly of the fixation constructs were performed using preoperative thin-slice (1 mm) computed tomography (CT). Intraoperatively, fluoroscopic images (anteroposterior [AP] and oblique views) were acquired after patient positioning and robotic system setup (attachment and adjustment). The intraoperative fluoroscopic images were fused with the preoperative CT images. This image integration enables the robotic system to perform pilot-



Fig. 1 Mazor X Stealth Edition robotic system (Medtronic plc).

hole preparation, tapping, and pedicle screw placement without the need for continuous intraoperative fluoroscopy. All surgeries employed a posterior approach using a midline incision.

The assessed parameters included the time to record the patient's anatomy, intraoperative fluoroscopy time, intraoperative radiation dose (in mGy), implant insertion time, pedicle screw accuracy, and complications (abandonment of the technique, neurological deficit, and adverse events).

The evaluation of pedicle screw accuracy in the sagittal and axial planes used the Gertzbein-Robbins classification:[16] A –screw completely within the pedicle without cortical breach; B – cortical breach < 2 mm; C – breach ranging from 2 to 4 mm; D – breach ranging from 4 to 6 mm; and E

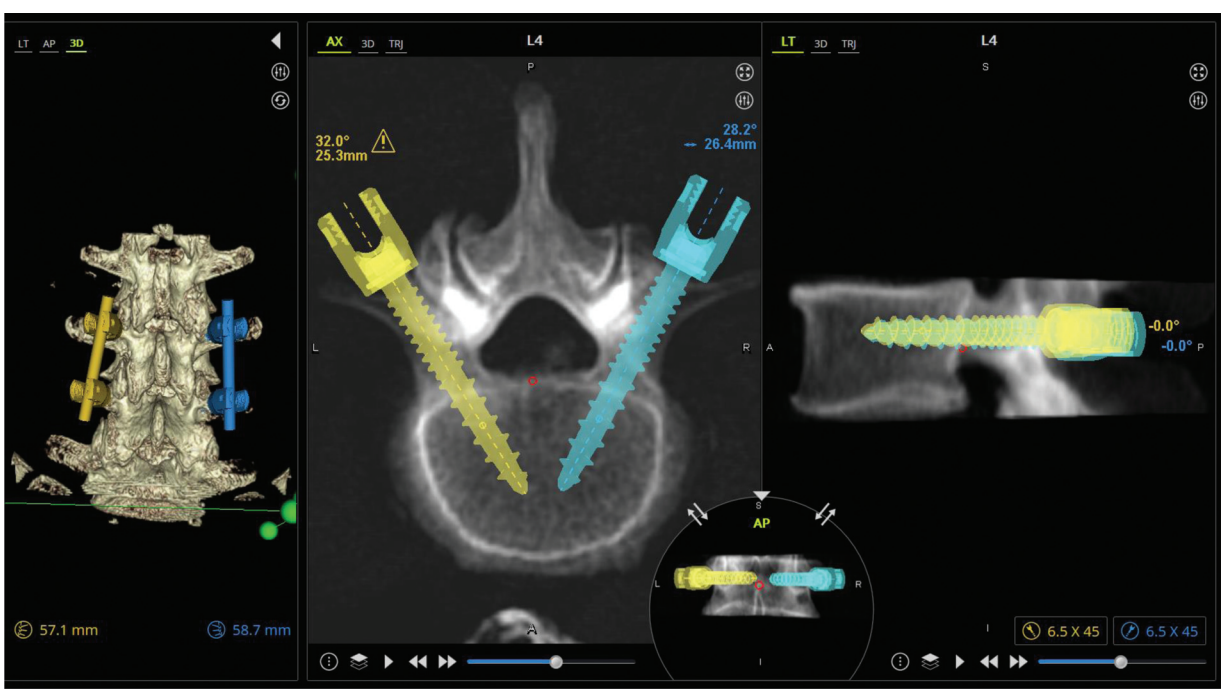

Fig. 2 Preoperative planning illustrating implant positioning and assembly of the fixation construct.

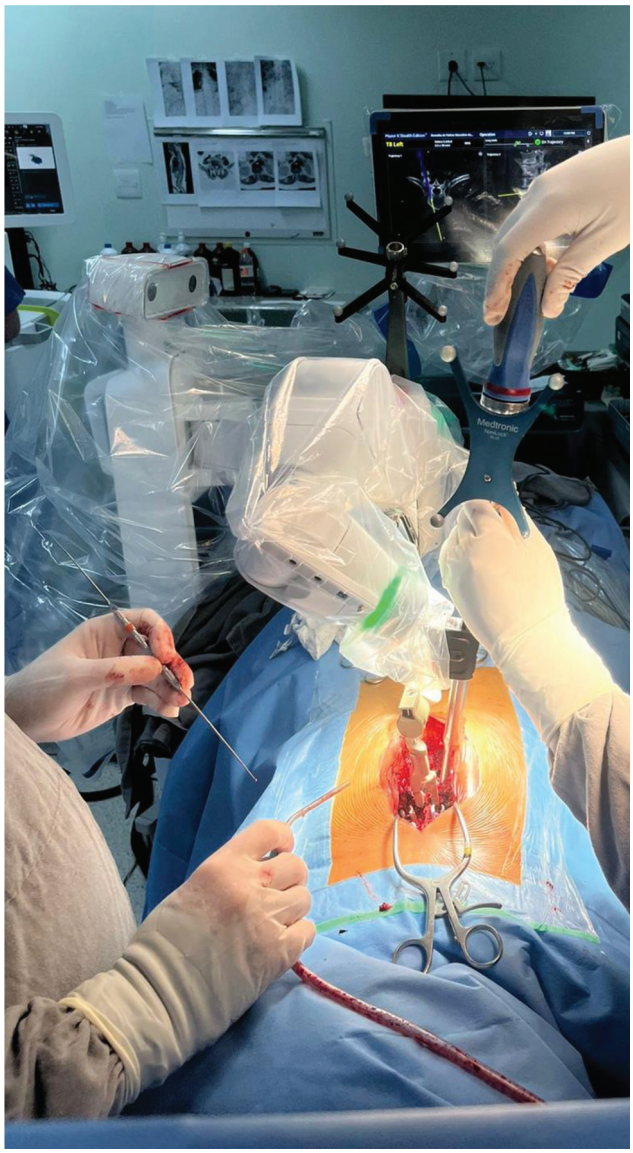

Fig. 3 Intraoperative photograph illustrating implant placement with assistance of the robotic arm and visualization through the navigation system.

– breach > 6 mm. According to location, the breach was classified as: 1–medial; 2–lateral; 3–superior; and 4–inferior (►**Fig. 4**).

The statistical analysis was performed using descriptive statistics. Sample normality was assessed using the Kolmogorov-Smirnov test, and comparisons among parameters were performed using the Kruskal-Wallis test. The significance level was set at 5% ($p < 0.05$).

Results

The current study assessed 67 (28 male and 39 female) patients with ages ranging from 12 to 88 (mean age: 59.81 ± 16.29) patients. A total of 415 pedicles (98 thoracic, 284 lumbar, 1 in a transitional vertebra, and 32 sacral) underwent screw insertion. ►**Fig. 5** shows the distribution of pedicle screws across the different levels.

The process and duration of the recording of the patient's anatomy by the robotic system, as well as its interaction with preoperative planning, are referred to as the *registration time*, which depends on the type of system used, the surgical team's experience, and procedural complexity. Registration time ranged from 4 to 71 (mean: 16.93 ± 12.49) minutes. Registration times were longer in patients with difficulty in image acquisition due to obesity, poor bone quality, or deformity. ►**Fig. 6** illustrates the registration time throughout the use of the robotic system. Registration time decreased as the experience with the robotic system increased. The registration time for the first 20 procedures showed a statistically significant difference (Kruskal-Wallis test: $p < 0.05$) compared with subsequent procedures (►**Fig. 6**).

Fluoroscopy time ranged from 2.3 to 71.20 (mean: 12.91 ± 11.52) seconds. The amount of radiation used during the surgical procedure ranged from 0.38 to 12.89 (mean: 3.78 ± 3.29) mGy. These parameters demonstrate the low radiation exposure associated with the use of the robotic system (►**Fig. 7**).

Implant insertion time within the pedicles ranged from 102 to 323 (mean: 147.90 ± 45.09) seconds (►**Fig. 8**). The figure illustrates the implant insertion time; no statistically significant difference was observed in insertion time between thoracic and lumbar vertebrae or between the first 20 procedures and subsequent procedures (Kruskal-Wallis test: $p > 0{,}05$).

Pedicle screw accuracy in the axial plane according to the Gertzbein-Robbins classification[16] was as follows: A in 85.54%; B in 10.11%; C in 2.4%; D in 0.72%; and E in 1.2%. Grades A and B of the Gertzbein-Robbins classification are an acceptable standard of accuracy and were observed in 95.65% of the implants in the axial plane and in 96.38% of those in the sagittal plane (►**Fig. 9** and ►**Table 1**).

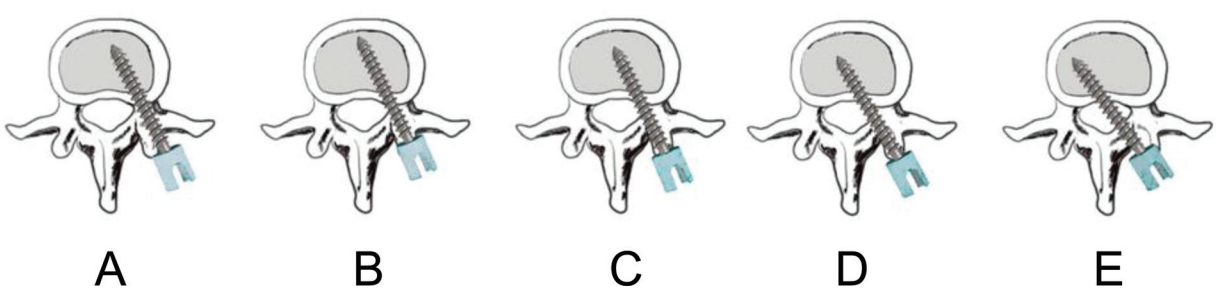

Fig. 4 Gertzbein-Robbins classification.

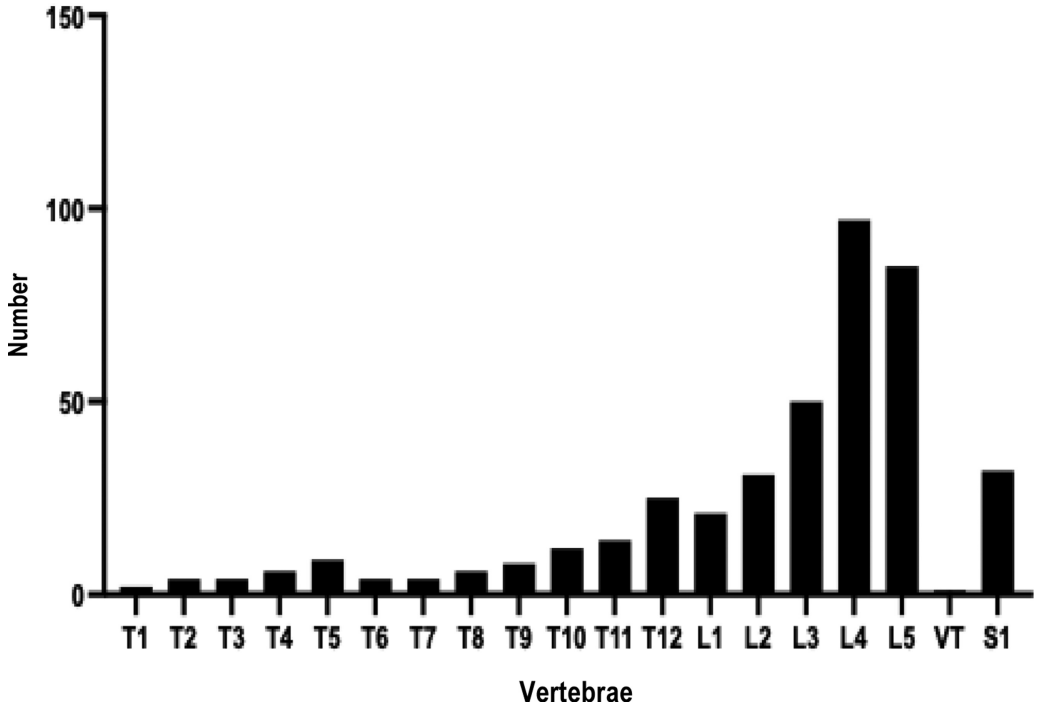

Fig. 5 Distribution of the number of pedicles evaluated in the vertebral column.

All procedures planned for robotic system use were completed, with no robotic system abandonment in this patient series. One patient presented with a nerve root injury resulting in unilateral sensory and motor deficit due to perforation of the vertebral canal. The neurological injury resulted from unilateral displacement of a portion of the fractured osteoporotic vertebra (previously treated with kyphoplasty), which interfered with the image registration process.

Discussion

The use of robotic systems requires learning and experience, similarly to the adoption of other new technologies.[17,18] The learning curve for robotic systems in spine surgery mainly relates to registration time and implant accuracy. Accurate registration is essential for the robotic system to correctly position surgical instruments and place implants precisely within the vertebrae.[15,18]

The difference in registration time between the first 20 procedures and the subsequent procedures performed in our patient series corroborates the importance of the learning curve, which is consistent with previous reports that registration time decreases as the number of procedures increases.[15,18,19]

The literature describes a considerable variation in the duration of the learning curve for robotic systems used in spine surgery, using parameters such as procedure time,

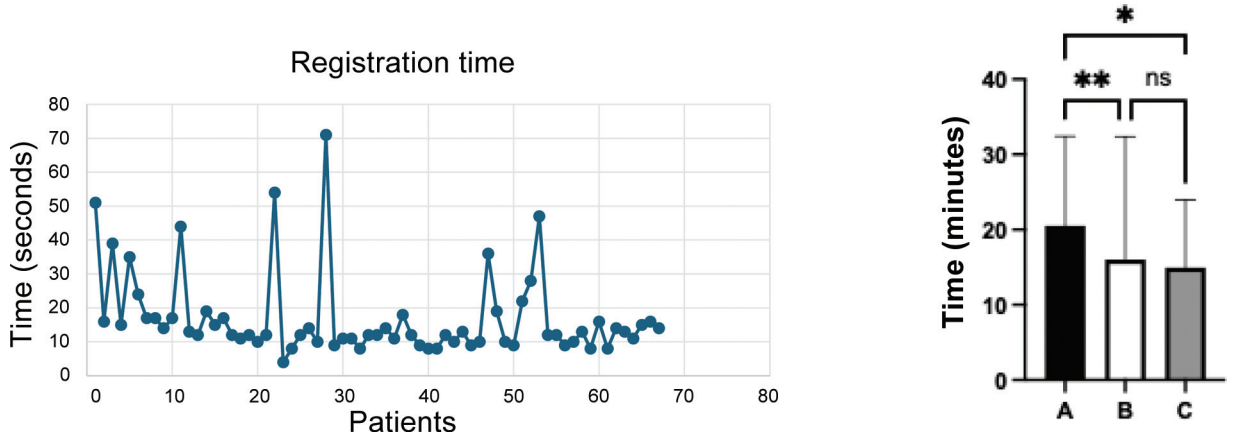

Fig. 6 Registration time throughout the use of the robotic system and comparison of registration time in the subgroups of 20 operated patients. Note the statistically significant difference in registration time between the first 20 and the subsequent patients (Kruskal-Wallis test: $p < 0.05$; the asterisk indicates statistical significance).

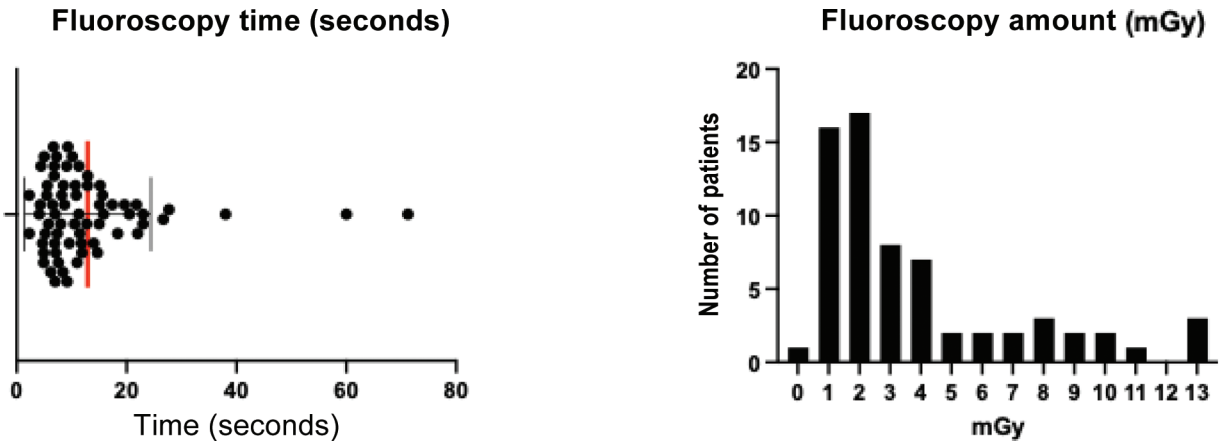

Fig. 7 Intraoperative fluoroscopy time (seconds) and radiation dose (mGy).

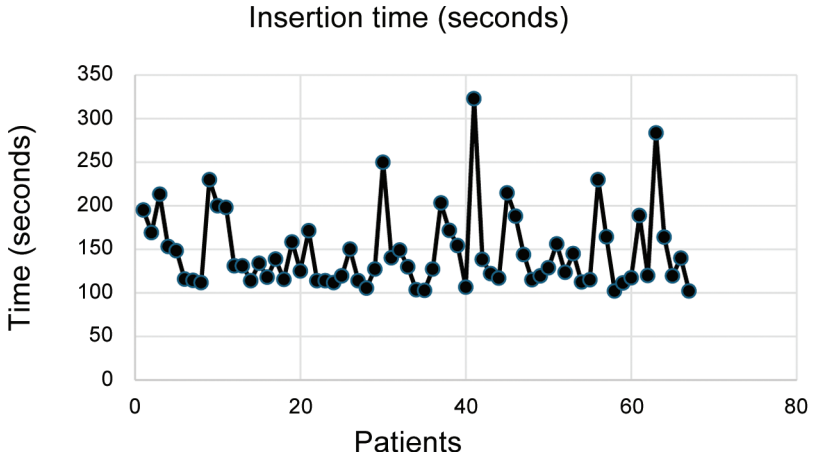

Fig. 8 Implant insertion time.

registration time, implant insertion time, and implant accuracy for its evaluation.[7,12,18,19] To date, the number of procedures required to overcome the learning curve has not been clearly established. Despite the reports of improved accuracy after 17, 18, 20, 25, or 30 procedures, some studies state that a learning curve may not be necessary.[8,12,18–20] Our results confirm the existence of a learning curve for robotic systems in spine surgery, with a significant reduction

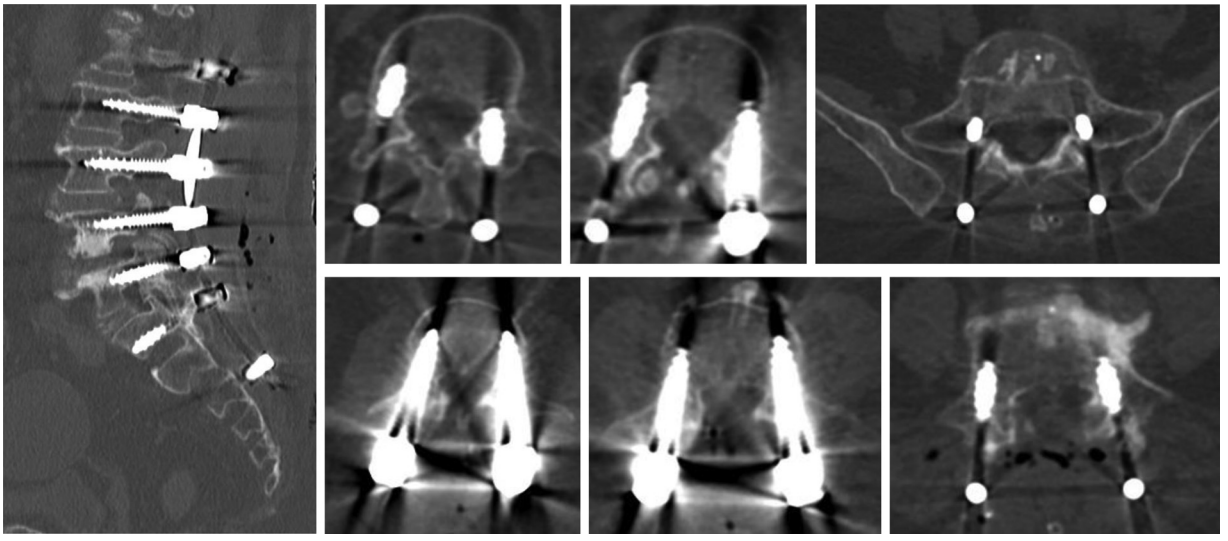

Fig. 9 Postoperative computed tomography scan illustrating the accuracy of implant placement.

Table 1 Accuracy of implants in the axial and sagittal planes

Axial plane			Sagittal plane		
Type	Number	%	Type	Number	%
A	355	85.54	A	400	96.38
B1	36	8.67	B3	1	0.24
B2	6	1.44	B4	12	2.89
C1	7	1.68	C3	2	0.48
C2	3	0.72	C4	0	0
D1	1	0.24	D3	0	0
D2	2	0.48	D4	0	0
E1	1	0.24	E3	0	0
E2	4	0.96	E4	0	0

in registration time after 20 procedures. Implant accuracy, registration time, and operative time improved with increasing use of and familiarity with the system. In addition, they are related to patient characteristics (obesity, osteoporosis, presence of implants), the type of procedure (deformity, multilevel surgery), and its location (thoracic, lumbar, sacral, or iliac spine).[15]

Hyun et al.[8] mentioned the implant insertion time as another parameter of the learning curve, reporting reductions throughout the use of robotic systems. However, this parameter did not show a statistically significant difference during the temporal progression of procedures of the patients analyzed, nor between the thoracic and lumbar segments.

The robotic system provided high accuracy of pedicle screw placement. Its superiority compared with freehand placement and CT- or O-arm-based navigation represents one of its main advantages.[3,5,12,21] Grades A and B of the Gertzbein-Robbins classification[16] are good standards to evaluate implant accuracy, and the percentages obtained in the present study (95.65% for implants in the axial plane and 96.38% for those in the sagittal plane) are consistent with the relevant literature.[5–7,9,22]

Despite this high level of accuracy, 5.79% of the implants in the axial plane and 3.32% of those in the sagittal plane did not meet the acceptable accuracy criteria (A or B). The use of robotic systems may result in implant malposition and adverse events.[23,24] The implant malposition observed during this initial phase of robotic system use resulted from problems with registration and integration of preoperative images, soft-tissue retraction when using the robotic system, and displacement of a fragment of a fractured vertebra. However, we observed situations in which the vertebral pedicles were very small, and the robotic system enabled precise implant placement, superior to the potential result obtained using fluoroscopy alone. No patient from our series required reoperation for screw repositioning. Implant malposition did not result in neurological injury. The single neurological injury occurred during pilot-hole preparation, with no implant insertion.

Implant malposition associated with the use of robotic systems has been reported in 0.8% of procedures, with no change in this rate during or after the learning curve. However, the present study, in particular, did not employ CT.[14] A study using CT for evaluation reported a higher percentage (15.7%).[25] The evaluation of results obtained with robotic systems should consider the generation and evolution of the systems, as well as the learning curve. Negative results have been reported, contrasting with very positive results described in other studies.[23,24,26,27] The use of robotic systems in spine surgery has also been associated with a reduction in the surgeon's physical and mental workload.[28] Although we did not objectively evaluate this parameter, a reduction in physical and mental workload was subjectively perceived when using the robotic system.

The reported advantages of robotic systems include reduced fluoroscopy time and lower radiation exposure during the surgical procedure.[5,12] Radiation exposure during freehand procedures may be up to four times higher compared with robotic-assisted surgery.[8] In our series, fluoroscopy time and radiation dose were low, demonstrating the low level of intraoperative radiation exposure associated with the use of the robotic system. Reduced intraoperative radiation exposure has been consistently reported as one of the advantages of robotic systems in spine surgery.[19,24]

The development of robotic systems has not been free of technical challenges and limitations related to computer software, image registration, reach of the robotic arm, trajectory deviation due to excessive force, device ergonomics, and implant trajectory deviation caused by slippage.[23,24,27] In our experience, problems related to intraoperative image registration, pilot-hole preparation, and soft-tissue retraction were observed, which may affect implant accuracy and should be considered as part of the learning curve of robotic systems.

The current study has limitations related to patient heterogeneity and the learning curve. Since the robotic system became available, procedures were performed consecutively without selecting a specific condition or vertebral segment and were limited to the thoracic and lumbar spines. Clinical outcomes were not evaluated at this initial stage, as only parameters related to registration time, implant accuracy, and intraoperative radiation exposure

were considered. Furthermore, at this stage, the present study did not evaluate the cost-effectiveness of robotic system use, a widely-discussed topic in the adoption of new technologies.[3,17]

The use of robotic systems in spine surgery requires teamwork, and team interaction is essential to achieve the potential benefits offered by this technology. Team interaction, beginning with preoperative planning, including discussion of the surgical steps and implant placement strategy, influences the outcome.[4,5] The importance of teamwork was evident during the introduction of this new technology and should be carefully considered in the implementation of robotic systems.

The preliminary results of robotic system use in spine surgery revealed the significance of the learning curve associated with this technology, high accuracy of implant placement, reduced intraoperative radiation exposure, the possibility of performing less invasive procedures, and the importance of preoperative planning, teamwork, and familiarity with the technology. Additional outcomes after completing the learning curve will be assessed in our setting, in order to evaluate the advantages described in comparison with traditional methods.

Conclusion

The use of the robotic system demonstrated high accuracy in implant placement, with reduced fluoroscopy time and lower intraoperative radiation exposure. The registration time also decreased as the experience with the robotic system increased. The use of robotic systems requires familiarity with the new technology and awareness of its limitations to achieve optimal results.

Data Availability

Data will be available upon request to the corresponding author.

Authors' Contributions

Each author contributed individually and significantly to the development of this article: HLAD, VMC, RSV, MPD, TD, and DSF: Conceptualization, data curation, formal analysis, investigation, methodology, validation, visualization, writing – original draft, and writing – review & editing.

Financial Support

The authors declare that they did not receive financial support from agencies in the public, private or non-profit sectors to conduct the present study.

Conflict of Interests

The authors have no conflict of interests to declare.

Acknowledgments

The authors would like to thank the technicians of the Mazor Robotic System—Felipe Fernandes Samogy, Gisene Bolzan Martins, and Helenês Marques de Morais—for their collaboration in conducting the study and during the learning curve.

References

1 Graetz G, Michaels G. Robots at work. Rev Econ Stat 2018;100(05): 753–768. Doi: 10.1162/rest_a_00754
2 Davies B. A review of robotics in surgery. Proc Inst Mech Eng H 2000;214(01):129–140. Doi: 10.1243/0954411001535309
3 Wang MY, Goto T, Tessitore E, Veeravagu A. Introduction. Robotics in neurosurgery. Neurosurg Focus 2017;42(05):E1. Doi: 10.3171/2017.2.FOCUS1783
4 Mensah-Brown KG, Yang AI, Yoon JW. Currently available robot-system in spinal surgery. In: Kim JS, Härtl R, Wang MY, Elmi-Terander A, editors. Technical Advance in Minimally Invasive Spine Surgery: Navigation, Robotics, Endoscopy, Augmented and Virtual Reality. Singapore: Springer; 2022:277–284. Doi: 10.1007/978-981-19-0175-1_24
5 Sun WX, Huang WQ, Li HY, et al. Clinical efficacy of robotic spine surgery: an updated systematic review of 20 randomized controlled trials. EFORT Open Rev 2023;8(11):841–853. Doi: 10.1530/EOR-23-0125
6 Lee YS, Cho DC, Kim KT. Navigation-Guided/Robot-Assisted Spinal Surgery: A Review Article. Neurospine 2024;21(01):8–17. Doi: 10.14245/ns.2347184.592
7 Torii Y, Ueno J, Iinuma M, Yoshida A, Niki H, Akazawa T. Accuracy of robotic-assisted pedicle screw placement comparing junior surgeons with expert surgeons: Can junior surgeons place pedicle screws as accurately as expert surgeons? J Orthop Sci 2023;28 (05):961–965. Doi: 10.1016/j.jos.2022.06.012
8 Hyun SJ, Kim KJ, Jahng TA, Kim HJ. Minimally Invasive Robotic Versus Open Fluoroscopic-guided Spinal Instrumented Fusions: A Randomized Controlled Trial. Spine 2017;42(06):353–358. Doi: 10.1097/BRS.0000000000001778
9 Kim HJ, Jung WI, Chang BS, Lee CK, Kang KT, Yeom JS. A prospective, randomized, controlled trial of robot-assisted vs freehand pedicle screw fixation in spine surgery. Int J Med Robot 2017;13 (03):. Doi: 10.1002/rcs.1779
10 Kantelhardt SR, Martinez R, Baerwinkel S, Burger R, Giese A, Rohde V. Perioperative course and accuracy of screw positioning in conventional, open robotic-guided and percutaneous robotic-guided, pedicle screw placement. Eur Spine J 2011;20(06): 860–868. Doi: 10.1007/s00586-011-1729-2
11 Moses ZB, Mayer RR, Strickland BA, et al. Neuronavigation in minimally invasive spine surgery. Neurosurg Focus 2013;35(02): E12. Doi: 10.3171/2013.5.FOCUS13150
12 Sundaram PPM, Peh DYY, Poh JW, et al. Does Robotic Spine Surgery Add Value to Surgical Practice over Navigation-Based Systems? A Study on Operating Room Efficiency. Medicina (Kaunas) 2024;60(12):2112. Doi: 10.3390/medicina60122112
13 Menger RP, Savardekar AR, Farokhi F, Sin A. A Cost-Effectiveness Analysis of the Integration of Robotic Spine Technology in Spine Surgery. Neurospine 2018;15(03):216–224. Doi: 10.14245/ns.1836082.041
14 Hu X, Lieberman IH. What is the learning curve for robotic-assisted pedicle screw placement in spine surgery? Clin Orthop Relat Res 2014;472(06):1839–1844. Doi: 10.1007/s11999-013-3291-1
15 Devito DP, Kaplan L, Dietl R, et al. Clinical acceptance and accuracy assessment of spinal implants guided with SpineAssist surgical robot: retrospective study. Spine 2010;35(24):2109–2115. Doi: 10.1097/BRS.0b013e3181d323ab
16 Gertzbein SD, Robbins SE. Accuracy of pedicular screw placement in vivo. Spine 1990;15(01):11–14. Doi: 10.1097/00007632-199001000-00004
17 Zawar A, Chhabra HS, Mundra A, Sharma S, Kalidindi KKV. Robotics and navigation in spine surgery: A narrative review. J Orthop 2023;44:36–46. Doi: 10.1016/j.jor.2023.08.007

18 Yu J, Zhang Q, Fan MX, Han XG, Liu B, Tian W. Learning curves of robot-assisted pedicle screw fixations based on the cumulative sum test. World J Clin Cases 2021;9(33):10134–10142. Doi: 10.12998/wjcc.v9.i33.10134
19 Akazawa T, Torii Y, Ueno J, et al. Learning curves for robotic-assisted spine surgery: an analysis of the time taken for screw insertion, robot setting, registration, and fluoroscopy. Eur J Orthop Surg Traumatol 2024;34(01):127–134. Doi: 10.1007/s00590-023-03630-x
20 Schatlo B, Molliqaj G, Cuvinciuc V, Kotowski M, Schaller K, Tessitore E. Safety and accuracy of robot-assisted versus fluoroscopy-guided pedicle screw insertion for degenerative diseases of the lumbar spine: a matched cohort comparison. J Neurosurg Spine 2014;20(06):636–643. Doi: 10.3171/2014.3.SPINE13714
21 Mao G, Gigliotti MJ, Myers D, Yu A, Whiting D. Single-Surgeon Direct Comparison of O-arm Neuronavigation versus Mazor X Robotic-Guided Posterior Spinal Instrumentation. World Neurosurg 2020;137:e278–e285. Doi: 10.1016/j.wneu.2020.01.175
22 Roser F, Tatagiba M, Maier G. Spinal robotics: current applications and future perspectives. Neurosurgery 2013;72(Suppl 1):12–18. Doi: 10.1227/NEU.0b013e318270d02c
23 Farivar D, Kim TT, Sy CA, et al. Complications Have Not Improved With Newer Generation Robots. Global Spine J 2025;15(02):898–905. Doi: 10.1177/21925682231216081
24 Schneider D, Brown EDL, Elsamadicy AA, Sciubba DM, Lo SL. The hidden cost of robotic spine surgery: real-world adverse events cause 58-minute delays and undermine economic viability. Spine J 2026;26(01):189–198. Doi: 10.1016/j.spinee.2025.07.014
25 Hicks JM, Singla A, Shen FH, Arlet V. Complications of pedicle screw fixation in scoliosis surgery: a systematic review. Spine 2010;35(11):E465–E470. Doi: 10.1097/BRS.0b013e3181d1021a
26 Ringel F, Stüer C, Reinke A, et al. Accuracy of robot-assisted placement of lumbar and sacral pedicle screws: a prospective randomized comparison to conventional freehand screw implantation. Spine 2012;37(08):E496–E501. Doi: 10.1097/BRS.0b013e31824b7767
27 Patel NA, Brown NJ, He C, et al. Characterizing the complication profile of spinal robotic systems: A MAUDE analysis of device failures and associated complications by device manufacturer and brand name. J Clin Neurosci 2025;135:111149. Doi: 10.1016/j.jocn.2025.111149
28 Morse KW, Subramanian T, Zhao E, et al. Robotic-Assisted Navigation in Single-Level Transforaminal Lumbar Interbody Fusion Reduces Surgeons' Mental Workload Compared With Fluoroscopic and Computed Tomographic Techniques: A Nonrandomized Prospective Controlled Trial. HSS J 2025;21(01):27–34. Doi: 10.1177/15563316241281064