Fractures of the Inferior Angle of the Scapula: Case Series and Proposed Simplified Treatment Algorithm

Fraturas do ângulo inferior da escápula: série de casos e proposta de algoritmo simplificado de tratamento

Robinson Esteves Pires[1,2] Gustavo Waldolato[1,3] Pablo Jose Carrasco Ordoñez[1]
Rafael Guillermo Gallego Andrade[1] Gabriel H. R. Melo[1] Vincenzo Giordano[4]

[1] Orthopedics and Traumatology Department, Hospital Felício Rocho, Belo Horizonte, MG, Brazil
[2] Musculoskeletal System Department, Faculdade de Medicina, Universidade Federal de Minas Gerais, Belo Horizonte, MG, Brazil
[3] Orthopedics Department, Faculdade de Ciências Médicas de Minas Gerais, Belo Horizonte, MG, Brazil
[4] Prof. Nova Monteiro Orthopedics and Traumatology Department, Hospital Municipal Miguel Couto, Rio de Janeiro, RJ, Brazil

Address for correspondence Robinson Esteves Pires, MD, PhD, Av. Alfredo Balena, 190, Santa Efigênia, 30130-100, Belo Horizonte, MG, Brazil (e-mail: robinsonestevespires@gmail.com).

Rev Bras Ortop 2026;61(4):s00461827215.

Abstract

Objective To present a series of three cases of fractures of the inferior angle of the scapula, along with a literature review and a proposed simplified treatment algorithm.

Methods The present retrospective case series (level of evidence IV) included 3 patients with fractures of the inferior angle of the scapula, followed for 6 months. Two patients were managed non-surgically, and one underwent internal fixation with a mini-fragment plate and screws. Time to fracture union and functional outcomes were assessed using the following validated scores: the Disabilities of the Arm, Shoulder and Hand (DASH), the University of California Los Angeles (UCLA) Shoulder Score, and the Brazilian version of the Constant-Murley Score (CMS-BR). A literature review was also performed, and a simplified treatment algorithm was proposed.

Results All patients achieved fracture union within 8 weeks, with functional outcomes rated as good or excellent. No complications were observed, including pseudo-scapular winging, nonunion, or malunion.

Conclusion In the current case series, all fractures healed satisfactorily, without complications, and with good or excellent functional outcomes.

Keywords
- scapula
- shoulder fractures
- shoulder joint

Work developed at the Orthopedics and Traumatology Department, Hospital Felício Rocho, Belo Horizonte, MG, Brazil.

received
February 2, 2026
accepted after revision
May 8, 2026

DOI https://doi.org/10.1055/s-0046-1827215.
ISSN 0102-3616.

Editor-in-Chief: Geraldo da Rocha Motta Filho.

© 2026. The Author(s).
This is an open access article published by Thieme under the terms of the Creative Commons Attribution 4.0 International License, permitting copying and reproduction so long as the original work is given appropriate credit (https://creativecommons.org/licenses/by/4.0/)

Thieme Revinter Publicações Ltda., Rua Rego Freitas, 175, loja 1, República, São Paulo, SP, CEP 01220-010, Brazil

Resumo

Objetivo Apresentar uma série de três casos de fratura do ângulo inferior da escápula, associada a uma revisão da literatura e à proposição de um algoritmo simplificado de tratamento.

Métodos Série de casos retrospectiva (nível de evidência IV) incluindo 3 pacientes com fratura do ângulo inferior da escápula, acompanhados por 6 meses. Dois pacientes foram tratados de forma conservadora e um foi submetido à fixação interna com placa e parafusos de minifragmentos. Foram avaliados o tempo para consolidação e desfechos funcionais por meio dos seguintes escores validados: Disabilities of the Arm, Shoulder and Hand (DASH), escore da University of California Los Angeles (UCLA) e a versão brasileira da escala de Constant-Murley (CMS-BR). Também foi realizada revisão da literatura, a partir da qual se propôs um algoritmo simplificado de tratamento.

Resultados Todos os pacientes apresentaram consolidação da fratura em até 8 semanas, com desfechos funcionais classificados como bons ou excelentes. Não foram observadas complicações, incluindo pseudoescápula alada, não união ou má união.

Conclusão Nesta série de casos, todas as fraturas consolidaram satisfatoriamente, sem complicações, e com resultados funcionais bons ou excelentes.

Palavras-chave

- articulação do ombro
- escápula
- fraturas do ombro

Introduction

Fractures of the inferior angle of the scapula (FIAS) are extremely rare, being described almost exclusively in case reports.[1] The ratio of men to women is 3:1, and the mean age of presentation is 33 years.[2]

Morphologically, the anterior deviation and/or angulation observed in FIAS is a result of the force vectors of the muscle insertions. The serratus anterior muscle is inserted along the superior angle, the medial border, and the inferior angle of the scapula; on the posteromedial surface of the inferior angle, the rhomboid major is inserted, and on the posterior surface, the latissimus dorsi and the teres major.[3] Thus, in the vast majority of cases, FIAS correspond to fracture-avulsion, especially due to the action of the serratus anterior muscle. Other possible mechanisms of trauma are electroconvulsive therapy, persistent cough, seizure, and muscle contraction against resistance in FIAS avulsion.[4,5]

As FIAS are extremely rare lesions with limited literature, there is no standardized treatment for them. Nondisplaced or incomplete fractures of the inferior angle of the scapula with bone contact are theoretically managed non-surgically.[1] However, non-surgical treatment of displaced fractures can potentially lead to painful non-union and pseudo-scapular winging, causing shoulder pain, muscle weakness, and limitation of ipsilateral upper limb movement.[2,3,6,7]

The unfavorable scapular anatomy for implant placement, the complexity of the access routes, the intimate relationship of the scapula with important neurovascular structures, and the rarity of the lesion are potential obstacles to determining an ideal treatment protocol for FIAS.[8] Thus, based on the available literature and observations of the evolution of the patients presented in this series, we hypothesize that a simplified treatment protocol, guided by the presence of initial fracture displacement and bone contact, should be the guiding factor in treatment decisions. The objectives of the current study are to present three FIAS cases, to conduct a literature review, and to propose a simplified treatment algorithm.

Methods

The electronic medical records of patients treated in a tertiary hospital between October 2024 and August 2025 were reviewed. The study was approved by the institutional review board (CAAE opinion: 74381323.4.0000.5125), and all participants signed the informed consent form. The inclusion criterion was FIAS in a skeletally-mature patient, with a minimum follow-up of 6 months. The functional evaluation was face-to-face, during outpatient follow-up. Fracture consolidation time, complications, and the following functional scores were evaluated: Disabilities of the Arm, Shoulder and Hand (DASH) questionnaire,[9] University of California Los Angeles (UCLA) scoring system,[10] and the Brazilian version of the Constant-Murley scale (CMS-BR).[11] ►**Table 1** shows the characteristics of patients with FIAS.

Patient 1

A 56-year-old female patient suffered a fall from a concrete wall on the left hemithorax, evolving with ventilatory-dependent pain in the left hemithorax and in the region of the ipsilateral scapula. During the initial radiographic evaluation, fractures of the 6th and 7th costal arches and left FIAS (Bartoníček type IV[12]/AO 14B1[13]) were observed. For propaedeutic extension, computed tomography was requested (►**Fig. 1**).

Due to the initial fracture displacement and absence of bone contact between the fragments, we opted for surgical treatment under general anesthesia, with the patient

Table 1 Demographic data

Case	Sex	Age	Classification		Treatment	Complications
			Bartoniček[12]	AO/ OTA[13]		
1	Female	56	IV	14B1	Surgically	None
2	Female	36	I	14B1	Non-surgical	None
3	Male	43	II	14B1	Non-surgical	None

Abbreviations: AO/OTA, Arbeitsgemeinschaft für Osteosynthesefragen – Orthopaedic Trauma Association.

positioned in the prone position. A 5-cm access was performed, limited to the lower angle of the scapula, with open reduction and internal fixation with a 2.4-mm mini-fragment blocked plate (Evos Mini Plating System, Smith & Nephew) (►**Figs. 2**–**3**). In the postoperative period, the patient used a Velpeau sling to help control pain and was encouraged to start physiotherapy rehabilitation with pendulum exercises, followed by passive and active exercises, assisted as soon as pain allowed, which occurred after 1 week of treatment.

Patient 2

A 36-year-old female patient suffered a fall on a bus. On computed tomography, an incomplete FIAS was observed, involving only the apex of the inferior angle of the scapula (Bartoniček type I[12]/AO 14B1[13]), with bone contact in the medial pillar of the inferior angle of the scapula (►**Fig. 4**)

Non-surgical treatment was chosen, using a Velpeau sling for 3 weeks, followed by the same rehabilitation protocol used in Patient 1.

Patient 3

A 43-year-old male patient suffered an automobile accident, evolving with multiple thoracic and cranial injuries. During the initial evaluation, thoracoabdominal and skull computed tomography were requested, revealing fractures of the bilateral parietal and temporal bones, an acute subdural hematoma, and fractures of the 1st to 6th costal arches.

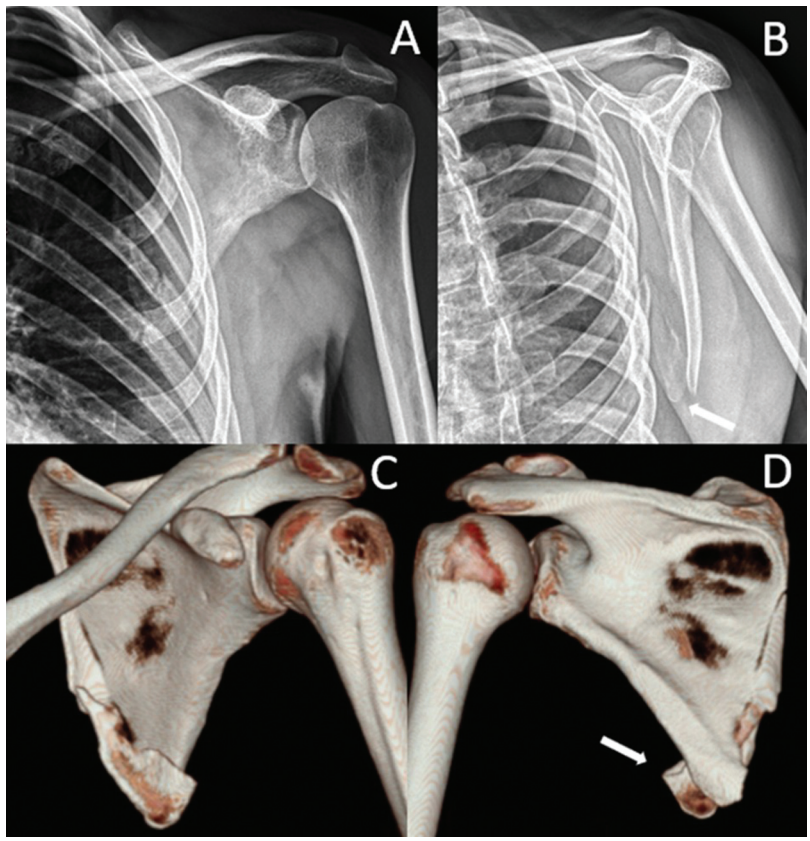

Fig. 1 Anteroposterior radiography of the shoulder (A), profile of the scapula (B), 3D reconstruction of the anterior (C) and posterior (D) faces of the left scapula. This is an avulsion fracture of the inferior angle of the scapula, with displacement involving the medial border (Bartoniček type IV/AO 14B1m). Ventral displacement of the distal fragment (arrows) is observed, resulting from the deforming force exerted by the serratus anterior muscle.

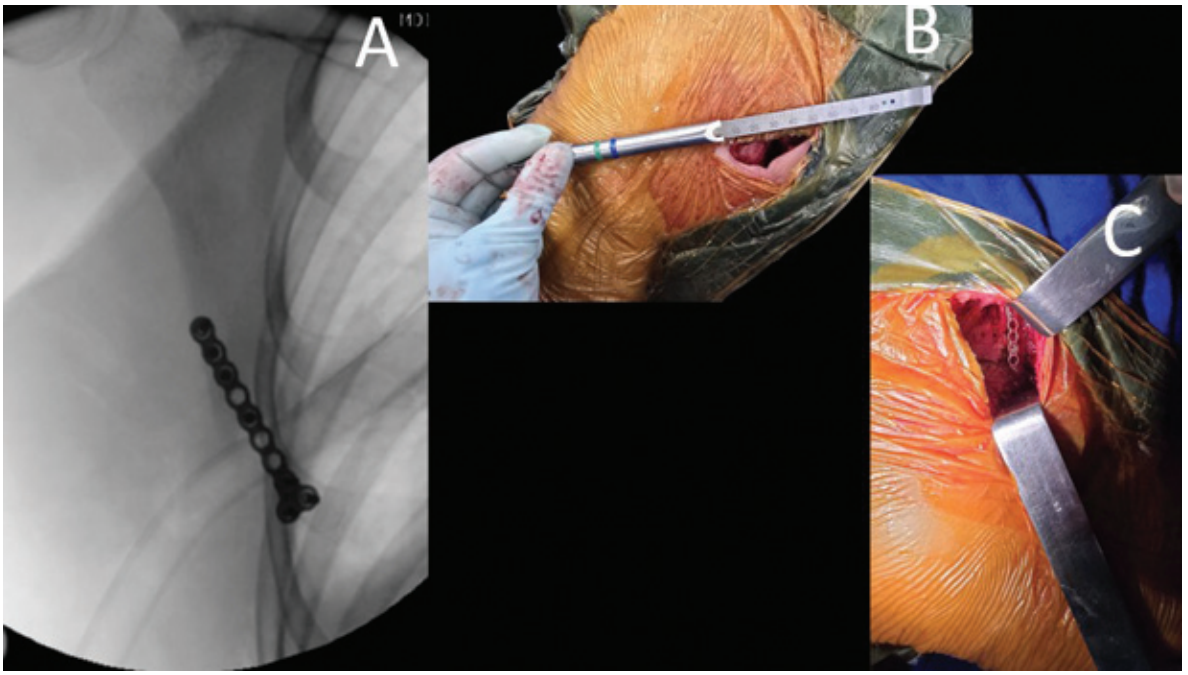

Fig. 2 Intraoperative image of the image intensifier showing the positioning of the mini-fragment plate on the lateral pillar of the scapula, the site with the highest amount of bone mass for fixation (A). Note the intraoperative photographs illustrating the size of the surgical incision (5 cm), fracture reduction, and plate fixation (B and C).

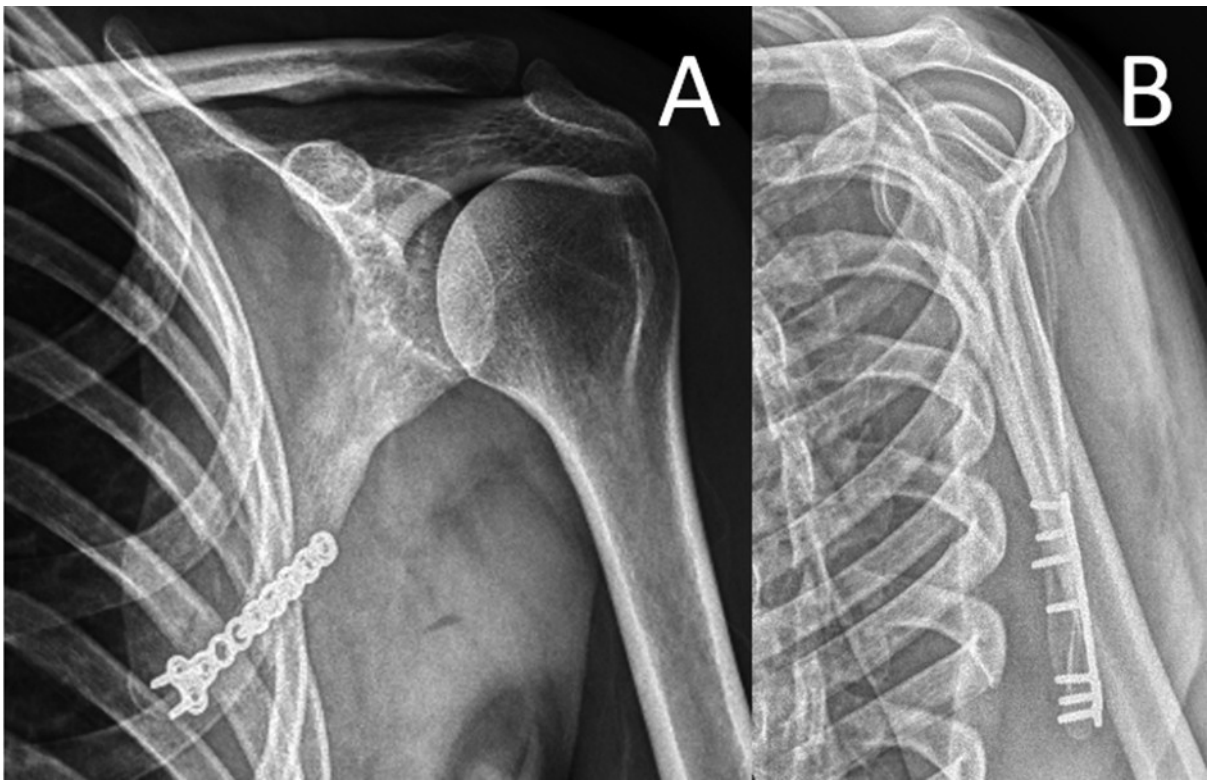

Fig. 3 Postoperative radiography of the left anteroposterior (A) and lateral (B) scapula. Fixation with a 2.4 mm mini-fragment locked plate is observed.



Fig. 4 Radiography of the right scapula in profile (A) and 3D reconstruction of the scapula in lateral view (B) and the dorsal face (C).

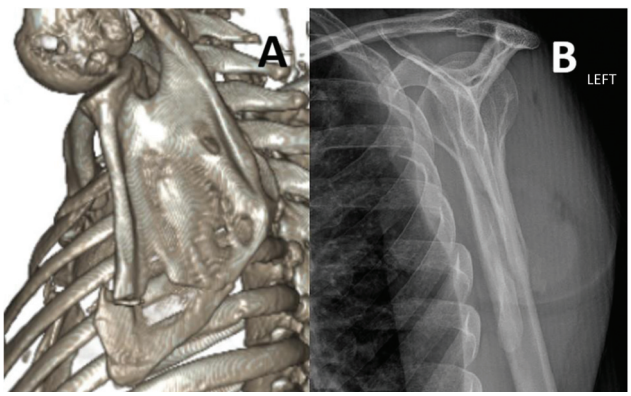

Fig. 5 3D reconstruction in dorsal view (A) and lateral radiography (B) of the left scapula performed 8 weeks after the accident. There is involvement of the entire inferior angle of the scapula, classified as Bartoníček type II / AO14B1.

The patient presented left FIAS (Bartoníček type II[12]/AO 14B1[13]) (►**Fig. 5**) and a fracture of the body of the right scapula, which were not initially identified and were diagnosed 8 weeks after the trauma. Given the late evolution and minimally displaced characteristics, and the presence of bone contact between the main fragments of the fracture, non-surgical treatment was chosen.

Based on the treated patients and the available literature, we developed a simplified treatment protocol that accounts for the presence of initial fracture displacement and bone contact (►**Fig. 6**). A complete fracture without bone contact between the fragments was considered displaced.

Results

All patients completed a minimum follow-up of 6 months. Consolidation time ranged from 6 to 8 weeks. Functional outcomes are described in ►**Table 2**. The functional outcome picture of patient 1 is illustrated in ►**Fig. 7**, and the images after fracture healing in the 3 patients are illustrated in ►**Fig. 8**.

Discussion

Fractures of the inferior angle of the scapula are rare lesions, with limited literature, and treatment outcomes remain inconsistent.[1] Studies suggest that FIAS without deviation respond well to non-surgical treatment, whereas FIAS with deviation are associated with high rates of complications, including non-union, malunion, and pseudo-scapular winging, which may lead to scapulothoracic dyskinesia, pain, and ipsilateral upper limb dysfunction.[1]

Heyse-Moore and Stoker[4] described the fracture mechanisms of FIAS and reported three cases of non-surgical treatment that progressed to healing. Chang et al.[14] conducted a literature review of 10 FIAS cases, 6 treated non-surgically and 3 surgically with transosseous suture or a double plate. The authors recommended surgical treatment of FIAS with displacement to avoid painful nonunion. They also advocate that fixation with transosseous suture provides favorable outcomes. Bartoníček et al.[12] proposed a new classification for FIAS, based on 3-dimensional tomographic reconstruction of 20 FIAS. The authors describe 5 types of FIAS: type I, fracture of the apex of the inferior angle; type II, fracture involving the entire inferior angle; type III, fracture of the inferior angle with extension to the lateral edge; type IV, fracture of the inferior angle with involvement of the medial border; and type V, fracture of the inferior half of the infraspinatus part of the body of the scapula. The introduction of this classification offered the advantage of allowing a more objective identification of the fracture patterns, with special attention to the size and shape of the fragments, the extent of the fracture lines along the lateral edges (although highly variable, affecting only the distal half of the lateral edge) and medial borders, and fragment deviation. In addition, it enabled the establishment of a boundary between the fractures of the inferior angle and the body of the scapula, a distinction not possible with previous descriptions. The authors did not include specific treatment recommendations for the types of fracture. Therefore, the development of a simplified treatment protocol for FIAS is warranted, given

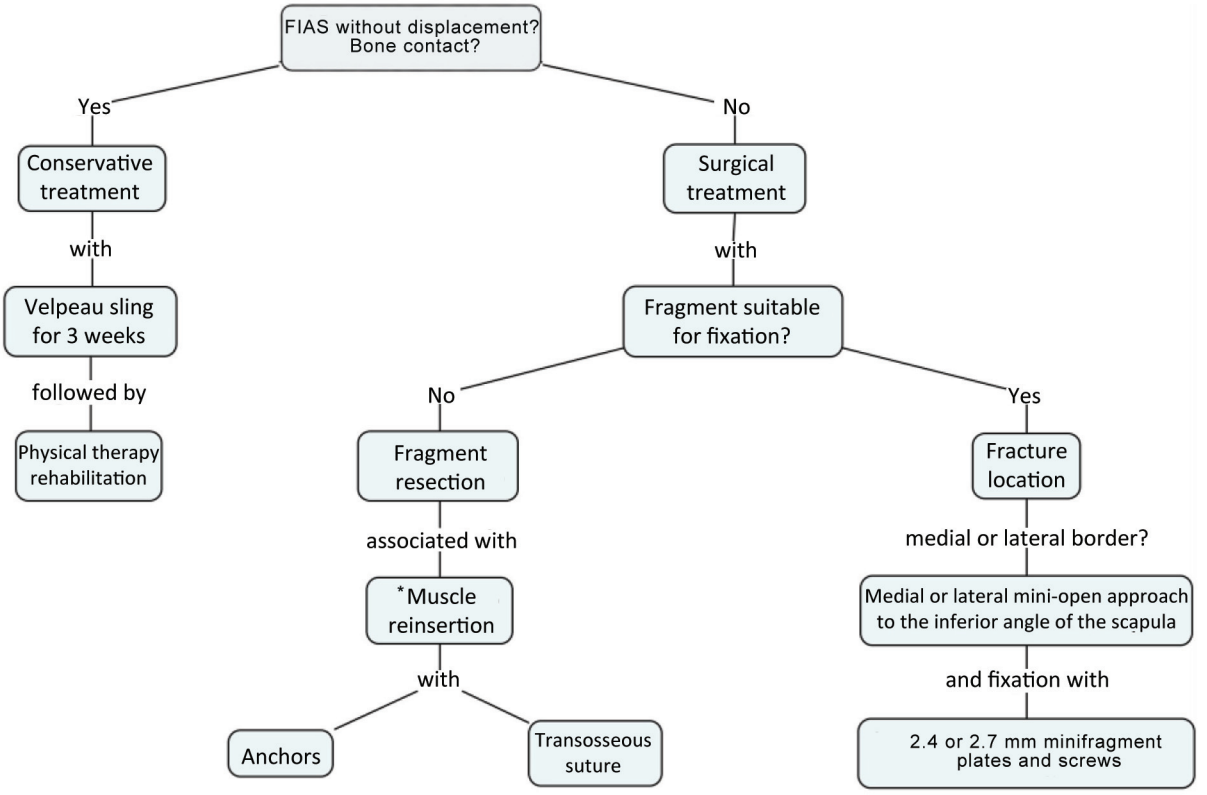

Fig. 6 Fractures of the inferior angle of the scapula treatment algorithm. (* if bone mass and scapular fracture site allow).

Table 2 Functional outcomes

Patient	CMS-BR	UCLA	DASH
1	86	35	0.8
	Excellent	Excellent	Excellent
2	79	28	0.8
	Good	Good	Excellent
3	92	33	11.6
	Excellent	Good	Excellent

Abbreviations: CMS-BR, Brazilian version of the Constant-Murley scale, DASH, Disabilities of the Arm, Shoulder and Hand, UCLA – The University of California Los Angeles scoring system.



Fig. 7 Patient 1, 60 days after treatment: (A) scar aspect, (B) internal rotation of the ipsilateral upper limb, (C) flexion of the arms against the wall to test the serratus anterior muscle, without scapulothoracic dyskinesia, and (D) elevation of the ipsilateral upper limb. Observe the full range of motion. No occurrence of pseudo-scapular winging was observed.

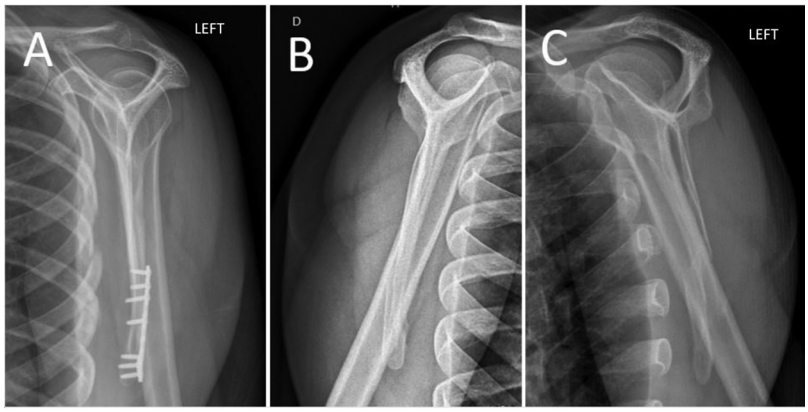

Fig. 8 (A) Radiography in profile of the left scapula after four and a half months of fixation of patient 1, with complete fracture consolidation. (B) Radiography in profile of the right scapula of patient 2 after one and a half months of trauma, with complete fracture consolidation. (C) Radiography in profile of the left scapula two months after the trauma, with fracture consolidation in Patient 3.

current knowledge and the complications associated with dysfunction, particularly of the serratus anterior muscle.

Ogawa et al.[15] reported a case of neglected FIAS that presented with pseudo-scapular winging and limited range of motion. This report corroborates the hypothesis that non-surgical treatment of FIAS with displacement generally leads to complications such as non-union, malunion, and pseudo-scapular winging. Mousafeiris et al.[2] presented a series of 22 cases, in which 8 of the 9 displaced FIAS treated non-surgically had failed fracture healing, leading to malunion or non-union, resulting in pseudo-scapular winging and other complications that affected the normal function of the scapular girdle, causing chronic pain, impact, and/or scapulothoracic dyskinesia. Alder-Price et al.[16] reported, in a retrospective series of 14 patients with FIAS, that half of the displaced fractures evolved with good results even without surgical treatment, while the other half presented unfavorable evolution, with persistent pain and shoulder dysfunction. The available clinical documentation and imaging tests did not allow us to identify a clear explanation for why only some patients remain symptomatic. The authors suggest that the persistence of symptoms may be related to the development of pseudo-scapular winging, due to the loss of stabilization provided by the lower pole of the scapula and the musculature inserted into it.

Within the therapeutic options of surgical treatment of FIAS, repair with suture, fragment resection, open reduction and internal fixation, and the use of a bone anchor have been described. Neopoulos et al.[17] reported two cases of FIAS with deviation, with the fragment located in the scapulothoracic space, which underwent surgical treatment using the trans-osseous suture technique, resulting in excellent functional results. ►**Table 3**[2,4–7,14–30] details the main reports and case series of FIAS.

Among the limitations of the study, we first highlight the previously mentioned small number of cases, which is inherent to the lesion's rarity. In any case, because it is a small case series, there is an expected reduction in the statistical power of the evaluations, preventing the performance of more robust inferential analyses. In addition, the retrospective design is subject to selection and information biases, as well as heterogeneity in the clinical documentation and imaging tests available, which restricts the generalization of the results and the strength of the conclusions. The absence of a control group comparing the two treatment modalities is also a limitation. Finally, given these limitations, our simplified treatment protocol requires validation.

However, there are some points that deserve highlighting. This is one of the largest single-center series in the literature, demonstrating the rarity of this lesion occurring in isolation. In addition, despite the limited number of patients, it was the first study to propose a simplified protocol for treating FIAS. Although this protocol has not been validated, we believe that the presence of anterior deviation and the absence of bone contact are the most important factors in the occurrence of complications, such as non-union or malunion, which may lead to scapulothoracic dyskinesia and its consequences. In our patients, in the surgically treated case, adequate reduction of the inferior angle fragment, associated with internal fixation, led to fracture consolidation. Similarly, the presence of bone contact and minimal anterior deviation in the other cases treated non-surgically resulted in consolidation without complications, with satisfactory functional results on validated scores.

Conclusion

The favorable outcomes of the three patients with FIAS lead us to believe that a simplified treatment protocol, based on the presence of displacement and bone contact between the main fragments, is appropriate and clinically applicable in therapeutic decision-making in these cases.

Data Availability

Data will be available upon request to the corresponding author.

Authors' Contributions

REP: conceptualization, investigation, supervision, writing – original draft; writing – review & editing, and

Rev Bras Ortop Vol. 61 No. 4/2026 © 2026. The Author(s).

Table 3 Main reports and case series of FIAS published in indexed journals

Author	Year of publication	Patient (age/sex)	Deviation	Initial treatment (surgical technique)	Outcome after initial treatment	Revision (surgical technique)	Time to surgery	Final outcome after surgery	Follow-up (months)
Peraino et al.[18]	1977	57/M	n/m	Non-surgical	Consolidation	–	–	–	n/m
Hayes and Zehr[19]	1981	25/M	n/m	Non-surgical	Muscle weakness in the shoulder	Fragment resection + reinsertion of serratus anterior muscle	9 months	ROM No pain, muscle strength recovered, no PSW	12
Heyse-Moore and Stoker[4]	1982	13/F	n/m	Non-surgical	Clicking sensation in the shoulder, palpable prominence, and preserved strength	–	–	–	2.5
		50/ n/m	n/m	n/m	n/m	n/m	n/m	n/m	n/m
		70/M	n/m	Non-surgical	No pain, strength preserved, -10° abduction	–	–	–	2
Martin and Weiland[20]	1994	27/F	n/m	Non-surgical	Clicking sensation and pain on scapulothoracic joint with abduction and external rotation Free ROM	Resection of the inferior scapular angle and bony prominences of the costal arches	23 years	ROM no pain	15
Brindle e Coen[21]	1998	17/M	Minimum	Non-surgical	No pain, free ROM, no PSW	–	–	–	6
Gupta et al.[22]	1998	45/M	Yes	Non-surgical	ROM with pain and clicking, PSW	Plate and screw fixation	5 months	170° elevation, 65° external rotation; no pain	24
Kaminsky and Pierce[23]	2002	16/M	Yes	Non-surgical	Non-union and persistent pain	Fragment resection + muscle reinsertion	n/m	Asymptomatic returned to normal activities	4.5
Franco et al.[5]	2004	47/M	No, deviation after 1 year	Non-surgical	Mild pain when in abduction	–	–	–	12
Mansha et al.[6]	2010	31/M	n/m	Non-surgical	Pain related to physical exertion, PSW	Transosseous suture	2 years	No PSW, ROM no pain	3.5
Szopinski et al.[24]	2012	5/M	Yes	Surgical (transosseous suture)	ROM no pain	–	n/m	–	3
Min et al.[7]	2014	41/M	Yes	Non-surgical	Pain when exercising, clicking, PSW	Plate fixation and transosseous suture	12	ROM no pain	24
		39/M	Yes	Surgical	No PSW, ROM no pain	Transosseous suture	–	–	18
		55/M	Yes	Surgical	No PSW, ROM no pain	Plate fixation and transosseous suture	–	–	12
Chang et al.[14]	2016	43/M	Yes	Non-surgical	Pain on ROM PSW	Transosseous suture	1 month	No PSW, ROM no pain	3
		65/M	Yes	Non-surgical	Restrict ROM with pain, PSW	–	–	–	16
Speigner et al.[25]	2016	51/M	Yes	Non-surgical	Reduced muscle strength, PSW	Anchor reinsertion	5 months	Strength recovered, no PSW	3
Park et al.[26]	2017	10/M	Yes	Surgical (transosseous suture)	Free ROM	–	5 days	–	24

Table 3 (*Continued*)

Author	Year of publication	Patient (age/sex)	Deviation	Initial treatment (surgical technique)	Outcome after initial treatment	Revision (surgical technique)	Time to surgery	Final outcome after surgery	Follow-up (months)
Miller et al.[27]	2018	4/M	n/m	Non-surgical	ROM no pain	–	–	–	3
Ogawa et al.[15]	2019	20/F	n/m	Non-surgical	Occasional painless clicking, no PSW Constant score compared to the contralateral shoulder 100% DASH score 0	–	–	–	120
Edington et al.[28]	2020	12/M	Deviation	Non-surgical	No PSW, ROM no pain	–	–	–	12
Mousaferis et al.[2]	2022	42/M	No	Non-surgical	ROM no pain ASES score 93 Quick DASH 2.3%	–	–	–	3
Alder-Price et al.[16]	2022	10 M/4 F Mean of 58 years	8 with deviation	Non-surgical	n: 3 DASH score 0, no pain n: 3 non-satisfactory n: 2 losses	n:2Patient 1: Plate fixation Patient 2: Fragment resection	Patient 1: 1 month Patient 2: 5 years	ROM no pain	n/m
			6 with deviation	Non-surgical	n: 4 DASH score 0, pain 0n: 2 losses	–	–	–	12
Reed and Frix[29]	2022	14/F	No	Non-surgical	Satisfactory	–	–	–	3
Chan et al.[30]	2023	40/M	Yes	Non-surgical	n/m	Transosseous suture	2	No PSW, ROM no pain	14
Neopoulos et al.[17]	2023	35/M	Yes	Surgical (transosseous suture)	No pain Constant score 97	–	–	–	15
		20/M	Yes	Surgical (transosseous suture)	No pain Constant score 99	–	–	–	4

Abbreviations: ROM, range of motion; ASES, American Shoulder and Elbow Surgeons; F, female; FIAS, Fractures of the inferior angle of the scapula; M, male; n/m, not mentioned; PSW, pseudo-scapular winging.

treatment of the patients involved in the study; PJCO, RGGA, GW, VG, and GHRM: investigation and writing – review & editing. All authors approved the final version of the manuscript.

Financial Support
The authors declare that they did not receive financial support from agencies in the public, private, or non-profit sectors to conduct the present study.

Conflict of Interests
Dr. Robinson Esteves Pires and Dr. Vincenzo Giordano reported payment or honoraria received from the AO Foundation.
Dr. Robinson Esteves Pires also reported a relationship with Johnson & Johnson, Smith & Nephew, and P&G.

References

1 Bartoníček J, Tuček M, Naňka O. Scapular fractures. In: Trail IA, ed. Textbook of Shoulder Surgery. Springer International Publishing; 2019:55–73
2 Mousafeiris VK, Kalyva N, Rigopoulos N, Mulita F, Mousafiris K. Characteristics, Management, and Outcomes of Inferior Scapula Angle Fractures: A Systematic Review of the Literature. Cureus 2022;14(07):e27192. Doi: 10.7759/cureus.27192
3 Pires RE, Lambronici PJ, Giordano V. Embryology, Anatomy, Biomechanics, Injury Mechanism, and Epidemiology of Scapular Fractures. . In: Pires RE, Lambronici PJ, Giordano V, eds. Fractures of the Scapula: Current management concepts. 1st ed. Springer; 2024:1–8
4 Heyse-Moore GH, Stoker DJ. Avulsion fractures of the scapula. Skeletal Radiol 1982;9(01):27–32. Doi: 10.1007/bf00367377
5 Franco M, Albano L, Blaimont A, Barrillon D, Bracco J. Spontaneous fracture of the lower angle of scapula. Possible role of cough. Joint Bone Spine 2004;71(06):580–582. Doi: 10.1016/j.jbspin.2003.10.001
6 Mansha M, Middleton A, Rangan A. An unusual cause of scapular winging following trauma in an army personnel. J Shoulder Elbow Surg 2010;19(08):e24–e27. Doi: 10.1016/j.jse.2010.08.006
7 Min K-D, Hwang S-H, Kim J-B, Cho S-H, Lee B-I. Treatment of Scapula Fractures of the Inferior Angle Causing Pseudowinging Scapula. J Korean Orthop Assoc 2014;49(02):165–171. Doi: 10.4055/jkoa.2014.49.2.165
8 Pires RE, Giordano V, Souza FSMd, Labronici PJ. Current challenges and controversies in the management of scapular fractures: a review. Patient Saf Surg 2021;15(01):6. Doi: 10.1186/s13037-020-00281-3
9 Orfale AG. [UNIFESP]. Tradução e validação do Disabilities of the Arm, Shoulder and Hand (DASH) para a língua portuguesa. Published online 2003. Repositório DSpace: Início. [Cited Oct 20, 2025] Available from: https://repositorio.ufmg.br/server/api/core/bitstreams/e05fa07d-360c-4e03-a75a-fa1a443404e7/content
10 Oku EC, Andrade AP, Stadiniky SP, Carrera EF, Tellini GG. Tradução e adaptação cultural do Modified-University of California at Los Angeles Shoulder Rating Scale para a língua portuguesa. Rev Bras Reumatol 2006;46(04):246–252. Doi: 10.1590/s0482-50042006000400003
11 Barreto RP, Barbosa ML, Balbinotti MA, Mothes FC, Rosa LH, Silva MF. The Brazilian version of the Constant-Murley Score (CMS-BR): convergent and construct validity, internal consistency, and unidimensionality. Rev Bras Ortop 2016;51(05):515–520. Doi: 10.1016/j.rboe.2016.08.017
12 Bartoníček J, Tuček M, Malík J. [Anatomy of fractures of the inferior scapular angle]. Rozhl Chir 2018;97(02):77–81 PubMed
13 Meinberg EG, Agel J, Roberts CS, Karam MD, Kellam JF. Fracture and Dislocation Classification Compendium-2018. J Orthop Trauma 2018;32(Suppl 1):S1–S170. Doi: 10.1097/bot.0000000000001063
14 Chang AC, Phadnis J, Eardley-Harris N, Ranawat VS, Bain GI. Inferior angle of scapula fractures: a review of literature and evidence-based treatment guidelines. J Shoulder Elbow Surg 2016;25(07):1170–1174. Doi: 10.1016/j.jse.2015.11.007
15 Ogawa K, Inokuchi W, Honma T. Overlooked Fracture of the Inferior Scapular Angle Treated Conservatively. Case Rep Orthop 2019;2019:9640301. Doi: 10.1155/2019/9640301
16 Alder-Price AC, Pilch W, Zhuang CB, McLean J, Bain GI. Inferior angle of scapula fractures: A retrospective case series. J Orthop Surg (Hong Kong) 2022;30(01):10225536221088633 . Doi: 10.1177/10225536221088633
17 Neopoulos G, Henninger HB, Suter T. Acute surgical treatment of entrapped avulsion fractures of the inferior angle of the scapula in adults: Two case reports. Trauma Case Rep 2023;48:100972. Doi: 10.1016/j.tcr.2023.100972
18 Peraino RA, Weinman EJ, Schloeder FX. Unusual fractures during convulsions in two patients with renal osteodystrophy. South Med J 1977;70(05):595–596. Doi: 10.1097/00007611-197705000-00030
19 Hayes JM, Zehr DJ. Traumatic muscle avulsion causing winging of the scapula. A case report. J Bone Joint Surg Am 1981;63(03):495–497
20 Martin SD, Weiland AJ. Missed scapular fracture after trauma. A case report and a 23-year follow-up report. Clin Orthop Relat Res 1994;(299):259–262
21 Brindle TJ, Coen M. Scapular avulsion fracture of a high school wrestler. J Orthop Sports Phys Ther 1998;27(06):444–447. Doi: 10.2519/jospt.1998.27.6.444
22 Gupta R, Sher J, Williams GR Jr, Iannotti JP. Non-union of the scapular body. A case report. J Bone Joint Surg Am 1998;80(03):428–430. Doi: 10.2106/00004623-199803000-00017
23 Kaminsky SB, Pierce VD. Nonunion of a scapula body fracture in a high school football player. Am J Orthop (Belle Mead NJ) 2002;31(08):456–457
24 Szopinski KT, Adamczyk G, Drwiega M. Traumatic detachment of the inferior angle of the scapula in a 5-year-old boy–a sonographic diagnosis. Skeletal Radiol 2012;41(05):615–618. Doi: 10.1007/s00256-011-1311-3
25 Speigner B, Verborgt O, Declercq G, Jansen EJP. Medial scapular winging following trauma–a case report. Acta Orthop 2016;87(02):203–204. Doi: 10.3109/17453674.2015.1117370
26 Park HY, Jang HJ, Sur YJ. Scapular body fracture and concomitant inferior angle apophyseal separation with intrathoracic displacement: a case report. J Pediatr Orthop B 2017;26(05):429–432. Doi: 10.1097/bpb.0000000000000404
27 Miller C, Grainger AJ, Phillips RS, Sabouni MY, Kraft JK. Bowing fracture of the inferior angle of the scapula, a difficult diagnosis. Pediatr Radiol 2018;48(01):146–149. Doi: 10.1007/s00247-017-3945-3
28 Edgington J, Antonacci CL, Alberta FG. Nonoperative management of a displaced cartilaginous avulsion fracture of the inferior aspect of the scapula. JSES Int 2020;4(02):280–286. Doi: 10.1016/j.jseint.2019.12.004
29 Reed DN, Frix JT. Scapular stress fracture of the inferior angle in an adolescent swimmer. Orthopedics 2023;46(04):e249–e252. Doi: 10.3928/01477447-20220907-01
30 Chan J, Hourston GJM, Robinson P. Inferior scapula avulsion fracture: an unusual presentation of winged scapula. BMJ Case Rep 2023;16(08):e255645. Doi: 10.1136/bcr-2023-255645