Assessment of Functional Recovery and Radiographic Shortening in Midshaft Clavicle Fractures Treated with Titanium Elastic Intramedullary Nailing*

Avaliação da recuperação funcional e do encurtamento radiográfico nas fraturas do terço médio da clavícula tratadas com osteossíntese por haste intramedular de titânio

Fábio Farina Dal Molin[1] Marcelo Henrique Gomes de Oliveira[1] Abcael Martins Santos Alves[1]

[1] Orthopedics and Traumatology Service, Hospital Moinhos de Vento, Porto Alegre, RS, Brazil

Address for correspondence Fábio Farina Dal Molin, MD, Serviço de Ortopedia e Traumatologia, Hospital Moinhos de Vento, Porto Alegre, RS, Brazil (e-mail: fabiodalmolin@me.com).

Rev Bras Ortop 2026;61(3):s00461825540.

Abstract

Objective To evaluate functional recovery and postoperative shortening in patients with midshaft clavicle fractures treated with a titanium elastic nail (TEN), and to analyze the time until bone union, esthetic satisfaction, and the complications associated with the technique.

Methods The current retrospective study with prospective data collection included 36 patients who underwent surgery between 2012 and 2023. Clinical, radiographic, and functional data were collected. Functional recovery was assessed using the Constant-Murley (score: 0–100) and the modified University of California, Los Angeles (UCLA), shoulder scores (score: 0–35). Shortening was measured on radiographs in the anteroposterior (AP), Zanca, and chest AP views. Statistical significance was set at $p \leq 0.05$.

Results The median age was 42 years. Fractures were equally distributed between dominant and non-dominant limbs. The mean time until bone union was 6 weeks, and the mean time until implant removal was 7.3 months. The union rate was 97.22%. The median Constant-Murley score was 100, and the median UCLA score was 35. The mean shortening ranged from 0.34 cm (AP) to 0.50 cm (Zanca). The complication rate was 27.78%, with no significant difference between open and closed reductions ($p = 0.226$).

Keywords
- clavicle
- diaphysis
- fracture fixation, internal
- fracture healing

* *Study developed at the Orthopedics and Traumatology Service, Hospital Moinhos de Vento, Porto Alegre, RS, Brazil.*

received
December 12, 2025
accepted after revision
May 8, 2026

DOI https://doi.org/10.1055/s-0046-1825540.
ISSN 0102-3616.

Editor-in-Chief: Geraldo da Rocha Motta Filho.

© 2026. The Author(s).
This is an open access article published by Thieme under the terms of the Creative Commons Attribution 4.0 International License, permitting copying and reproduction so long as the original work is given appropriate credit (https://creativecommons.org/licenses/by/4.0/)

Thieme Revinter Publicações Ltda., Rua Rego Freitas, 175, loja 1, República, São Paulo, SP, CEP 01220-010, Brazil

Conclusion Osteosynthesis of midshaft clavicle fractures using TENs resulted in a high union rate, excellent functional recovery, minimal alteration in clavicular length, high esthetic satisfaction, and an acceptable complication rate, representing a safe alternative to plate fixation in selected cases.

Resumo

Objetivo Avaliar a recuperação funcional e a presença de encurtamento pós-operatório nos pacientes com fratura do terço médio da clavícula tratados com haste intramedular do tipo *titanium elastic nail* (TEN, em inglês), e analisar o tempo de consolidação óssea, a satisfação estética e as complicações associadas ao método.

Métodos Realizamos um estudo retrospectivo, com coleta prospectiva de dados, que incluiu 36 pacientes operados entre 2012 e 2023. Foram coletados dados clínicos, radiográficos e funcionais. A recuperação funcional foi avaliada pela escala de Constant-Murley (pontuação: 0–100) e pela escala modificada de ombro da University of California, Los Angeles (UCLA; pontuação: 0–35). O encurtamento foi medido por radiografias nas incidências anteroposterior (AP), Zanca e AP de tórax. A análise estatística considerou $p \leq 0{,}05$.

Resultados A mediana de idade foi 42 anos. A distribuição foi equivalente entre os membros dominante e não dominante. O tempo médio para a consolidação foi de 6 semanas, e para a remoção do implante, 7,3 meses. A taxa de consolidação foi de 97,22%. A pontuação mediana na escala de Constant-Murley foi de 100, e na da UCLA, de 35. O encurtamento médio variou de 0,34 cm (AP) a 0,50 cm (Zanca). A taxa de complicações foi de 27,78%, sem diferença significativa entre reduções aberta e fechada ($p = 0{,}226$).

Conclusão A osteossíntese das fraturas do terço médio da clavícula com haste TEN apresentou alta taxa de consolidação, excelente recuperação funcional, mínima alteração do comprimento clavicular, elevada satisfação estética e perfil de complicações aceitável, configurando-se como alternativa segura à fixação com placas em casos selecionados.

Palavras-chave
- clavícula
- consolidação da fratura
- diáfise
- fixação interna de fraturas

Introduction

Clavicle fractures account for 5 to 12% of all fractures of the human skeleton, with 70 to 80% occurring in the midshaft and frequently being displaced due to muscular forces.[1] They are more common in young men (2:1 ratio) and often result from falls onto the shoulder or high-energy direct trauma.[2]

The treatment of these fractures in adults has evolved significantly over the last 2 decades. Although conservative management remains widely used in clinical practice, particularly for midshaft fractures, its indication should consider factors such as the degree of displacement, shortening, the patient's functional profile, and the risk of complications. Recent studies[3] have demonstrated relevant rates of malunion and nonunion after the nonoperative treatment.

Plate osteosynthesis remains the gold standard[4,5] for displaced midshaft clavicle fractures because of its high biomechanical stability. However, this technique is associated with complications, including infection, nonunion, implant failure, local discomfort, and the need for additional procedures for implant removal.[3] As an alternative to plate fixation, intramedullary fixation with a titanium elastic nail (TEN) is a minimally-invasive approach, with less soft-tissue disruption and improved cosmetic outcomes, although it carries specific risks, such as clavicular shortening and implant prominence.[6]

The aim of the current study was to evaluate functional recovery and the presence of postoperative shortening in patients with midshaft clavicle fractures treated with an intramedullary TEN, and to analyze the time until bone union, esthetic satisfaction, and complications associated with this technique.

Materials and Methods

The present study was a retrospective, descriptive observational study with prospective data collection, conducted at the Orthopedics and Traumatology Service of our institution, following prior approval by the Research Ethics Committee (under no. 76772524.1.0000.5330). Patients who underwent surgery between 2012 and 2023 were included, with data collected between February and December 2024.

We selected adult patients with completely-displaced midshaft-clavicle fractures and shortening greater than

1.5 cm, treated with TEN fixation and followed for 1 year after implant removal surgery. Nail diameter was individualized (2.0 mm, 2.5 mm, and 3.0 mm) according to patient anatomy and fracture characteristics.

Patients with fractures of the medial or lateral end of the clavicle, fractures with cortical contact between fragments, pathological fractures, previous or associated injuries of the ipsilateral shoulder girdle or upper limb that could compromise function, associated neurovascular injuries, open fractures not eligible for primary internal fixation, patients with clinical contraindications to surgery, and fractures older than 30 days were excluded.

All procedures were performed by the same orthopedic surgeon, specialized in shoulder and elbow surgery and affiliated with the institution, totaling 40 participants. Of these, 4 were excluded from the analysis because they did not return for the final clinical and radiographic evaluations, resulting in a final sample of 36 patients.

All patients underwent the same surgical technique. They were positioned in the beach-chair position (►**Fig. 1**), and a 1- to 2-cm medial approach was used (►**Figs. 2**–**3**). Nail diameter ranged from 2.0 to 3.0 mm. Open reduction was performed only when closed reduction of the fracture was not feasible. Postoperatively, a Velpeau sling was used for 30 days, while elbow flexion-extension and external rotation with the arm at the side were allowed immediately after surgery.



Fig. 1 Surgical positioning. Beach-chair position with fluoroscopic guidance.



Fig. 2 Preoperative planning of the medial incision.



Fig. 3 Surgical incision for clavicle osteosynthesis using a titanium elastic nail.

Data were obtained from medical records containing pre- and postoperative clinical assessments and radiographic examinations stored in a digital archive, and they were supplemented by telephone contact when information was incomplete. At the last in-person evaluation, clinical examination and bilateral clavicle radiographic assessment were performed.

The evaluation protocol comprised three stages: 1) preoperative assessment, including documentation of the mechanism of injury, sex, age, involvement of the dominant

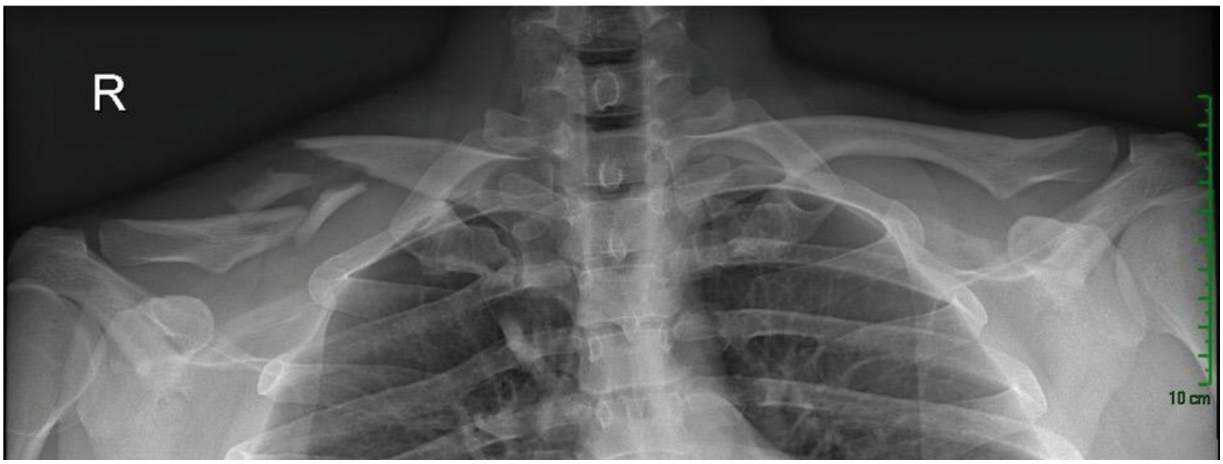

Fig. 4 Midshaft clavicle fracture.

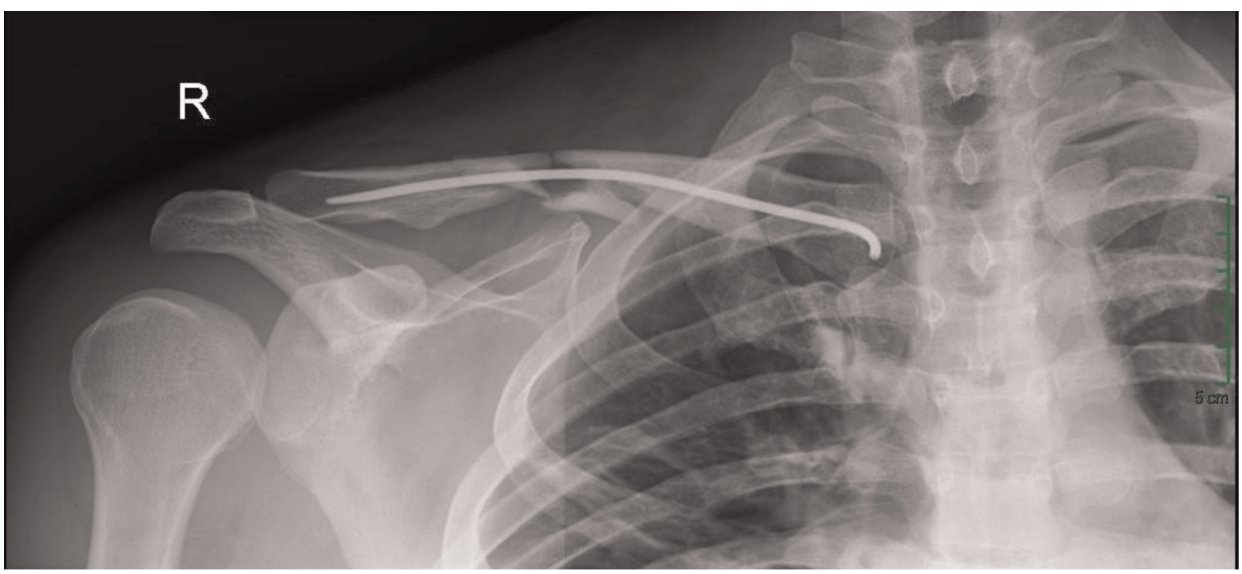

Fig. 5 Immediate postoperative radiograph following osteosynthesis of a midshaft clavicle fracture using a titanium elastic nail.

limb, initial clinical evaluation, and bilateral clavicle radiographs (►**Fig. 4**) obtained in the anteroposterior (AP), Zanca, and AP chest views, as well as measurement of shortening and fracture classification according to Robinson.[7] 2) Intraoperative assessment, including recording of operative time, incision length, and the need for open reduction. 3) Postoperative assessment, including control radiographs obtained immediately after the procedure (►**Fig. 5**), followed by scheduled visits at 7, 14, 21, and 28 days, and subsequently at 3, 6, and 12 months (►**Figs. 6**–**8**), evaluating pain, surgical

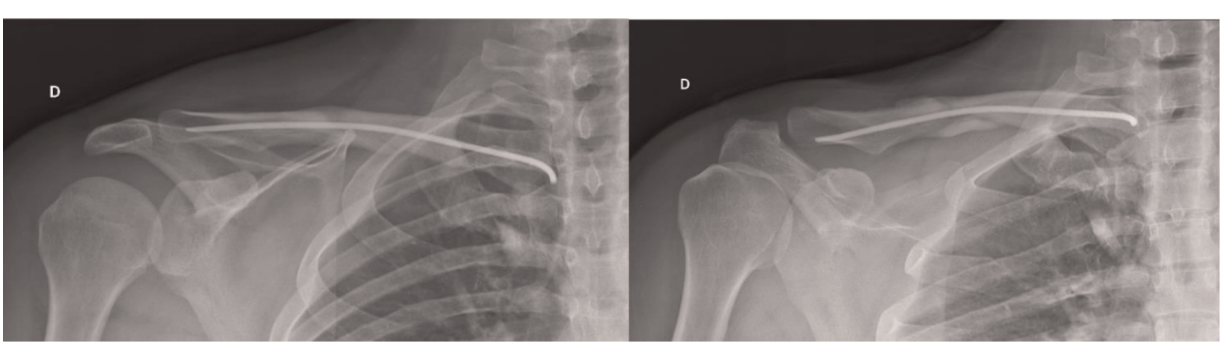

Fig. 6 Six-month postoperative radiograph following osteosynthesis of a midshaft clavicle fracture using a titanium elastic nail, showing fracture union.



Fig. 7 One-year postoperative radiograph following osteosynthesis of a midshaft clavicle fracture using a titanium elastic nail.

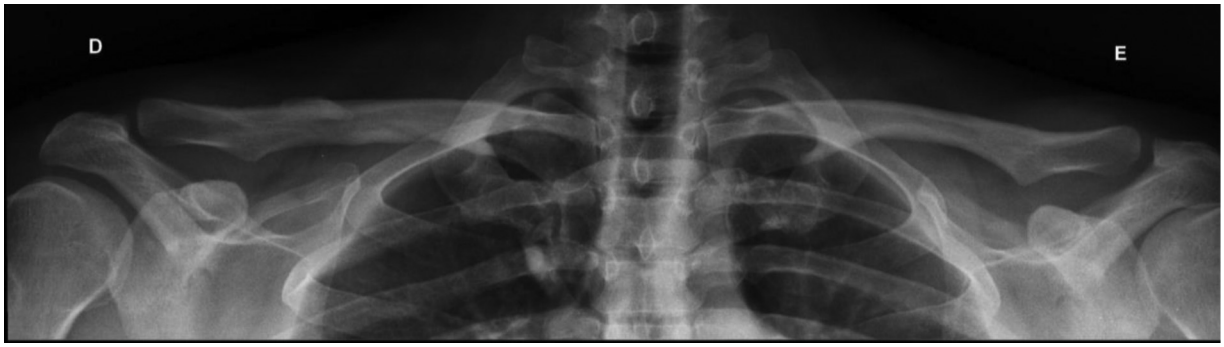

Fig. 8 Follow-up radiograph after removal of the titanium elastic nail.



Fig. 9 Postoperative scar following removal of the titanium elastic nail.

wound appearance (►**Fig. 9**), time until bone union, and length of the operated clavicle. Complications were recorded and analyzed according to the medical records.

Functional recovery was assessed at 6 and 12 months after implant removal, which was performed as an outpatient surgical procedure, using the Constant-Murley and modified University of California, Los Angeles (UCLA), shoulder scores.

The primary outcomes included functional recovery and postoperative clavicular length difference. The secondary outcomes included pain, function, patient satisfaction, active forward flexion range of motion, and strength assessment by manual resistance testing for forward flexion during routine physical examination, performed by the same examiner accompanied by a fourth-year shoulder and elbow surgery resident. Bone union was defined as the presence of continuous and homogeneous callus formation in one or more cortices, independently assessed by two surgeons on AP and Zanca radiographs.

Data were managed using the Research Electronic Data Capture (REDCap) platform[8,9] and analyzed with RStudio software (Posit, PBC), version 4.3.1. The qualitative variables were expressed as absolute and relative frequencies, whereas the quantitative variables were summarized using measures of central tendency and dispersion after assessment of data distribution. Associations involving qualitative variables were evaluated using the Fisher's exact test and/or the Pearson's Chi-squared test ($p \leq 0.05$), as appropriate.

Results

The sample included 36 patients, with a median age of 42 (interquartile range [IQR]: 28.5–46) years. The distribution between dominant and nondominant limbs was equivalent (►**Table 1**).

According to the Robinson classification,[7] type 2B1 was the most prevalent, accounting for 80.56% of the cases. Postoperative radiographic measurements demonstrated a mean shortening of 0.34 ± 0.79 cm on AP views,

Table 1 Description of study variables

Variable	N = 36
Affected limb: n (%)	
Dominant	18 (50%)
Non-dominant	18 (50%)
Age at surgery (years): median (interquartile range)	42 (28.5–46)
Reduction type (fracture site): n (%)	
Open	9 (25%)
Closed	27 (75%)
Time until union (weeks): median (interquartile range)	6 (4–7)
Time until implant removal (months) : median (interquartile range)	7.3 (6–11.9)
Postoperative complications: n (%)	
Yes	10 (27.78%)
No	26 (72.22%)
Union: n (%)	
Yes	35 (97.22%)
No	1 (2.78%)
Constant-Murley score: median (interquartile range)	100 (100–100)
University of California, Los Angeles, score: median (interquartile range)	35 (35–35)
Esthetic satisfaction: n (%)	
No	1 (2.78%)
Yes	35 (97.22%)
Tenderness at the surgical wound site: n (%)	
Yes	3 (8.33%)
No	33 (91.67%)
Fracture classification (Robinson): n (%)	
2A2	1 (2.78%)
2B1	29 (80.56%)
2B2	6 (16.67%)
Mean difference in the affected limb (cm; anteroposterior view)	0.34 (0.79)
Mean difference in the affected limb (cm; Zanca view)	0.5 (0.86)
Mean difference in the affected limb (cm; chest anteroposterior view)	0.34 (0.92)

0.50 ± 0.86 cm on Zanca views, and 0.34 ± 0.92 cm on AP chest radiographs (►**Table 1**).

Closed reduction was the most frequently used surgical technique, accounting for 75% of the cases. The mean time until bone union was 6 weeks, implant removal was performed at a mean of 7.3 months, and the union rate was of 97.22% (►**Table 1**).

The Constant-Murley (median: 100 points) and UCLA (median: 35 points) scores reflected favorable functional outcomes. Esthetic satisfaction was reported by 97.22% of the patients (►**Table 1**).

The radiographic measurements obtained on AP and Zanca views (►**Fig. 10**) showed a strong positive correlation. In contrast, the correlations regarding both methods and AP chest radiographs were moderate, indicating a less pronounced, although still positive, relationship. The Friedman test, used to compare the medians of the 3 methods, revealed no statistically significant differences ($p > 0.05$).

The models fitted to evaluate the association between fracture classification and shortening measurements did not demonstrate statistically significant associations. On AP radiographs, the estimated coefficients for fractures classified as 2B1 ($\beta = 0.1276$; $p = 0.8782$) and 2B2 ($\beta = 0.1217$; $p = 0.8906$) were positive but not statistically significant, indicating no association involving these classifications and shortening variations. On chest radiographs, although the intercept was statistically significant ($\beta = -0.4234$; $p = 0.0186$), the coefficient associated with 2B2 fractures ($\beta = 0.4584$; $p = 0.2750$) was not significant. Similarly, on

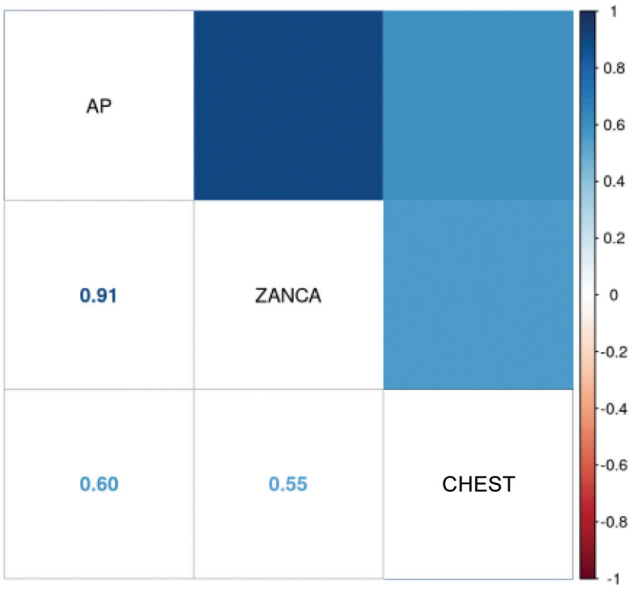

Fig. 10 Comparison of measurement methods. Anteroposterior (AP), Zanca, and chest AP radiographic views.

Table 2 Postoperative complications

Complication	n
Nonunion	1
Lateral implant migration	1
Bursitis	1
Adhesive capsulitis	1
Surgical wound drainage	1
Difficulty with implant removal	1
Posterior cortical perforation	4
Total	10

Zanca views, the estimated coefficients for 2B1 ($\beta = 1.0245$; $p = 0.2512$) and 2B2 fractures ($\beta = 1.0883$; $p = 0.2510$) also failed to reach statistical significance, despite suggesting a trend toward greater shortening.

A total of 10 patients (27.78%) experienced at least 1 complication, whereas 26 (72.22%) had no complications (►**Table 1**). Among the observed complications, there was one case of nonunion, one case of lateral implant migration without clinical consequences, one case of bursitis at the surgical approach site, one case of adhesive capsulitis, one case of persistent drainage from the surgical site, and four cases of posterior cortical penetration associated with postoperative pain (►**Table 2**). Additionally, there was one case of technical difficulty during implant removal. Complications occurred in 4 out of 9 patients (44.44%) who underwent open reduction and in 6 out of 27 patients (22.22%) who underwent closed reduction. This difference was not statistically significant ($p = 0.226$) according to the Fisher's exact test. Despite the lack of statistical significance, the observed increase in risk (odds ratio [OR] = 2.8; 95%CI: 0.57–13.83) suggests the clinical relevance of performing closed reduction whenever possible.

Discussion

The current study demonstrated a mean time until bone union of 6 weeks, which is consistent with the expected timeframe for intramedullary osteosynthesis. In the literature,[10–12] fractures treated conservatively typically achieve union within approximately 8 to 12 weeks, whereas plate fixation generally results in union between 6 and 10 weeks. These findings place the present results within the expected range for surgical treatment and reinforce the effectiveness of TEN osteosynthesis as an alternative to plate fixation for midshaft clavicle fractures.[10] The high union rate (97.22%), together with the maximum functional scores achieved, supports previous findings[13–15] demonstrating comparable outcomes between intramedullary techniques and plate fixation.

Closed reduction was the predominant approach (75%), reflecting the minimally-invasive nature of the technique. Conversion to open reduction was required in cases likely associated with greater displacement, soft-tissue interposition, or difficulty achieving adequate alignment. A higher proportion of complications was observed among patients undergoing open reduction (44.44% versus 22.22%), although the difference was not statistically significant. Among these complications, events directly related to the surgical approach deserve particular attention, such as persistent wound drainage, which resolved after appropriate clinical management. The literature[16] indicates that opening the fracture site may increase the risk of local complications and is generally reserved for cases in which closed reduction cannot be achieved.

Robinson type-2B1 fractures accounted for the majority of the cases (80.56%), a pattern classically considered suitable for intramedullary fixation.[7] The traditional indication for TEN includes diaphyseal fractures in which adequate alignment and preservation of cortical contact can be achieved.[17,18] This fracture pattern tends to maintain some degree of structural support, particularly through the posterosuperior cortex, contributing to relative stability and a lower risk of shortening. In the present study, no association was found between fracture type and the degree of shortening, which is consistent with previous reports.[12]

The mean shortening observed ranged from 0.34 to 0.50 cm, indicating the absence of clinically-relevant shortening and possibly reflecting radiographic measurement variability. The literature[1,19–22] suggests that shortening greater than 1.5 to 2.0 cm is associated with poorer functional outcomes, including residual pain and strength deficits. Therefore, our findings remain well below the thresholds often considered clinically concerning.

The complication rate (27.78%) was within the expected range for intramedullary osteosynthesis and consisted predominantly of minor events.[18,23] Among these, posterior cortical penetration associated with pain deserves particular

attention, as it has been described as a technical complication related to nail positioning.[18] Although generally not severe, it should be recognized because it may require clinical management or implant removal. Other events, such as bursitis at the nail insertion site, adhesive capsulitis, and implant migration, have also been reported in the literature,[23] and did not significantly affect functional outcomes.

The single case of nonunion represented a rare event in the present series, considering the high union rates reported in similar studies.[18,23] Despite satisfactory functional outcomes, as described in the literature,[21] revision surgery with plate fixation and autologous bone grafting was performed because of the risk of mechanical failure of the nail. This case did not significantly affect the final functional outcome.

The need for nail removal is an inherent aspect of the technique. In the present study, implant removal was performed at a mean of 7.3 months and was generally a simple outpatient procedure.[18,23] There was one case of technical difficulty during implant removal, a complication that has also been reported in the literature.[23]

The functional outcomes were excellent, with maximum scores achieved on both the Constant-Murley and UCLA scales, reflecting complete recovery in most patients. The high satisfaction rate (97.22%) reinforces the functional success of the procedure and its positive cosmetic impact, a factor that may be particularly relevant in young and active patients. Intramedullary fixation is associated with smaller incisions and less soft-tissue disruption, resulting in less conspicuous scars when compared with plate fixation, which often requires more extensive surgical approaches and may lead to implant prominence beneath the skin. These factors may directly influence patients' subjective perception of the outcome, particularly among individuals with greater cosmetic concerns. This finding is consistent with those previous studies reporting high satisfaction rates and favorable outcomes with intramedullary techniques.[24,25]

This study has limitations stemming from its retrospective design, small sample size, conduct at a single center by a single surgeon, and the absence of a control group. The loss of four patients at final follow-up may have introduced attrition bias. The predominance of Robinson 2B1 fractures limits the generalizability of the findings to more complex fracture patterns.

Conclusion

Osteosynthesis with a TEN proved to be an effective and safe method for the treatment of displaced midshaft clavicle fractures. The procedure provided excellent functional recovery, with maximum scores on the Constant-Murley and UCLA scales, as well as a high rate of esthetic satisfaction. Postoperative shortening was minimal and clinically-irrelevant, with no association with fracture type, indicating adequate restoration of clavicular length. The time until bone union was consistent with that expected for surgical treatment, and the union rate was high. The observed complications were predominantly minor and did not affect functional outcomes. Therefore, TEN fixation demonstrated consistent results regarding function, maintenance of clavicular length, bone union, esthetics, and safety, representing a viable alternative to plate fixation.

Data Availability

Data will be available upon request to the corresponding author.

Authors' Contributions

Each author contributed individually and significantly to the development of this article. FFDM: Surgery, methodology, supervision, project management, investigation, data collection, writing – original draft, validation, and final approval of the manuscript; MHGO: Data collection, investigation, and writing – original draft; and AMSA: Data collection, investigation, validation, writing – original draft, and writing – review & editing.

Financial Support

The authors declare that they did not receive financial support from agencies in the public, private, or non-profit sectors to conduct the present study.

Conflict of Interests

The authors have no conflict of interests to declare.

Acknowledgments

The authors would like to thank their colleagues from the Orthopedics and Traumatology Service at Hospital Moinhos de Vento for their technical and logistical support during data collection. The authors would also like to thank the language reviewers and collaborators who contributed to the writing and critical review of the manuscript, ensuring its clarity and scientific accuracy.

References

1 Lazarides S, Zafiropoulos G. Conservative treatment of fractures at the middle third of the clavicle: the relevance of shortening and clinical outcome. J Shoulder Elbow Surg 2006;15(02):191–194. Doi: 10.1016/j.jse.2005.08.007

2 Hoogervorst P, Van Schie P, Van den Bekerom MP. Midshaft clavicle fractures: Current concepts. EFORT Open Rev 2018;3 (06):374–380. Doi: 10.1302/2058-5241.3.170033

3 Park JS, Ko SH, Hong TH, et al. Plate fixation versus titanium elastic nailing in midshaft clavicle fractures based on fracture classifications. J Orthop Surg (Hong Kong) 2020;28(03):23094990 20972204. Doi: 10.1177/2309499020972204

4 Tornetta P III, Ricci WM, Ostrum RF, McQueen MM, McKee MD, Court-Brown CM, editors. Rockwood and Green's Fractures in Adults. 9th ed. Philadelphia: Lippincott Williams & Wilkins; 2019

5 Hoogervorst P, Van Dam T, Verdonschot N, Hannink G. Functional outcomes and complications of intramedullary fixation devices for Midshaft clavicle fractures: a systematic review and meta-analysis. BMC Musculoskelet Disord 2020;21(01):395. Doi: 10.1186/s12891-020-03256-8

6 Lu CC, Liu PC, Huang SH, Hsieh CH, Tien YC, Chien SH. Complications and technical pitfalls of titanium elastic nail fixation for midclavicular fractures. Orthopedics 2014;37(04):e377–e383. Doi: 10.3928/01477447-20140401-60

7 Robinson CM. Fractures of the clavicle in the adult. Epidemiology and classification. J Bone Joint Surg Br 1998;80(03):476–484. Doi: 10.1302/0301-620x.80b3.8079

8 Harris PA, Taylor R, Thielke R, Payne J, Gonzalez N, Conde JG. Research electronic data capture (REDCap)–a metadata-driven methodology and workflow process for providing translational research informatics support. J Biomed Inform 2009;42(02): 377–381. Doi: 10.1016/j.jbi.2008.08.010

9 Harris PA, Taylor R, Minor BL, et al; REDCap Consortium. The REDCap consortium: Building an international community of software platform partners. J Biomed Inform 2019;95:103208. Doi: 10.1016/j.jbi.2019.103208

10 Canadian Orthopaedic Trauma Society. Nonoperative treatment compared with plate fixation of displaced midshaft clavicular fractures. A multicenter, randomized clinical trial. J Bone Joint Surg Am 2007;89(01):1–10. Doi: 10.2106/JBJS.F.00020

11 Van der Meijden OA, Gaskill TR, Millett PJ. Treatment of clavicle fractures: current concepts review. J Shoulder Elbow Surg 2012; 21(03):423–429. Doi: 10.1016/j.jse.2011.08.053

12 Houwert RM, Wijdicks F-J, Bisschop CS, Verleisdonk E-J, Kruyt M. Plate fixation versus intramedullary fixation for displaced midshaft clavicle fractures: a systematic review. Int Orthop 2012;36 (03):579–585. Doi: 10.1007/s00264-011-1422-4

13 Danish M, Gupta H, Sao A, Kant R. Tens nailing in fracture clavicle: a case series. Trauma Int 2022;8(02):17–20. Doi: 10.13107/ti.2022.v08i02.029

14 Storti TM, Camilo MS, Silva RFA, Faria RSS, Simionatto CL, Paniago AF. Clinical evaluation of the treatment of clavicle fractures: Intramedullary nail x plate. Acta Ortop Bras 2021;29(01): 34–38. Doi: 10.1590/1413-785220212901231439

15 Silva FBA, Kojima KE, Silva JS, Mattar R Junior. Comparação entre o uso de placas e o de hastes flexíveis para a osteossíntese de fraturas do terço médio da clavícula – resultados preliminares. Rev Bras Ortop 2011;46(Suppl 1):34–39. Doi: 10.1590/S0102-36162011000700009

16 Ferran NA, Hodgson P, Vannet N, Williams R, Evans RO. Locked intramedullary fixation vs plating for displaced and shortened mid-shaft clavicle fractures: a randomized clinical trial. J Shoulder Elbow Surg 2010;19(06):783–789. Doi: 10.1016/j.jse.2010.05.002

17 Smekal V, Oberladstaetter J, Struve P, Krappinger D. Shaft fractures of the clavicle: current concepts. Arch Orthop Trauma Surg 2009;129(06):807–815. Doi: 10.1007/s00402-008-0775-7

18 Jubel A, Andemahr J, Bergmann H, Prokop A, Rehm KE. Elastic stable intramedullary nailing of midclavicular fractures in athletes. Br J Sports Med 2003;37(06):480–483, discussion 484. Doi: 10.1136/bjsm.37.6.480

19 Zhao JX, Zhao YP, Mao Z, et al. Intramedullary nailing versus plating fixation for the treatment of midshaft clavicular fractures: A meta-analysis of randomized controlled trials. Injury 2023;54 (Suppl 2):S70–S77. Doi: 10.1016/j.injury.2022.02.026

20 Hill JM, McGuire MH, Crosby LA. Closed treatment of displaced middle-third fractures of the clavicle gives poor results. J Bone Joint Surg Br 1997;79(04):537–539. Doi: 10.1302/0301-620x.79b4.7529

21 McKee MD, Pedersen EM, Jones C, et al. Deficits following nonoperative treatment of displaced midshaft clavicular fractures. J Bone Joint Surg Am 2006;88(01):35–40. Doi: 10.2106/JBJS.D.02795

22 Ledger M, Leeks N, Ackland T, Wang A. Short malunions of the clavicle: an anatomic and functional study. J Shoulder Elbow Surg 2005;14(04):349–354. Doi: 10.1016/j.jse.2004.09.011

23 Mueller M, Burger C, Florczyk A, Striepens N, Rangger C. Elastic stable intramedullary nailing of midclavicular fractures in adults: 32 patients followed for 1-5 years. Acta Orthop 2007;78(03): 421–423. Doi: 10.1080/17453670710014013

24 Andrade-Silva FB, Kojima KE, Joeris A, Silva JS, Mattar R Jr. Single, superiorly placed reconstruction plate compared with flexible intramedullary nailing for midshaft clavicular fractures: a prospective, randomized controlled trial. J Bone Joint Surg Am 2015; 97(08):620–626. Doi: 10.2106/JBJS.N.00497

25 Ban I, Troelsen A, Christiansen DH, Svendsen SW, Kristensen MT. Standardized outcome reporting in clavicle fracture studies: a systematic review. J Shoulder Elbow Surg 2014;23(07):e1–e10