Article published online: 2025-07-15

Medial Thigh Cutaneous Flap Irrigated by Perforating Vessels of the Secondary Pedicle of the Gracilis Muscle: Anatomical Study and Clinical Case Report

Retalho cutâneo medial da coxa irrigado por vasos perfurantes do pedículo secundário do músculo grácil: Estudo anatômico e relato de caso clínico

Gabriel Vique Valeriano[1] Antonio Carlos da Costa[1] Diego Figueira Falcochio[1] Yussef Ali Abdouni[1]

[1] Hand Surgery and Microsurgery Group, Department of Orthopedics and Traumatology, Irmandade da Santa Casa de Misericórdia de São Paulo (DOT/ISCMSP), São Paulo, SP, Brazil

Rev Bras Ortop 2025;60(2):s00451809398.

Address for correspondence Gabriel Vique Valeriano, Departamento de Ortopedia e Traumatologia, Irmandade da Santa Casa de Misericórdia de São Paulo, Rua Martinico Prado, 284, apto. 53, Vila Buarque, São Paulo, 01221–010, SP, Brazil (e-mail: gviquev@hotmail.com).

Abstract

Objective To analyze the anatomy of the perforating vessels irrigating the skin of the medial aspect of the thigh and originating from the secondary vascular pedicle of the gracilis muscle.

Methods We dissected 33 thighs from cadavers of both sexes to record and analyze the characteristics of the blood vessels irrigating the gracilis muscle in the middle third of the thigh.

Results All thighs (100%) had a secondary vascular pedicle in the intermuscular septum between the gracilis and vastus medialis/sartorius muscles, with branches irrigating the overlying skin on the medial aspect. The pedicle presented an arterial diameter ranging from 1.3 to 4.6 mm (mean: 2.3 mm) and a length ranging from 28 to 84 mm (mean: 50.6 mm). In 87.8% of the cases, the pedicle irrigated the gracilis muscle and presented vessels to the overlying skin.

Conclusion Based on the data found, we conclude that it is feasible to obtain a reliable flap from the medial aspect of the middle third of the thigh.

Keywords
- gracilis muscle
- surgical flaps
- thigh

Resumo

Objetivo Estudar a anatomia dos vasos perfurantes que irrigam a pele da face medial da coxa, provenientes do pedículo vascular secundário do músculo grácil.

Métodos Foram dissecadas 33 coxas de cadáveres de ambos os sexos, e registradas e analisadas as características dos vasos sanguíneos que irrigam o músculo grácil no terço médio.

Study performed at the Department of Orthopedics and Traumatology, Irmandade da Santa Casa da Misericórdia de São Paulo (DOT/ISCMSP), São Paulo, SP, Brazil.

received
October 2, 2024
accepted
March 13, 2025

DOI https://doi.org/10.1055/s-0045-1809398.
ISSN 0102-3616.

© 2025. The Author(s).
This is an open access article published by Thieme under the terms of the Creative Commons Attribution 4.0 International License, permitting copying and reproduction so long as the original work is given appropriate credit (https://creativecommons.org/licenses/by/4.0/)

Thieme Revinter Publicações Ltda., Rua Rego Freitas, 175, loja 1, República, São Paulo, SP, CEP 01220-010, Brazil

Resultados Em todas as coxas (100%) foi evidenciada a presença de um pedículo vascular secundário no septo intermuscular entre os músculos grácil e vasto medial/sartório, com ramos que irrigam a pele suprajacente na face medial. O pedículo apresentou um diâmetro arterial que variou de 1,3 a 4,6 mm (média de 2,3 mm) e comprimento entre 28 e 84 mm (média de 50,6 mm). Em 87,8% dos casos, o pedículo irrigava o músculo grácil e apresentava vasos para a pele suprajacente.

Conclusão Com base nos dados encontrados, podemos concluir que é possível obter um retalho confiável da face medial do terço médio da coxa.

Palavras-chave
- coxa
- músculo grácil
- retalhos cirúrgicos

Introduction

Injuries resulting from high-energy trauma, mainly traffic accidents, often involve soft tissue loss and exposure of essential structures, such as bones, tendons, vessels, and nerves.[1] These therapeutic situations are difficult to manage and challenging for the reconstructive surgeon.

The improvements in surgical techniques have increased treatment success rates. Today, free flaps are an effective option among reconstructive techniques. Perforator flaps are an evolution of microsurgical flaps, enabling the creation of thinner flaps and resulting in better functional and esthetic outcomes.[2]

In 1967, Fujino[3] documented the distribution of perforating arteries to supply the interstitium, similar to axial arteries. In 1988, Koshima et al.[4] pioneered perforating artery-based flaps exclusively consisting of skin and subcutaneous tissue. Wei et al.[5] defined perforating artery-based flaps as those supplied by arteries crossing the adjacent deep fascia and making it feasible to dissection through the muscle or the intermuscular septum to their vessel of origin, with no need for muscle inclusion in the flap.

Focusing on the medial aspect of the thigh, certain authors, such as Peek et al.[6] and Eom et al.,[7] described, in anatomical studies and case reports, a flap from this region based on the perforating arteries originating from the main vascular pedicle of the gracilis muscle. This flap has been widely studied and may be used in its pedicled or free form to cover different defects in the inguinal region or distant areas.

Feng et al.,[8] Scaglioni et al.,[1] and Zheng et al.[9] also described, through anatomical studies and some clinical cases, the anteromedial thigh flap or lower medial thigh flap based on perforating branches from muscular arteries irrigating the vastus medialis muscle. In 1984, Song et al.[10] described the perforating flap from the deep femoral artery, harvested from the posteromedial aspect of the thigh.

The gracilis muscle, in the medial region of the thigh, is commonly used as a functional free muscle flap. Mathes and Nahai[11] classified its irrigation pattern as type 2, that is, muscle irrigation occurs by a dominant vascular pedicle, able to supply the entire muscle, but with the contribution of several smaller secondary pedicles. Some branches of these vessels cross the deep fascia in the medial region of the thigh and irrigate the subcutaneous tissue and overlying skin. In an anatomical study with arteriography, Peek et al.[6] identified the presence of a secondary pedicle in the intermediate region of the thigh with multiple intramuscular anastomoses with the main vascular pedicle.

The objective of the present study was to evaluate the anatomical parameters of the vessels irrigating the skin and fascia of the medial region of the thigh, originating from the secondary vascular pedicle of the gracilis muscle in the middle third of the thigh, defining its location, diameter, distribution pattern, and anatomical variations, showing the feasibility of obtaining a reliable flap based on this vascular pedicle.

Materials and Methods

The institutional Ethics Committee approved the study under number CAAE: 15621319.1.0000.5479.

We performed microsurgical dissection of 33 thighs from 18 cadavers. In total, 19 thighs were from male cadavers, and 14, from female cadavers. We recorded biometric data of the cadavers, such as age, height, and weight. We excluded cadavers with peripheral vascular disease as the known cause of death and those with scars in the dissection region.

The same surgeon performed all dissections using a surgical magnifying glass with 3.5x magnification. We recorded anatomical parameters of the vascular pedicle, such as vessel length, diameter, location, origin, and distribution, in addition to their relationship with thigh length. We obtained the measurements using a millimeter tape and a digital four-dimensional 150-mm caliper (Digimess Instrumentos de Precisão Ltda.).

The Kolmogorov-Smirnov test assessed the normal distribution of the quantitative outcome variables. The analysis of quantitative variables used the equality of two proportions and Pearson's correlation tests. The statistical confidence interval was of 95%.

Dissection

Initially, we drew a line on the medial aspect of the thigh, from the ischiopubic ramus to the medial femoral epicondyle (►**Fig. 1**). This line coincided with the anterior border of the gracilis muscle. At the midpoint of this line, we drew a circle with a 3-cm radius divided into quadrants. Next, we made the incision following the circle contour. Then, we identified the perforating arteries by gentle dissection of the

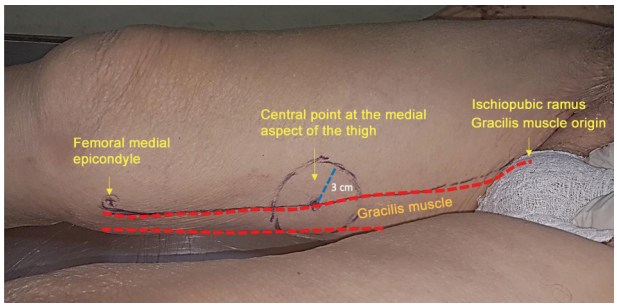

Fig. 1 Medial aspect of the right thigh with a drawing showing the location of the vascular pedicle.

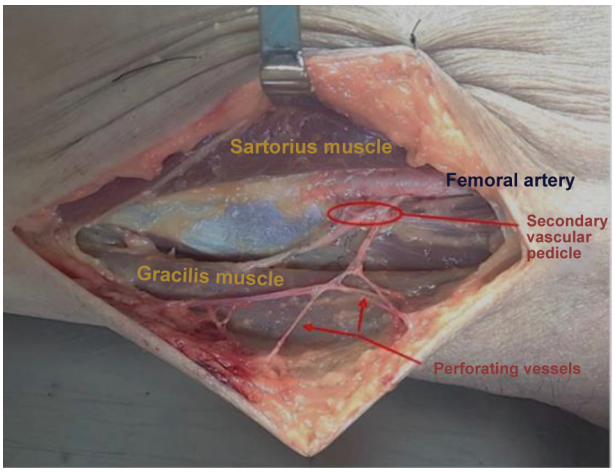

Fig. 2 Dissection of the secondary vascular pedicle of the gracilis muscle with its perforating vessels.

subcutaneous tissue, following them to the septum between the gracilis muscle and the vastus medialis/sartorius muscle. Most vessels identified in the intermuscular septum had muscular branches to the gracilis muscle and, in a few cases, to the sartorius muscle. These septal vessels gave off perforating branches to irrigate the skin and overlying subcutaneous tissue. The dissection continued deep into the femoral artery, which was identified as the arterial origin in all cases (►**Fig. 2**). The veins, usually two, were tributaries of the femoral vein, not of the great saphenous vein, which was close to the dissection site. The branch leading to the gracilis or sartorius muscle underwent ligation, preserving its proximal part. We did the same thing with the perforating veins leading to the skin, increasing the length of the vessels. We selected and documented vessels with an external diameter greater than 0.5 mm.

Table 1 Anthropometric data

Thigh number	Age (years)	Side	Sex	Height (cm)	Weight (kg)	Thigh length (inguinal-medial femoral condyle) (cm)
1	56	Right	Male	176	70	38
2	56	Left	Male	176	70	38
3	62	Right	Male	174	66	36
4	62	Left	Male	174	66	36
5	56	Right	Male	165	88	36
6	52	Right	Male	172	78	35
7	52	Left	Male	172	78	35
8	56	Right	Male	176	84	35
9	52	Right	Male	150	43	35
10	52	Left	Male	150	43	35
11	64	Right	Male	167	61	30
12	64	Left	Male	167	61	30
13	58	Right	Male	170	70	30
14	58	Left	Male	170	70	30
15	59	Right	Female	169	95	30
16	59	Left	Female	169	95	30
17	42	Right	Male	182	76	35
18	42	Left	Male	182	76	35
19	66	Left	Male	175	74	26
20	58	Right	Male	175	86	34
21	58	Left	Male	175	86	34
22	92	Right	Female	164	68	28

(*Continued*)

Table 1 (*Continued*)

Thigh number	Age (years)	Side	Sex	Height (cm)	Weight (kg)	Thigh length (inguinal-medial femoral condyle) (cm)
23	92	Left	Female	164	68	28
24	47	Right	Female	160	65	29
25	47	Left	Female	160	65	29
26	36	Right	Female	165	70	33
27	36	Left	Female	165	70	33
28	92	Right	Female	163	55	32
29	92	Left	Female	163	55	32
30	85	Right	Female	157	42	29
31	85	Left	Female	157	42	29
32	38	Right	Female	160	62	29
33	38	Left	Female	160	62	29
Mean	**57.8**			**162.5**	**66.5**	**31.3**
Maximum	**92**			**182**	**95**	**38**
Minimum	**36**			**150**	**42**	**26**

Table 2 Vascular pedicle features

Thigh number	Pedicle length (mm)	Artery diameter (mm)	Vein diameter (mm)	Origin	Irrigated muscle	Quadrant	Variation
1	53	3.8	3	Femoral	Gracilis	Anterosuperior	
2	48	3.4	3.2	Femoral	Gracilis	Anterosuperior	
3	83	4.2	3.2	Femoral	Gracilis	Anterosuperior	
4	76	4.6	3.6	Femoral	Gracilis	Anterosuperior	
5	32	2.1	1.8	Femoral	None	Anteroinferior/ Anterosuperior	No muscular branch
6	41	3.6	3.4	Femoral	Gracilis	Anteroinferior	
7	38	3.4	3.2	Femoral	Gracilis	Anteroinferior	
8	63	3.2	2.8	Femoral	Sartorius	Anterosuperior	Branch to the sartorius muscle
9	38	2	2	Femoral	Gracilis	Anterosuperior	
10	32	2.2	1.8	Femoral	Gracilis	Anterosuperior	
11	32	1.3	1	Femoral	Gracilis	Anterosuperior	
12	28	1.5	1.2	Femoral	Gracilis	Antroinferior	
13	78	1.6	1.4	Femoral	Gracilis	Anterosuperior	
14	45	2.5	2	Femoral	Gracilis	Anterosuperior	
15	84	1.8	1.8	Femoral	Gracilis	Anterosuperior	
16	76	1.6	1.6	Femoral	Gracilis	Anterosuperior	
17	38	1.3	1.2	Femoral	Gracilis	Anterosuperior	
18	40	1.4	1.2	Femoral	Gracilis	Anterosuperior	
19	32	1.6	1.4	Femoral	Gracilis	Anterosuperior	
20	40	2.2	2	Femoral	Sartorius	Anterosuperior	Branch to the sartorius muscle
21	38	2	2	Femoral	Sartorius	Anterosuperior	

Table 2 (*Continued*)

Thigh number	Pedicle length (mm)	Artery diameter (mm)	Vein diameter (mm)	Origin	Irrigated muscle	Quadrant	Variation
							Branch to the sartorius muscle
22	62	1.5	1.5	Femoral	Gracilis	Anterosuperior	
23	60	1.3	1.5	Femoral	Gracilis	Anterosuperior	
24	58	2	1.8	Femoral	Gracilis	Antroinferior	
25	61	2.4	1.9	Femoral	Gracilis	Anteroinferior	
26	64	2.7	2.2	Femoral	Gracilis	Anterosuperior	
27	68	2.4	2.3	Femoral	Gracilis	Anterosuperior	
28	56	1.8	1.6	Femoral	Gracilis	Anterosuperior	
29	42	2.8	2	Femoral	Gracilis	Anterosuperior	
30	56	2.8	2.3	Femoral	Gracilis	Anterosuperior	
31	58	2.5	2.2	Femoral	Gracilis	Anterosuperior	
32	52	2	1.8	Femoral	Gracilis	Anterosuperior	
33	50	1.8	1.6	Femoral	Gracilis	Anterosuperior	
Mean	**50.6**	**2.3**	**2.0**				
Maximum	**84**	**4.6**	**3.6**				
Minimum	**28**	**1.3**	**1**				

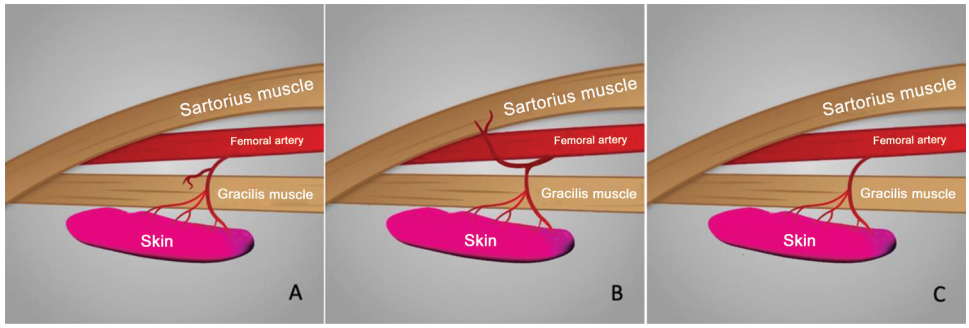

Fig. 3 Arterial distribution patterns. Vessels with branches to the gracilis muscle (**A**). Vessels with branches to the sartorius muscle (**B**). Direct perforating vessels, with no muscular ramifications (**C**).

Results

►**Table 1** shows the anthropometric data of the dissected cadavers, and ►**Table 2** shows the flap vessel features.

In all dissections (100%), we identified at least 1 artery accompanied by 2 veins and considered them viable for flap creation. All of these vessels were in the intermuscular septum between the gracilis and vastus medialis/sartorius muscles. In 29 (87.8%) of the 33 thighs, the main vessel was a septocutaneous artery with branches to the gracilis muscle; in 3 (9.1%) thighs, the septocutaneous arteries provided branches to the sartorius muscle; and 1 thigh (3%) had two direct septocutaneous arteries with no muscular branches (►**Fig. 3**).

All cases had at least 1 artery and 1 vein with an external diameter greater than 0.5 mm. The largest diameter was of 4.6 mm, and the smallest, of 1.3 mm. The mean artery diameter was of 2.3 mm. In general, there were 2 veins for each artery. The largest vein diameter was of 3.6 mm, and the smallest, of 1.0 mm, with a mean of 2.0 mm (►**Fig. 4**). The length of the vessels, from their origin in the femoral vessels to the smaller branches in the subcutaneous tissue, ranged from 28 mm to 84 mm, with a mean of 53.2 mm.

The statistical analysis started with the Kolmogorov-Smirnov parametric test to assess the normality of the distribution of the quantitative variables, and we concluded that there was a normal distribution. Regarding the distribution of the relative frequency (percentages) of qualitative factors, by applying the equality of two proportions test, we observed that the pedicle was in the anterosuperior quadrant in 84.8% of the dissected thighs. In addition, we noted that the gracilis was the muscle most commonly irrigated by this pedicle, corresponding to 87.9% ($p < 0.001$) of the cases (►**Tables 3**, **4**, respectively).

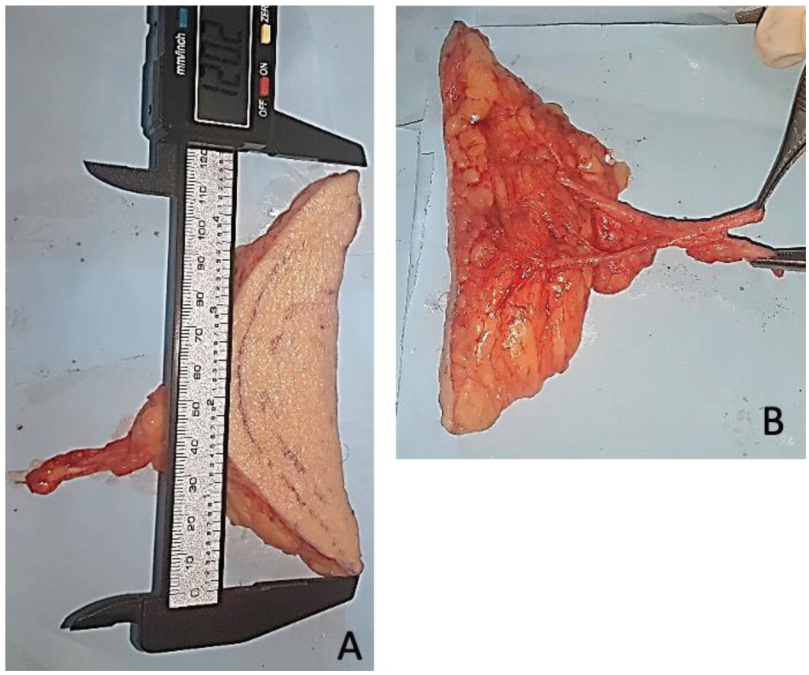

Fig. 4 Isolated flap with an approximate length of 12 cm (A). Vascular pedicle (B).

Table 3 Pedicle location at anteroinferior and anterosuperior quadrants

		n	%	*p*-value
Quadrant	Anteroinferior Anterosuperior	5 28	15.2% 84.8%	< 0.001

Table 4 Muscles irrigated by the vascular pedicle

		n	%	*p*-value
Irrigated muscle	Gracilis None Sartorius	29 1 3	87.9% 3.0% 9.1%	< 0.001 < 0.001

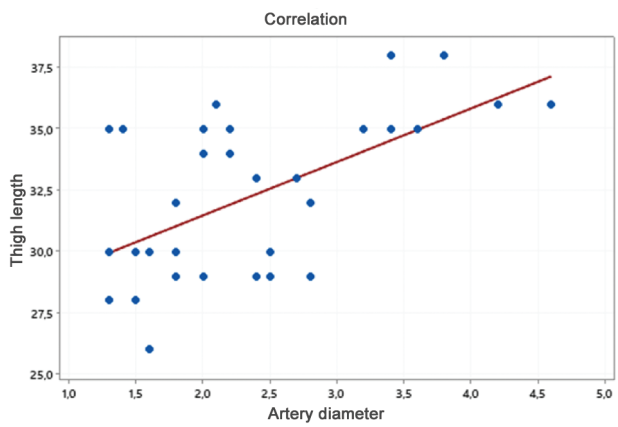

Fig. 5 Relationship between thigh length and artery diameter.

The Pearson test analyzed the correlation among these variables. It revealed a significant and directly-proportional association between vessel diameter and thigh length ($p < 0.001$) (►**Fig. 5**).

Discussion

According to Giordano et al.[12] and Peek et al.,[6] the gracilis muscle receives blood supply from a proximal main pedicle originating from the medial circumflex femoral artery and at least two distal secondary pedicles originating from the femoral or popliteal artery. Most of these primary and secondary pedicles have branches piercing the deep fascia and irrigating a considerable skin area over the gracilis muscle, corresponding to at least twice the width of this muscle. The anatomical characteristics of the main pedicle are well-known, resulting in reliable parameters to create gracilis or musculocutaneous flaps. However, the literature is scarce on secondary pedicles and their potential use as fasciocutaneous flaps.

The most common flaps are the proximal fasciocutaneous flaps of the thigh, irrigated by branches of the main pedicle of the gracilis muscle. Gracilis flaps are used widely in their pedicled and free forms. However, they compromise the main pedicle of the gracilis muscle and require care with the branches of the obturator nerve at the dissection site. The main vascular pedicle flap, harvested from the proximal medial region of the thigh, is in an area more susceptible to contamination and with limited access to postoperative dressings.[6]

Scaglioni et al.[1] described some flaps of the anteromedial region in the distal region of the thigh based on the perforating musculocutaneous vessels crossing the vastus medialis. However, an adequate-length pedicle requires



Fig. 6 Primary closure of the donor area.

intramuscular dissection, and the scar area is more exposed compared with the main pedicle flap. Song et al.[10] and Algan and Tan[13] described a reliable flap originating from perforators of the deep femoral artery in this region, but often the patient's positioning makes it impossible to harvest it.

The proposed flap is on the medial side of the middle third of the thigh. After flap removal, primary closure of the donor area can be performed without the need for a skin graft. The scar is in a region of little exposure. The donor area is further away from the inguinal and perineal regions when compared with the main pedicle flap. Dressing change is more comfortable, and the prevention of contamination and infection is more reliable.

The mean arterial diameter in the current study was of 2.3 mm. According to Jacobson and Suarez,[14] this value is safe for vascular anastomoses in free flaps. The mean length of the pedicle was of 50.6 mm, which is adequate for free or pedicled flaps. However, in one of the dissections, we identified a pedicle shorter than 30 mm (28 mm), that is, a relatively short pedicle that would hinder anastomosis and depend on the area and the recipient's vessel.

Some interesting parameters found in the dissection included the following: all vascular pedicles were in the central region of the medial aspect of the thigh, within a circle with 6 cm in diameter, whose central point coincided with the anterior border of the gracilis muscle; the arterial origin was in the anterosuperior quadrant of the circle in 87.8% of the cases, and most of the vessels (87.8%) were septocutaneous vessels, with branches to the gracilis muscle. The greater saphenous vein requires care, as it is often included in the flap design and should be ligated and included in the flap if it is impossible to isolate.

According to Giordano et al.,[12] the width of the skin irrigated by the perforating vessels would correspond to at least twice the width of the underlying gracilis muscles. Closure of the donor area closure could be performed primarily, with relative ease, with no need for skin grafting (►**Fig. 6**).

The parameters found will enable the safe dissection and removal of a microsurgical flap. The skin of the medial region of the thigh is thinner and more versatile. A flap from this region is appropriate for covering small and medium-sized defects (shorter than 15 cm in diameter).

Case series[15,16] conducted in recent years have demonstrated the advantages of using perforating vessel flaps to obtain less bulky and malleable flaps; however, the flap herein presented was not described in any of these studies.

To demonstrate flap viability, we performed surgery on a young male patient who had been involved in a traffic accident and, in addition to multiple fractures on his right foot, had lost skin on the medial surface extending to the plantar surface, exposing tendons and the plantar aponeurosis (►**Fig. 7**). We performed microsurgical coverage with the flap described, with anastomosis of its vessels in branches and tributaries of the posterior tibial vessels. The procedure was successful, thus demonstrating technical viability (►**Fig. 7** and ►**Fig. 8**).

In our opinion, one of the best indications for this flap would be upper limb skin coverage, which requires thin and malleable skin and donor vessels of smaller caliber. We

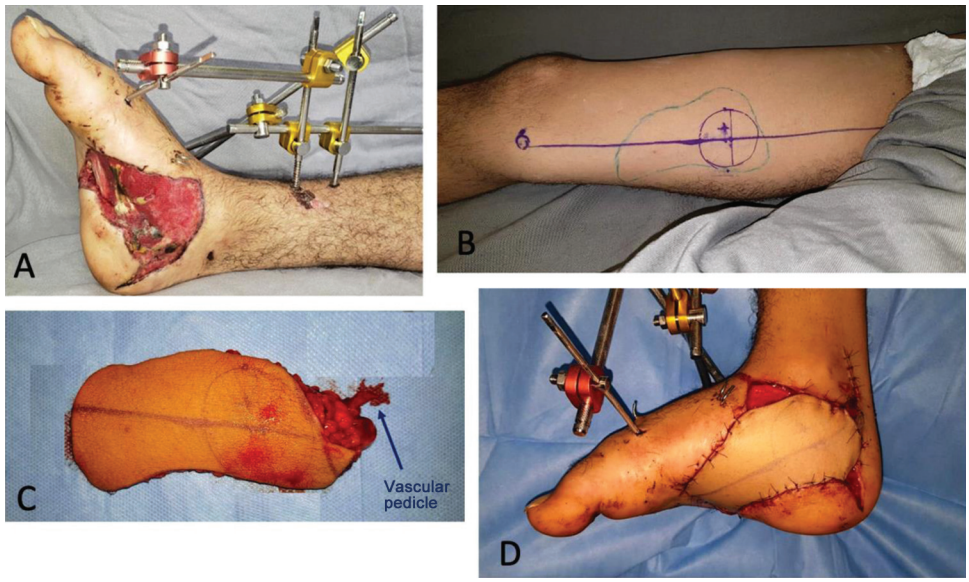

Fig. 7 Operated case. Right foot with inferomedial defect coverage (**A**). Medial aspect of the right thigh with a drawing of the flap and location of the vascular pedicle (**B**). Isolated flap (**C**). Defect coverage with anastomosis in the posterior tibial vessels (**D**).



Fig. 8 Operated case at three months of postoperative follow-up.

intend to perform a series of cases using this flap type for later publication of the outcomes, showing the positive and negative points.

Conclusion

We found the secondary pedicle of the gracilis muscle, which provides septocutaneous and perforating branches to the skin of the medial thigh, in all dissected thighs (100%). Therefore, this is a reliable option to obtain a fasciocutaneous flap from this region.

Authors' Contributions

Each author contributed individually and significantly to the development of the present article. GVV: writing – original draft, cadaveric dissection, clinical case surgery, and data collection and analysis. ACC: clinical case surgery, methodology, formal analysis, and writing – review & editing. DFF: statistical analysis, validation, and writing – review & editing, and formal analysis. YAA: methodology, conceptualization, and writing – review & editing.

Financial Support

The authors declare that they did not receive financial support from agencies in the public, private or non-profit sectors to conduct the present study.

Conflict of Interests

The authors have no conflict of interests to declare.

References

1 Scaglioni MF, Fakin RM, Giovanoli P, Kuo YR, Kuo PJ. The lower medial thigh perforator (LMTP) flap for lower extremity reconstruction: Preliminary results. Microsurgery 2016;36(06): 474–479. Doi: 10.1002/micr.30030
2 Kim JT, Kim SW. Perforator Flap versus Conventional Flap. J Korean Med Sci 2015;30(05):514–522. Doi: 10.3346/jkms.2015.30.5.514
3 Fujino T. Contribution of the axial and perforator vasculature to circulation in flaps. Plast Reconstr Surg 1967;39(02):125–137. Doi: 10.1097/00006534-196702000-00001
4 Koshima I, Soeda S, Yamasaki M, Kyou J. The free or pedicled anteromedial thigh flap. Ann Plast Surg 1988;21(05):480–485. Doi: 10.1097/00000637-198811000-00015
5 Wei FC, Jain V, Suominen S, Chen HC. Confusion among perforator flaps: what is a true perforator flap? Plast Reconstr Surg 2001;107 (03):874–876. Doi: 10.1097/00006534-200103000-00037
6 Peek A, Müller M, Ackermann G, Exner K, Baumeister S. The free gracilis perforator flap: anatomical study and clinical refinements of a new perforator flap. Plast Reconstr Surg 2009;123(02): 578–588. Doi: 10.1097/PRS.0b013e3181956519
7 Eom JS, Sun SH, Hong JP. Use of the upper medial thigh perforator flap (gracilis perforator flap) for lower extremity reconstruction. Plast Reconstr Surg 2011;127(02):731–737. Doi: 10.1097/PRS.0b013e3181fed789
8 Feng CH, Yang JY, Chuang SS, Huang CY, Hsiao YC, Lai CY. Free medial thigh perforator flap for reconstruction of the dynamic and static complex burn scar contracture. Burns 2010;36(04): 565–571. Doi: 10.1016/j.burns.2009.07.005
9 Zheng H, Wang H, Zhang F, Yue S. Anatomic basis of perforator flaps of medial vastus muscle. Microsurgery 2008;28(01):61–64. Doi: 10.1002/micr.20446
10 Song YG, Chen GZ, Song YL. The free thigh flap: a new free flap concept based on the septocutaneous artery. Br J Plast Surg 1984; 37(02):149–159. Doi: 10.1016/0007-1226(84)90002-x
11 Mathes SJ, Nahai F. Classification of the vascular anatomy of muscles: experimental and clinical correlation. Plast Reconstr Surg 1981;67(02):177–187
12 Giordano PA, Abbes M, Pequignot JP. Gracilis blood supply: anatomical and clinical re-evaluation. Br J Plast Surg 1990;43 (03):266–272. Doi: 10.1016/0007-1226(90)90071-7
13 Algan S, Tan O. Profunda femoris artery perforator flaps: a detailed anatomical study. J Plast Surg Hand Surg 2020;54(06): 377–381. Doi: 10.1080/2000656X.2020.1801456
14 Jacobson JH, Suarez EL. Microsurgery in anastomosis of small vessels. Surg Forum 1960;11:243–245
15 Abdelfattah U, Power HA, Song S, Min K, Suh HP, Hong JP. Algorithm for Free Perforator Flap Selection in Lower Extremity Reconstruction Based on 563 Cases. Plast Reconstr Surg 2019;144 (05):1202–1213. Doi: 10.1097/PRS.0000000000006167
16 Scaglioni MF, Meroni M, Knobe M, Fritsche E. Versatility of perforator flaps for lower extremity defect coverage: Technical highlights and single center experience with 87 consecutive cases. Microsurgery 2022;42(06):548–556. Doi: 10.1002/micr.30892