Article published online: 2025-06-23

Treatment of Focal Chondral Lesions in the Patellofemoral Joint with Collagen Membrane: Clinical and Functional Outcomes in a Two-Year Follow-Up

Tratamento de lesões condrais focais na articulação patelofemoral com membrana de colágeno: Resultados clínicos e funcionais em seguimento de dois anos

Pedro Debieux[1,2,3] José Ricardo Dantas Moura Costa[4] Wesley Araujo Weis[5]
Diego da Costa Astur[3,4] Camila Cohen Kaleka[1,3] Moisés Cohen[1,3]

[1] Department of Orthopedic Surgery, Hospital Israelita Albert Einstein, São Paulo, SP, Brazil
[2] Department of Orthopedic Surgery, Hospital Beneficência Portuguesa de São Paulo, São Paulo, SP, Brazil
[3] Department of Orthopedic Surgery, Instituto Cohen, São Paulo, SP, Brazil
[4] Sports Traumatology Center, Department of Orthopedics and Traumatology, Escola Paulista de Medicina, Universidade Federal de São Paulo, São Paulo, SP, Brazil
[5] Department of Orthopedics, Empresa Cuiabana de Saúde Pública, Cuiabá, MT, Brazil

Address for correspondence Pedro Debieux, Departamento de Cirurgia Ortopédica, Hospital Beneficência Portuguesa de São Paulo, Rua Maestro Cardin, 637, Bela Vista, São Paulo, SP 01323-001, Brazil (e-mail: pedrod.ortop@gmail.com).

Rev Bras Ortop 2025;60(2):s00451809338.

Abstract

Objective To evaluate the clinical and functional outcomes of patients undergoing surgical treatment to repair focal chondral lesions in the patella and trochlea using the autologous matrix-induced chondrogenesis (AMIC) technique after a minimum follow-up of 2 years.

Methods A total of 24 patients (25 knees) with a mean age of 39.6 ± 4.7 years underwent the patellofemoral AMIC technique and evaluation over a mean follow-up of 3.64 ± 0.65 years. We collected data on patient factors, lesion morphology, and patient-reported outcome measures, including the International Knee Documentation Committee (IKDC), Tegner, Kujala, Fulkerson, and Lysholm scores, as well as the Visual Analog Scale (VAS).

Results Male subjects accounted for 76% of the sample. The mean defect size of the chondral lesions was of $1.99 \pm 0.36\,cm^2$. All defects were of grade IV according to the Outerbridge classification. At the last follow-up, patients showed the following mean increases in the scores: Kujala – from 61.9 to 87.9; IKDC –from 51.3 to 83.6; Lysholm –from

Keywords
- cartilage, articular
- chondrogenesis
- knee injuries

Study developed at Sports Traumatology Center, Department of Orthopedics and Traumatology, Escola Paulista de Medicina, Universidade Federal de São Paulo, São Paulo, SP, Brazil.

received
September 3, 2024
accepted
March 7, 2025

DOI https://doi.org/10.1055/s-0045-1809338.
ISSN 0102-3616.

© 2025. The Author(s).
This is an open access article published by Thieme under the terms of the Creative Commons Attribution 4.0 International License, permitting copying and reproduction so long as the original work is given appropriate credit (https://creativecommons.org/licenses/by/4.0/)

Thieme Revinter Publicações Ltda., Rua Rego Freitas, 175, loja 1, República, São Paulo, SP, CEP 01220-010, Brazil

64.0 to 88.4; Tegner –from 4.04 to 5.12; Fulkerson –from 60.2 to 89.3; and VAS – from 5.6 to 1.24. All results were statistically significant ($p < 0.05$).

Conclusion The AMIC technique is a safe, effective, and feasible method to treat symptomatic full-thickness chondral defects of the patellofemoral cartilage in properly-selected cases, and it resulted in clinical and functional improvement in all criteria under analysis.

Resumo

Objetivo Avaliar os desfechos clínicos e funcionais de pacientes submetidos a tratamento cirúrgico para reparo de lesão condral focal na patela e na tróclea, pela técnica de condrogênese induzida por matriz autóloga (*autologous matrix-induced chondrogenesis*, AMIC, em inglês), após um mínimo de 2 anos de tratamento.

Métodos Ao todo, 24 pacientes (25 joelhos) com idade média de $39,6 \pm 4,7$ anos foram submetidos à técnica AMIC patelofemoral e foram avaliados em um seguimento médio de $3,64 \pm 0,65$ anos. Os fatores dos pacientes, a morfologia da lesão e as medidas de resultado relatadas pelos pacientes, incluindo os escores do International Knee Documentation Committee (IKDC), de Tegner, de Kujala, de Fulkerson, de Lysholm, e a Escala Visual Analógica (EVA), foram coletados.

Resultados O sexo masculino representou 76% da amostra. O tamanho médio do defeito das lesões condrais foi de $1,99 \pm 0,36\,cm^2$. Todos os defeitos foram classificados como de grau IV, de acordo com a classificação de Outerbridge. No seguimento final, os pacientes apresentaram os seguintes aumentos na pontuação média nos escores: Kujala – de 61,9 para 87,9; IKDC – de 51,3 para 83,6; Lysholm – de 64,0 para 88,4; Tegner – de 4,04 para 5,12; Fulkerson – de 60,2 para 89,3; e EVA – de 5,6 para 1,24. Todos os resultados apresentaram significância estatística ($p < 0,05$).

Conclusão A AMIC é um método seguro, eficaz e viável para o tratamento de defeitos condrais sintomáticos, de espessura total da cartilagem femoropatelar, em casos adequadamente selecionados, e resultou em melhora clínica e funcional em todos os critérios analisados.

Palavras-chave
- cartilagem articular
- condrogênese
- traumatismos do joelho

Introduction

Articular cartilage is a highly specialized tissue whose main function is to enable multiplanar movement of the joint under several conditions of applied load.[1] Another significant role of hyaline cartilage is its ability to transmit load to the adjacent subchondral bone without damaging it. In addition, it provides a smooth, lubricated, low-friction surface that enables the maintenance of joint homeostasis.[2]

Lesions affecting the patellofemoral region occur in up to one-third of the cases, and they can result in severely-limiting symptoms.[3,4] The most common causes include trauma, patellar dislocation, misalignment, and instability.[3,5] These lesions remain a significant challenge for orthopedic surgeons.[6–8] Several treatments have been proposed, with the recommendation of surgical therapy in cases in which conservative modalities have not been successful. The options available include microperforations, autologous chondrocyte implantation, and autologous osteochondral graft, but the ideal treatment remains controversial.[3,9]

Autologous matrix-induced chondrogenesis (AMIC) is part of this technical arsenal to repair focal full-thickness cartilage lesions. This technique stimulates the bone marrow through microfractures and lesion covering with type-I and -III collagen membrane to contain the formed clot and promote adhesion, proliferation, and cell differentiation.[7–13] Notably effective in treating condylar chondral lesions, reports of outcomes from this technique on isolated patellofemoral compartment lesions are lacking.[9,14] However, since its introduction, AMIC has demonstrated good short- and medium-term outcomes.[7,8,10,15–17]

Therefore, the present study aimed to analyze the clinical outcomes of patients undergoing surgical treatment to repair focal chondral lesions in the patella and trochlea using the AMIC technique with a follow-up of 2 years.

Materials and Methods

The current is a descriptive and observational case series study. We obtained data by analyzing medical records of patients who underwent surgical treatment to repair focal chondral lesions in the patella or trochlea using the AMIC

technique from 2015 to 2020. The institutional Ethics in Research Committee approved the study under number CAAE 65062522.9.0000.5505.

A single surgeon operated on 24 patients (25 knees), 19 men and 5 women, who were followed up for at least 2 years after the surgical procedure. All received detailed guidance on the proposed surgical technique and other available treatment options, with their respective advantages and disadvantages, and agreed with the procedure chosen.

The inclusion criteria were age from 15 to 60 years, diagnosis of focal chondral lesion in the patella or trochlea with an area ranging from 0.5 cm^2 to 4.0 cm^2, International Cartilage Repair Society (ICRS) classification grade III or IV, regular physical activity, and lack of response to conservative treatment with physical therapy and functional rehabilitation for up to 6 weeks. The exclusion criteria were patellar malalignment, subchondral bone (osteochondral) lesions, advanced osteoarthritis (grade $\geq$ 2 on the Ahlbäck radiographic classification), and a history of cartilage repairs or concomitant procedures, such as meniscal repair or ligament reconstruction.

All patients with suspected patellar or trochlear chondral lesions underwent a preoperative evaluation, including radiographs and magnetic resonance imaging (MRI) scans to characterize and measure the chondral injury and identify potential ligament injuries or malalignments in the lower limbs. This approach enabled a careful selection of participants meeting the inclusion criteria.

Surgical Technique

The procedure begins with arthroscopy for a detailed evaluation of the chondral lesion and diagnostic confirmation, followed by medial or lateral parapatellar arthrotomy depending on the location of the lesion. After patellar eversion, the edges of the lesion are molded to create stable vertical walls of healthy adjacent cartilage (►**Fig. 1**). The defect is marked and curetted down to its calcified layer, followed by nanoperforation of the subchondral bone. Then, the porcine collagen type-I and -III membrane (Chondro-Gide, Geistlich Pharma AG) is applied over the lesion and fixed with 5–0 monofilament suture (PDS, Ethicon, Inc.), reinforced with fibrin glue (Tisseel, Baxter Medical Pharmaceutical Ltd.) at the edges (►**Fig. 1**).

Rehabilitation

Postoperative rehabilitation includes initial immobilization with a hip brace for 10 days, with full weight bearing on the operated limb. The progressive gain in the range of motion starts according to pain tolerance, with ambulation without orthosis encouraged until gait normalization in 6 to 8 weeks. The patients are allowed to practice contact sports 6 to 8 months after surgery.

Data Collection

We collected demographic data, such as sex, age, laterality, lesion location, size, follow-up, and associated procedures. The preoperative clinical evaluation used internationally-standardized clinical scores, including the Lysholm, Fulkerson, Kujala, Tegner, International Knee Document Committee (IKDC) scores, and the Visual Analogue Scale (VAS). These scores were applied again after 2 years of outpatient follow-up.

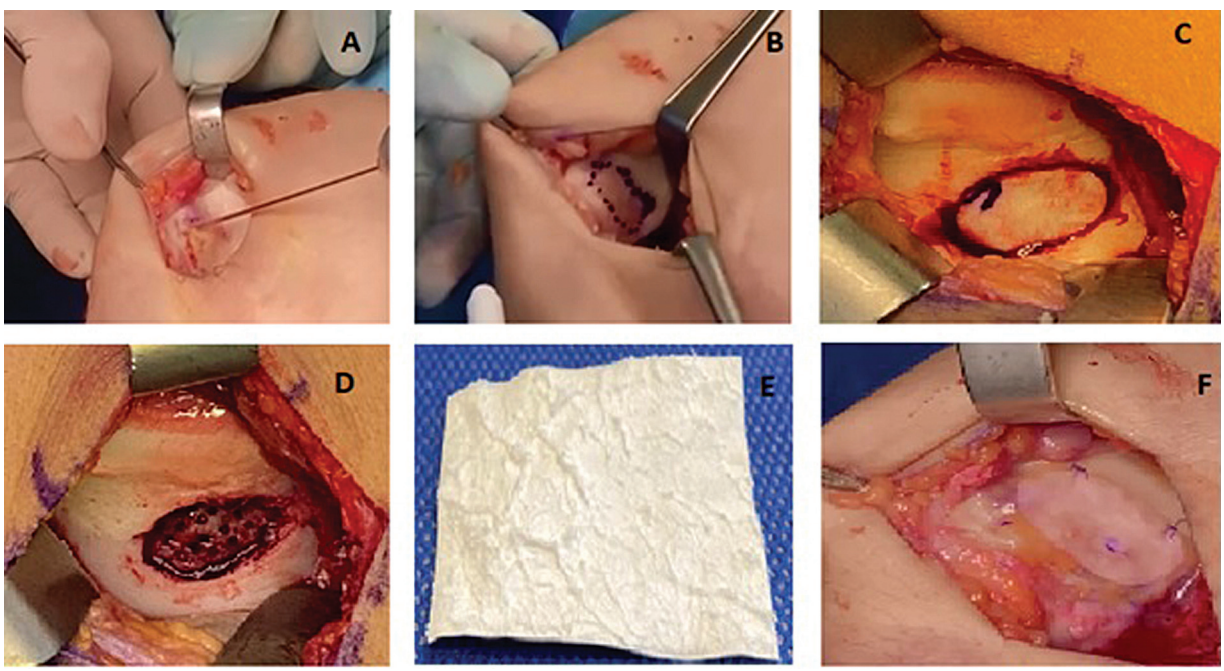

Fig. 1 Clinical image of autologous matrix-induced chondrogenesis (AMIC) in a cartilage lesion. **A**, extensive cartilage defect. **B**, regularization of the lesion edges. **C**, marking of the lesion size after curettage. **D**, subchondral bone nanoperforation. **E**, porcine type I/III collagen membrane. **F**, final appearance of the membrane implant with 5-0 monofilamentous suture reinforced with fibrin glue.

Table 1 Comparison between groups regarding the distribution of qualitative factors

		Patella		Trochlea		Total	
		N	%	N	%	N	%
Side	Right	7	58.3%	5	38.5%	12	48.0%
	Left	5	41.7%	8	61.5%	13	52.0%
Sex	Female	5	41.7%	1	7.7%	6	24.0%
	Male	7	58.3%	12	92.3%	19	76.0%
Site	Lateral	5	41.7%	5	38.5%	10	40.0%
	Medial	4	33.3%	3	23.1%	7	28.0%
	Medial and lateral	3	25.0%	5	38.5%	8	32.0%

Statistical Analysis

Data analysis used the following software: IBM SPSS Statistics for Windows, version 20.0 (IBM Corp.), Minitab 16 (Minitab, LLC), and Excel 2010 (Microsoft Corp.). The analysis of the quantitative variables was performed by calculating means, standard deviations (SDs), and quartiles. For the qualitative variables, absolute and relative frequencies were calculated. Result comparison between groups employed the Wilcoxon, Mann-Whitney, and equality of two proportions tests. Data was shown in tables and boxplots. The level of statistical significance was of 95%, and the *p*-value was set at 0.05.

Table 2 Score comparison per group

			Mean	Median	Standard deviation	N	*p*-value
Lysholm	Patella	Pre	60.1	62.5	± 13.6	12	0.003
		Post	88.3	90.5	± 10.7	12	
	Trochlea	Pre	67.5	63.0	± 13.2	13	0.007
		Post	88.5	89.0	± 13.4	13	
IKDC	Patella	Pre	48.7	46.6	± 14.9	12	0.002
		Post	82.6	89.1	± 13.9	12	
	Trochlea	Pre	53.6	52.9	± 11.5	13	0.003
		Post	84.6	92.0	± 14.5	13	
Tegner	Patella	Pre	3.58	3.00	± 1.62	12	0.017
		Post	4.92	5.50	± 1.31	12	
	Trochlea	Pre	4.46	5.00	± 1.76	13	0.305
		Post	5.31	5.00	± 1.93	13	
Fulkerson	Patella	Pre	56.9	60.5	± 15.0	12	0.002
		Post	88.2	90.0	± 11.6	12	
	Trochlea	Pre	63.3	64.0	± 15.1	13	0.005
		Post	90.3	94.0	± 14.4	13	
VAS	Patella	Pre	5.83	6.50	± 2.48	12	0.005
		Post	1.42	0.50	± 1.93	12	
	Trochlea	Pre	5.38	6.00	± 2.06	13	0.003
		Post	1.08	0.00	± 1.71	13	
Kujala	Patella	Pre	58.3	58.5	± 14.5	12	0.002
		Post	86.4	89.0	± 12.9	12	
	Trochlea	Pre	65.2	70.0	± 14.1	13	0.006
		Post	89.2	91.0	± 12.8	13	

Abbreviations: IKDC, International Knee Documentation Committee; Post, postoperative period; Pre, preoperative period; VAS, Visual Analog Scale.

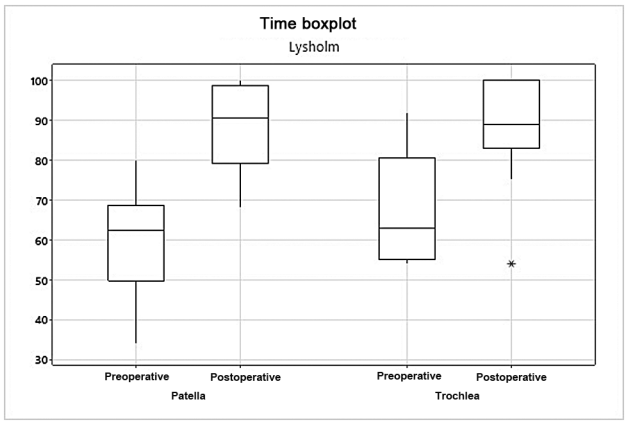

Fig. 2 Analysis of the patella and trochlea groups per the Lysholm score.

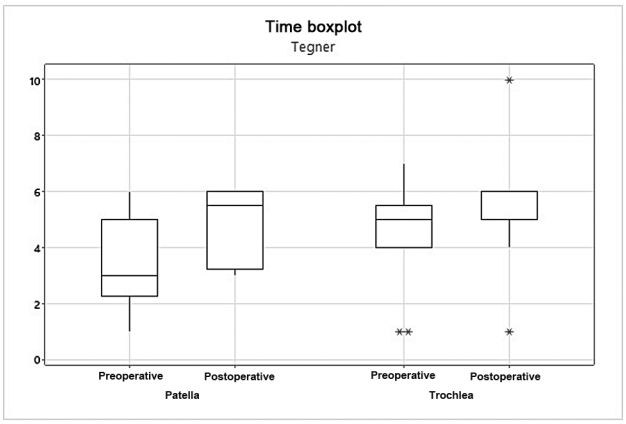

Fig. 4 Analysis of the patella and trochlea groups per the Tegner score.

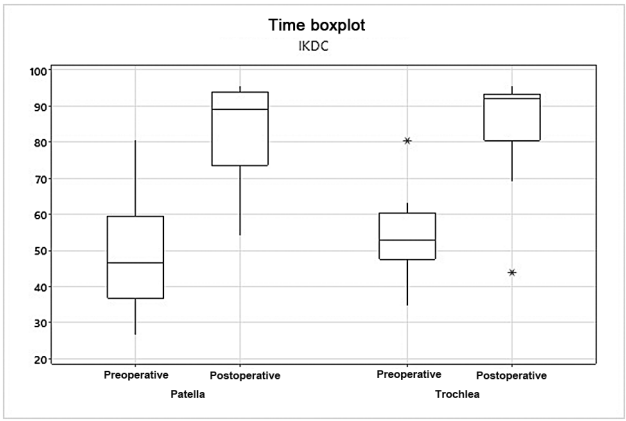

Fig. 3 Analysis of the patella and trochlea groups per the International Knee Documentation Committee (IKDC) score.

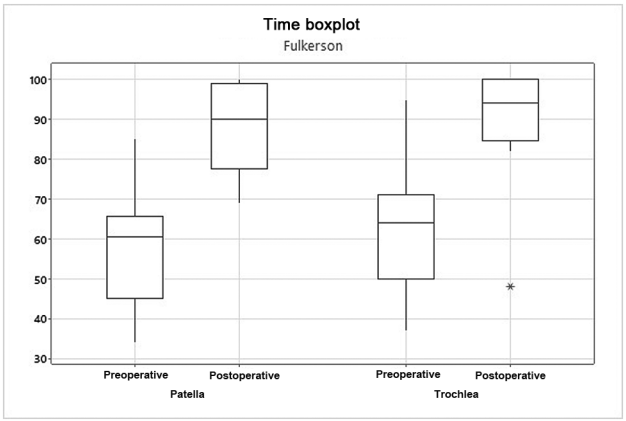

Fig. 5 Analysis of the patella and trochlea groups at per Fulkerson score.

Results

We analyzed 24 patients (25 knees) aged 15 to 60 (mean: 39.6 ± 4.7) years, 5 women and 19 men. The lesions affected the patella in 12 cases and the femoral trochlea in 13 cases, and their sizes ranged from 1.0 cm^2 to 3.99 cm^2 in the patella and from 0.9 cm^2 to 2.94 cm^2 in the trochlea. The mean follow-up was of 3.54 ± 0.65 years. ►**Table 1** shows the frequencies of the lesion site, laterality, and sex.

The evaluation of the Lysholm, Fulkerson, Kujala, Tegner, VAS, and IKDC scores was performed before and after surgery, with a minimum follow-up of 24 months. There was a statistically significant increase in virtually all comparisons, except for the Tegner score for the trochlea group, which presented no statistical significance, even though the mean value increased from 4.46 to 5.31 ($p = 0.305$). ►**Table 2** compares the mean values for the patella and trochlea groups.

The mean Lysholm score increased from 60.1 to 88.3 ($p = 0.003$) in the patella group, and from 67.5 to 88.5 ($p = 0.007$) in the trochlea group (►**Fig. 2**). The mean IKDC score increased from 48.7 to 82.6 ($p = 0.002$) in the patella group, and from 53.6 to 84.6 ($p = 0.003$) in the trochlea group (►**Fig. 3**). The mean Tegner score increased from 3.58 to 4.92 ($p = 0.017$) in the patella group (►**Fig. 4**).

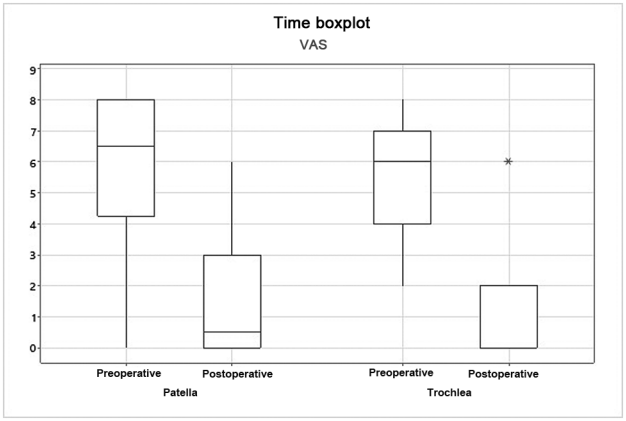

Fig. 6 Analysis of the patella and trochlea groups per the score on the Visual Analog Scale (VAS).

The mean Fulkerson score increased from 56.9 to 88.2 ($p = 0.002$) in the patella group, and from 63.3 to 90.3

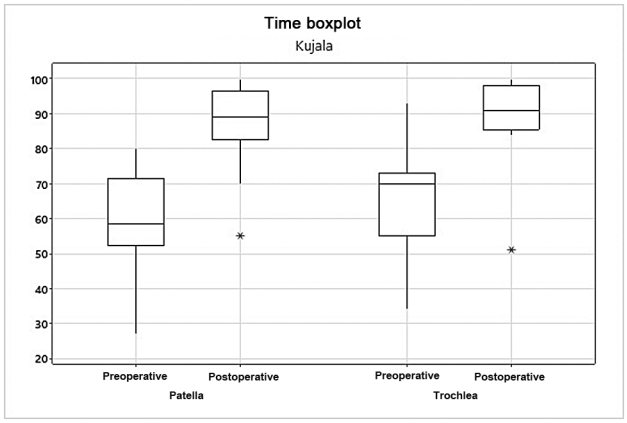

Fig. 7 Analysis of the patella and trochlea groups per the Kujala score.

($p = 0.005$) in the trochlea group (►**Fig. 5**). The mean VAS score decreased from 5.83 to 1.42 ($p = 0.005$) in the patella group, and from 5.38 to 1.08 ($p = 0.003$) in the trochlea group (►**Fig. 6**). Lastly, the mean Kujala score increased from 58.3 to 86.4 ($p = 0.002$) in the patella group, and from 65.2 to 89.2 ($p = 0.006$) in the trochlea group (►**Fig. 7**).

Discussion

The most relevant data from the current study was the efficacy of the AMIC technique to treat full-thickness chondral lesions in the patella and trochlea with a minimum follow-up of 2 years. All scores presented statistically significant clinical and functional improvements, resulting in symptom reduction and sports return at preinjury levels.

Consistent with these findings, Gille et al.[18] conducted a study with a sample of patients with patellofemoral lesions smaller than ours ($n = 11$ versus $n = 25$), but a similar mean age. However, in their study, the patella was predominantly affected (nine versus two), while trochlear lesions were more frequent here (13 versus 12). Likewise, they[18] found improvements in Lysholm scores, which increased from 36 ± 21 preoperatively to 76 ± 24 at the 24-month follow-up. The Tegner and IKDC scores also showed a significant increase in patellar defects during the same analysis period, with these data published in a previous article.[10] Waltenspül et al.[3] observed an elevation in the Kujala score from 63.5 ± 11.6 preoperatively to 72.2 ± 17.4 after a minimum follow-up of 24 months ($p = 0.029$).

Regarding patient satisfaction after AMIC, Panni et al.,[19] after a mean follow-up of 7 years, reported that 76.2% of the patients considered the treatment good or excellent. Gille et al.,[18] when evaluating 27 patients treated with AMIC, found that 87% of them were satisfied with the treatment outcomes. The current analysis confirms these data, revealing positive outcomes, with 84% of patients classifying their satisfaction as good or excellent, a rate consistent with those of the aforementioned literature.

In a 12-month follow-up, Tradati et al.[20] reported significant outcomes in patients undergoing AMIC. The Kujala score increased from 49.6 preoperatively to 87.8 after 12 months ($p < 0.01$). The IKDC score increased from 36.1 to 79.8 ($p < 0.01$). In addition, there was a significant reduction in pain, and the VAS score decreased from 7.5 to 1.5 ($p < 0.01$).[20] The present study reveals that the benefits of the treatment proposed by Tradati et al.[20] are sustained for at least 24 months, since the variations in the scores measured here are symmetrical to those observed by those authors.

The patellofemoral compartment is the most challenging knee region to treat chondral lesions. Hinckel et al.[21] conducted a systematic review to establish which technique is most appropriate in this scenario. They observed that the outcomes of the combination of collagen membrane and autologous chondrocyte implant (ACI) were superior to those of the other techniques. Nevertheless, the AMIC technique was not included in their analysis[21] due to the lack of controlled studies at the time. The use of AMIC is well-established for the condylar region; Astur et al.,[6] for instance, analyzed outcomes similar to those reported here in 15 patients for 12 months, noting a 4-point difference in VAS score at the end of the 12-month follow-up, consistent with our findings after 24 months, even though we dealt with the anterior knee compartment.

A current trend associates the classic AMIC technique herein described with orthobiological agents, preserving the subchondral bone or not. For instance, the AMIC plus technique associates bone marrow aspirate concentrate (BMAC) with the collagen membrane. This combination has shown evidence of postoperative pain relief, functional improvement, and outcome maintenance for up to 3 years.[22] Sciarretta et al.[23] reported promising results using the LIPO-AMIC technique, which combines AMIC with autologous adipose tissue grafting. These authors[23] observed early and progressive improvement, in addition to long-lasting symptom relief; moreover, they noted significant recovery and maintenance of daily functional and sports activities at 2-year and, especially, 5-year follow-ups. Another technique that deserves attention is minced cartilage implantation, which can be applied to small-diameter cartilage defects. This technique can be an alternative to bone marrow stimulation procedures, as minced cartilage implantation can be performed in a single-stage procedure, even using arthroscopic techniques. This minimally-invasive approach is easy to apply and an attractive option to treat focal chondral lesions.[24]

The current study is not free from limitations, many of which are inherent to its design, as it is an observational case series study. First, the number of participants ($n = 25$) may limit statistical robustness, despite being relevant compared with the international literature. Furthermore, the fact that it is a single-arm study and that does not include a control group prevents direct comparison and assessment of the relative efficacy of the interventions. Another limitation is the impossibility of comparing different techniques, such as nanofracture, since control groups are critical for data analysis. The heterogeneity of the lesions among the patients constitutes a significant limitation of the current study, since we included injuries in the trochlea and the patella.

Moreover, we did not consider subtle variations in the anatomical and biomechanical patterns of the patellofemoral region. Another significant limitation is the lack of outcome assessment through imaging. Additionally, a longer follow-up could provide more robust data and enrich the conclusions.

Conclusion

The repair of chondral lesions using collagen membrane is a safe, effective, and viable technique for the treatment of symptomatic full-thickness chondral defects of the patellofemoral cartilage in properly-selected cases, resulting in clinical and functional improvements in all criteria analyzed after 2 years of follow-up.

Informed Consent Form

Consent was waived due to the study design.

Financial Support

The authors declare that they did not receive financial support from agencies in the public, private, or non-profit sectors to conduct the present study.

Conflict of Interests

The authors have no conflict of interests to declare.

References

1 Krishnan Y, Grodzinsky AJ. Cartilage diseases. Matrix Biol 2018; 71-72:51–69. Doi: 10.1016/j.matbio.2018.05.005
2 Carballo CB, Nakagawa Y, Sekiya I, Rodeo SA. Basic Science of Articular Cartilage. Clin Sports Med 2017;36(03):413–425. Doi: 10.1016/j.csm.2017.02.001
3 Waltenspül M, Suter C, Ackermann J, Kühne N, Fucentese SF. Autologous Matrix-Induced Chondrogenesis (AMIC) for Isolated Retropatellar Cartilage Lesions: Outcome after a Follow-Up of Minimum 2 Years. Cartilage 2021;13(1_suppl, suppl)1280S–1290S. Doi: 10.1177/19476035211021908
4 Gomoll AH, Gillogly SD, Cole BJ, Farr J, Arnold R, Hussey K, Minas T. Autologous chondrocyte implantation in the patella: a multicenter experience. Am J Sports Med 2014;42(05):1074–1081. Doi: 10.1177/0363546514523927
5 Flanigan DC, Harris JD, Trinh TQ, Siston RA, Brophy RH. Prevalence of chondral defects in athletes' knees: a systematic review. Med Sci Sports Exerc 2010;42(10):1795–1801. Doi: 10.1249/MSS.0b013e3181d9eea0
6 Astur DC, Lopes JC, Santos MA, Kaleka CC, Amaro JT, Cohen M. Surgical treatment of chondral knee defects using a collagen membrane - autologus matrix-induced chondrogenesis. Rev Bras Ortop 2018;53(06):733–739. Doi: 10.1016/j.rboe.2018.09.005
7 De Girolamo L, Schönhuber H, Viganò M, Bait C, Quaglia A, Thiebat G, Volpi P. Autologous Matrix-Induced Chondrogenesis (AMIC) and AMIC Enhanced by Autologous Concentrated Bone Marrow Aspirate (BMAC) Allow for Stable Clinical and Functional Improvements at up to 9 Years Follow-Up: Results from a Randomized Controlled Study. J Clin Med 2019;8(03):392. Doi: 10.3390/jcm8030392
8 Kim JH, Heo JW, Lee DH. Clinical and Radiological Outcomes After Autologous Matrix-Induced Chondrogenesis Versus Microfracture of the Knee: A Systematic Review and Meta-analysis With a Minimum 2-Year Follow-up. Orthop J Sports Med 2020;8(11):2325967120959280. Doi: 10.1177/2325967120959280
9 Miyahira MKC, Novaretti JV, Astur DC, Kaleka CC, Amaro JT, Cohen M. Larger Chondral Lesions Treated with Collagen Membrane - Matrix-Induced Autologous Chondrogenesis - Show Larger Increase in Clinical Scores. Rev Bras Ortop 2021;56(03):333–339. Doi: 10.1055/s-0040-1712493
10 Gille J, Schuseil E, Wimmer J, Gellissen J, Schulz AP, Behrens P. Mid-term results of Autologous Matrix-Induced Chondrogenesis for treatment of focal cartilage defects in the knee. Knee Surg Sports Traumatol Arthrosc 2010;18(11):1456–1464. Doi: 10.1007/s00167-010-1042-3
11 Sadlik B, Puszkarz M, Kosmalska L, Wiewiorski M. All-Arthroscopic Autologous Matrix-Induced Chondrogenesis-Aided Repair of a Patellar Cartilage Defect Using Dry Arthroscopy and a Retraction System. J Knee Surg 2017;30(09):925–929. Doi: 10.1055/s-0037-1599246
12 Peras M, Caubère A, Choufani C, Passuti N, Versier G, Barbier O. Does AMIC® provide improvements at least two years after surgery for knee osteochondral lesions? A multicentre retrospective study of 101 patients. Orthop Traumatol Surg Res 2024;110(01):103774. Doi: 10.1016/j.otsr.2023.103774
13 Volz M, Schaumburger J, Gellißen J, Grifka J, Anders S. A randomized controlled trial demonstrating sustained benefit of autologous matrix-induced chondrogenesis (AMIC®) over microfracture: 10-year follow-up. Eur J Orthop Surg Traumatol 2024;34(05):2429–2437. Doi: 10.1007/s00590-024-03948-0
14 Kaiser N, Jakob RP, Pagenstert G, Tannast M, Petek D. Stable clinical long term results after AMIC in the aligned knee. Arch Orthop Trauma Surg 2021;141(11):1845–1854. Doi: 10.1007/s00402-020-03564-7
15 Kusano T, Jakob RP, Gautier E, Magnussen RA, Hoogewoud H, Jacobi M. Treatment of isolated chondral and osteochondral defects in the knee by autologous matrix-induced chondrogenesis (AMIC). Knee Surg Sports Traumatol Arthrosc 2012;20(10):2109–2115. Doi: 10.1007/s00167-011-1840-2
16 Steinwachs MR, Gille J, Volz M, Anders S, Jakob R, De Girolamo L, et al. Systematic Review and Meta-Analysis of the Clinical Evidence on the Use of Autologous Matrix-Induced Chondrogenesis in the Knee. Cartilage 2021;13(1_suppl)42S–56S. Doi: 10.1177/1947603519870846
17 Dhollander A, Moens K, Van der Maas J, Verdonk P, Almqvist KF, Victor J. Treatment of patellofemoral cartilage defects in the knee by autologous matrix-induced chondrogenesis (AMIC. Acta Orthop Belg 2014;80(02):251–259
18 Gille J, Behrens P, Volpi P, De Girolamo L, Reiss E, Zoch W, Anders S. Outcome of Autologous Matrix Induced Chondrogenesis (AMIC) in cartilage knee surgery: data of the AMIC Registry. Arch Orthop Trauma Surg 2013;133(01):87–93. Doi: 10.1007/s00402-012-1621-5
19 Panni AS, Del Regno C, Mazzitelli G, D'Apolito R, Corona K, Vasso M. Good clinical results with autologous matrix-induced chondrogenesis (Amic) technique in large knee chondral defects. Knee Surg Sports Traumatol Arthrosc 2018;26(04):1130–1136. Doi: 10.1007/s00167-017-4503-0
20 Tradati D, De Luca P, Maione A, Uboldi FM, Volpi P, De Girolamo L, Berruto M. AMIC-autologous matrix-induced chondrogenesis technique in patellar cartilage defects treatment: A retrospective study with a mid-term follow-up. J Clin Med 2020;9(04):1184. Doi: 10.3390/jcm9041184
21 Hinckel BB, Pratte EL, Baumann CA, Gowd AK, Farr J, Liu JN, et al. Patellofemoral Cartilage Restoration: A Systematic Review and Meta-analysis of Clinical Outcomes. Am J Sports Med 2020;48(07):1756–1772. Doi: 10.1177/0363546519886853
22 Ow ZGW, Ting KJE, Wong KL. Single-Stage Arthroscopic Cartilage Repair With Chondrectomy and Implantation of a Templated

Membrane Collagen Scaffold With Bone Marrow Aspirate Concentrate Augmentation (AMIC Plus). Arthrosc Tech 2023;12(11): e2085–e2091. Doi: 10.1016/j.eats.2023.07.030

23 Sciarretta FV, Ascani C, Sodano L, Fossati C, Campisi S. One-stage cartilage repair using the autologous matrix-induced chondrogenesis combined with simultaneous use of autologous adipose tissue graft and adipose tissue mesenchymal cells technique: clinical results and magnetic resonance imaging evaluation at five-year follow-up. Int Orthop 2024;48(01):267–277. Doi: 10.1007/s00264-023-05921-8

24 Salzmann GM, Ossendorff R, Gilat R, Cole BJ. Autologous Minced Cartilage Implantation for Treatment of Chondral and Osteochondral Lesions in the Knee Joint: An Overview. Cartilage 2021;13 (1_suppl)1124S–1136S. Doi: 10.1177/1947603520942952