Article published online: 2025-04-28



# Transiliac-transsacral Screws: What is the Required Implant Length for Adequate Percutaneous Fixation of the Posterior Pelvic Ring?

## *Parafusos transilíaco-transacrais: Qual o comprimento necessário dos implantes para uma adequada fixação percutânea do anel pélvico posterior?*

Leonardo Comerlatto[1] Natália Henz Concatto[2] Marcus Vinícius Crestani[1] Tauã Brum Silva[2] Carlos Roberto Galia[1] Marco Aurélio Telöken[1]

[1] Orthopedics and Traumatology Service, Hospital Moinhos de Vento, Porto Alegre, RS, Brazil
[2] Radiology Service, Hospital Moinhos de Vento, Porto Alegre, RS, Brazil

**Address for correspondence** Leonardo Comerlatto, MD, Serviço de Ortopedia e Traumatologia, Hospital Moinhos de Vento, Rua Ramiro Barcelos, 910, primeiro pavimento, bloco A, 90035-000, Porto Alegre, RS, Brazil (e-mail: comerlatto.quadril@gmail.com).

Rev Bras Ortop 2025;60(1):s00441800947.

**Abstract**

**Objective** Brazilian orthopedic surgeons experience the unavailability of long screws allowing percutaneous fixation of the posterior pelvic ring in transiliac-transsacral (TI-TS) configuration. The objective of the present study is to measure the lenght of the osseous fixation pathways available for TI-TS fixation in a population sample to infer the required implant length.

**Methods** We retrospectively assessed patients undergoing computed tomography (CT), initially identifying the existence of a potential osseous fixation pathway (POFP) in S1, S2 and S3. Each POFP was measured from the external cortex of the iliac bone to the external cortex of the contralateral iliac bone on axial CT images.

**Results** The analysis comprised a sample of 180 cases. A POFP was identified in S1 in 116 (64.4%) cases, in S2 in 178 (98.9%) cases, and in S3 in 16 (8.9%) cases. The median (interquartile range – IQR) POFP measurement in S1 was 153 (148–161) mm, ranging from 135 mm to 179 mm. In S2, the median (IQR) POFP measurement was 136 (131–144) mm, ranging from 114 to 160 mm. In S3, the median (IQR) POFP measurement was 120.5 (115–126) mm, ranging from 110 to 131 mm.

**Conclusions** We demonstrated that the maximum lengths of the osseous fixation pathways identified in our sample would require screws up to 180 mm in length, with a clear dissociation between the values measured and the longer screws currently commercialized in our setting.

**Keywords**
- bone screws
- fracture fixation, internal
- fractures, bone
- pelvic bones

*Work carried out at the Orthopedics and Traumatology Service, Hospital Moinhos de Vento, Porto Alegre, Brazil.*

**received**
June 21, 2024
**accepted**
October 2, 2024

**DOI** https://doi.org/10.1055/s-0044-1800947.
**ISSN** 0102-3616.

© 2025. The Author(s).
This is an open access article published by Thieme under the terms of the Creative Commons Attribution 4.0 International License, permitting copying and reproduction so long as the original work is given appropriate credit (https://creativecommons.org/licenses/by/4.0/).

Thieme Revinter Publicações Ltda., Rua do Matoso 170, Rio de Janeiro, RJ, CEP 20270-135, Brazil

## Resumo

**Objetivo** Cirurgiões ortopédicos brasileiros vivenciam a indisponibilidade de parafusos longos que permitam a fixação percutânea do anel pélvico posterior na configuração transilíaco-transacral (TI-TS). O objetivo do presente estudo é mensurar o comprimento dos corredores ósseos de fixação disponíveis para fixação TI-TS em uma amostra populacional para inferir o comprimento necessário do implante.

**Métodos** Foram avaliados retrospectivamente pacientes que realizaram tomografia computadorizada (TC), identificando inicialmente a existência de um potencial corredor ósseo de fixação (PCOF) em S1, S2 e S3. Cada PCOF foi medido a partir da cortical externa de um ilíaco até a cortical externa do ilíaco contralateral em imagens axiais de TC.

**Resultado** A análise compreendeu uma amostra de 180 casos. PCOF em S1 foi identificado em 116 (64,4%) casos, PCOF em S2 foi identificado em 178 (98,9%) casos e PCOF em S3 foi identificado em 16 (8,9%) casos. A mediana (intervalo interquartílico - IIQ) da aferição do PCOF de S1 foi de 153 (148–161) mm, variando de 135 a 179 mm. Em S2, a mediana (IIQ) foi de 136 (131–144) mm, com uma variação de 114 a 160 mm. Em S3, a mediana (IIQ) da medição do PCOF foi de 120,5 (115–126) mm, com uma variação de 110 a 131 mm.

**Conclusões** Demonstramos que os comprimentos máximos dos corredores ósseos de fixação identificados exigiriam parafusos de até 180 mm de comprimento, com uma clara dissociação entre os valores medidos e os parafusos mais longos atualmente comercializados em nosso meio.



**Palavras-chave**

- fixação interna de fraturas
- fraturas ósseas
- ossos pélvicos
- parafusos ósseos


## Introduction

From its first descriptions,[1,2] percutaneous fixation of traumatic posterior pelvic ring injuries using cannulated screws has been established as a safe, reproducible, effective, and versatile method, which can be used to treat a wide variety of fractures, dislocations, and fracture-dislocations affecting the posterior ilium, sacroiliac joint, and sacrum.[3–5] Current indications include more unstable injury patterns[4,6] and subjects with poor bone quality.[7,8] The method requires extensive knowledge of the anatomy, neurovascular structures at risk, and the osseous fixation pathways (OFP) available in each patient.[8] Sacral dysmorphism recognition is essential and guides the fixation strategy.[9]

Depending on individual features and the purpose of implant use, implants can be positioned in the iliosacral (IS) or transiliac-transsacral (TI-TS) configuration. Screws in the traditional IS configuration are inserted from the iliac bone external cortex towards the sacral vertebral body. This configuration has proven insufficient, especially in situations of major instability, comminution, and osteoporosis.[10,11] The TI-TS configuration, i.e the insertion of a screw crossing the sacral segment and reaching the external cortex of the contralateral iliac bone, became possible only after the production of longer implants in the early 2000s.[12] Since then, a better understanding of OFPs and bone density-related particularities of the posterior ring have demonstrated clinical and biomechanical advantages of using screws in the TI-TS configuration.[13–15]

Brazilian orthopedic surgeons experience the unavailability of cannulated screws with lengths that allow implant application in TI-TS configuration, preventing optimal OFP use and, in many cases, compromising the ability to offer sufficiently rigid and stable fixation.

The main objective of the present study was to perform the tomographic measurement of the length of OFPs used in the TI-TS fixation in a population sample.

## Materials and Methods

After obtaining Intitucional Review Board approval (CAAE: 78038724.5.0000.5330), we assessed retrospectively patients admitted in the emergency department between January 2nd and 10th, 2024, using the picture archiving and communication system (PACS) version 12 (Philips Medical Systems Nederland B.V., Best, The Netherlands) available at the institution.

Patients aged between 18 and 85 years who were evaluated in the hospital emergency department and underwent computed tomography (CT) of the abdomen/pelvis with serial axial images of up to 2 mm were included. Patients with traumatic injuries (acute or chronic) or malignancy-related anatomical deformities were excluded.

The presence of a potential osseous fixation pathway (POFP) for a safe insertion of a TI-TS screw in the first (S1), second (S2), and third (S3) sacral segments was inittialy evaluated on axial CT images. The presence of POFP in S1 was defined by the existence of a wide bone corridor allowing for a safe insertion of a TI-TS screw according to previously described criteria;[16] these patients have been considered non-dysmorphic (►**Figure 1A**). According to the same criteria, the presence of sacral dysmorphism is represented by the

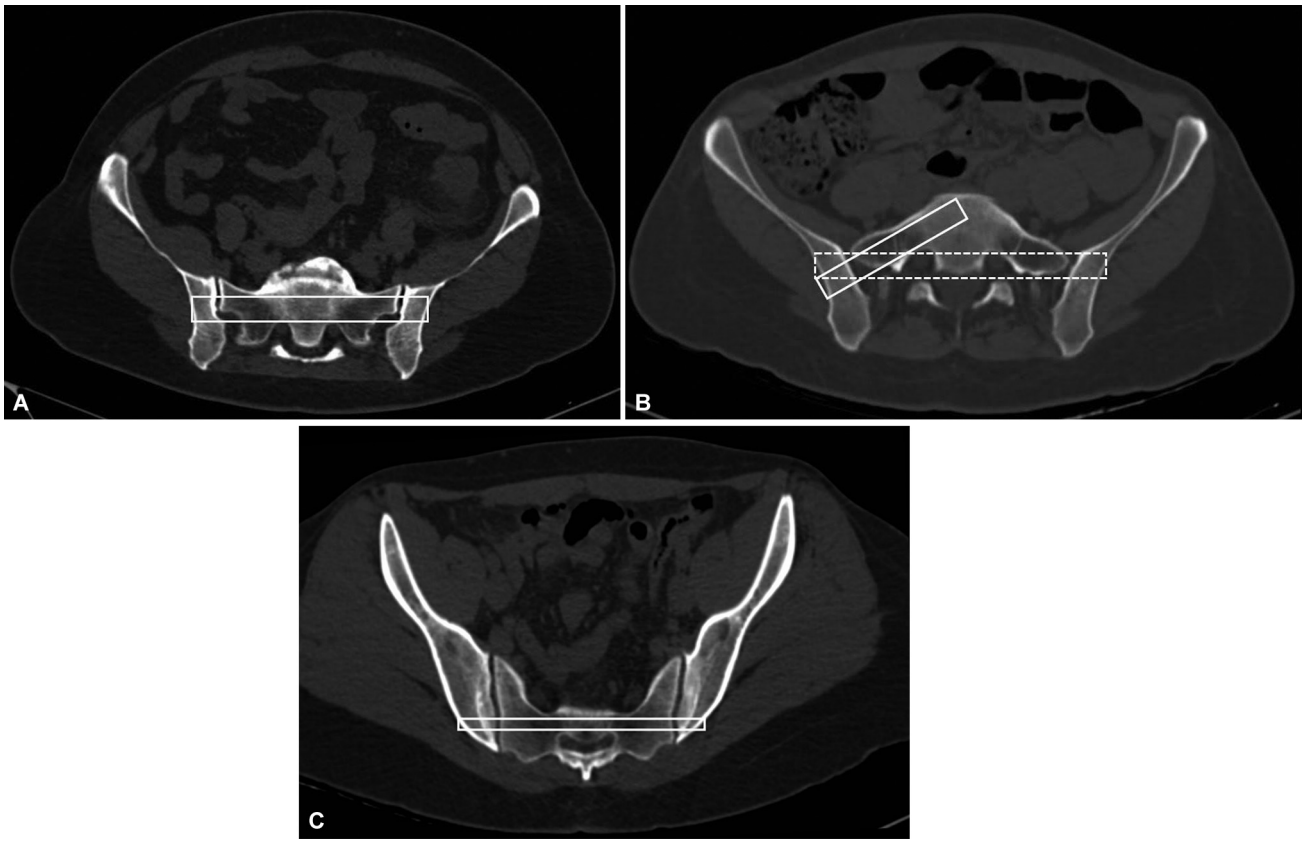


**Fig. 1** Definition of a transiliac-transsacral (TI-TS) potential osseous fixation pathway (POFP) in S1 and S3. (A) Presence of TI-TS POFP in S1 (absence of sacral dysmorphism). (B) The absence of TI-TS POFP in S1 (presence of sacral dysmorphism), with a narrow and oblique OFP at this level, only allows for implant application in the iliosacral (IS) configuration. (C) Patient with a TI-TS POFP in S3 presenting a bilateral complete articulation between the caudal portion of the iliac bone and the third sacral vertebra.

absence of a POFP in S1 that would allow the application of a TI-TS screw (►**Figure 1B**). Only patients with a complete bilateral articulation between the caudal portion of the ilium and the third sacral vertebra were considered to have a POFP in S3 according to previous definition[17] (►**Figure 1C**). POFPs identified in S1, S2, and S3 were measured (in millimeters *[mm]*) from the external cortex of the posterior iliac bone to the external cortex of the contralateral posterior iliac to infer the minimum TI-TS configuration implant length (►**Figure 2**). The same evaluator (an orthopedic surgeon experienced in treating pelvic ring injuries) performed the measurements using the tool provided by the software.

All sample size calculations used the WinPEPI program (Programs for Epidemiologists for Windows) version 11.65 (Jerusalem, Israel) based on data from a pilot survey analyzing 20 patients and referring to subjects from both genders and the presence of PBCFs at each level. Considering the quantitative data for S1, the standard deviation for men (8.81) and women (7.10), an 80% analysis power, a 5% significance level, and a 10% potential loss margin, the minimum sample size required to detect a difference of five units between the groups was 63 participants from each gender, totaling 126 subjects.

Data processing, double entry into the database, review, and analysis used IBM SPSS Statistics for Windows (IBM Corp., version 21.0, Armonk, NY, USA) software. Descriptive analyses expressed quantitative data as mean ± standard deviation of the mean (± SD) or median and interquartile range (IQR) ($25^{th}$–$75^{th}$ percentiles) per the Shapiro-Wilk distribution test. Qualitative variables were described as absolute frequencies (n) and relative frequencies (%). The Chi-squared ($\chi 2$) test with adjusted residual analysis assessed potential associations between qualitative variables. The Student's t-test for independent samples (t) compared means (± SD), and the Mann-Whitney (MW) test compared medians (IQR). For all analyses, the significance level was set at 5%.

## Results

The analysis comprised a sample of 180 patients admitted to the emergency department who underwent abdominal/pelvic CT between January 2nd and 10th, 2024. The sample had 115 women (63.9%) and 65 men (36.1%). The median (IQR) age was 43.5 years (34–62), ranging from 19 to 82. Of the total 180 cases included in the analysis, we identified a POFP in S1 in 116 (64.4%) cases, a POFP in S2 in 178 (98.9%) cases, and a POFP in S3 in 16 (8.9%) cases.

►**Table 1** shows the presence of POFP at each sacral level evaluated. We noted the absence of POFP at S1, i.e, the presence of sacral dysmorphism, in 64 (35.5%) of the 180 patients evaluated.

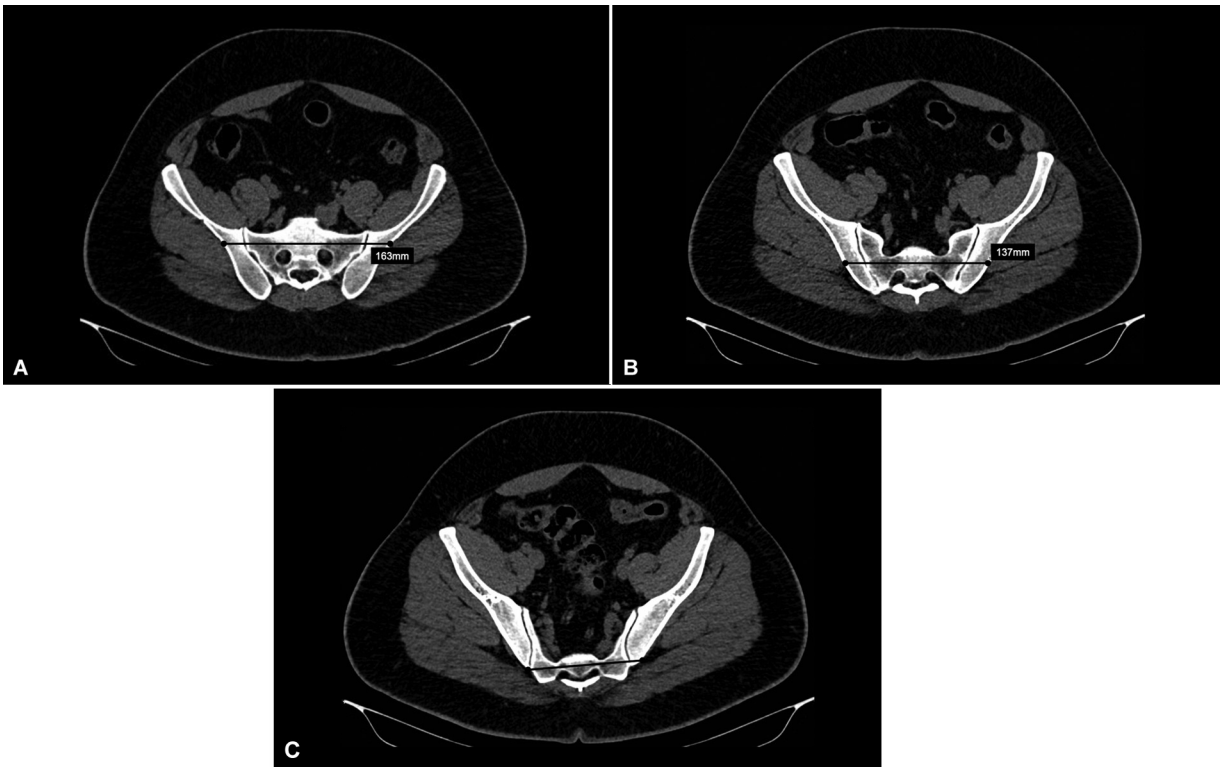


**Fig. 2** Technique for measuring the length of the potential osseous fixation pathway (POFP) in each patient. The patient has POFP in the first (A) and second (B) sacral segments, with lengths of 163 mm and 137 mm, respectively. There is no POFP in the third sacral segment (C).

**Table 1** Presence of a potential osseous fixation pathway at each sacral level evaluated

| Sacral level | Total presence of POFP ($N = 180$) |
|---|---|
| S1 | 116 (64.4) |
| S2 | 178 (98.9) |
| S3 | 16 (8.9) |

Abbreviation: POFP, patients with a potential osseous fixation pathway.
Note: Data presented as absolute (n) and relative (%) frequencies.

►**Table 2** shows the length of each POFP in millimeters (mm) for each sacral level. The median [IQR] of the POFP at S1 was 153 (148–161) mm, ranging from 135 mm to 179 mm. At S2, the median (IQR) was 136 (131–144) mm, ranging from 114 to 160 mm. At S3, the median (IQR) POFP was 120.5 (115–126) mm, ranging from 110 to 131 mm.

►**Table 3** presents the differences between patients with and without sacral dysmorphism. Among those without sacral dysmorphism ($N = 116$), the mean (± SD) of POFP length in S2 was 135.68 ± 8.54 mm, while, in those with sacral dysmorphism ($N = 64$), the mean (± SD) POFP length in S2 was slightly higher, of 139.50 (± 9.30) mm (t, $p = 0.006$). There was a significant contrast between groups regarding the presence of POFP at S3. Among patients with sacral dysmorphism, 21.9% presented a POFP at S3, whereas only 1.7% of those without sacral dysmorphism did so ($\chi^2$, $p \leq 0.001$).

**Table 2** Lenght of the potencial osseous fixation pathways at each sacral level evaluated

| Sacral level | | POFP measurement (mm) ($N = 180$) |
|---|---|---|
| S1[a] | (minimum–maximum) | 153 [148–160] (135–179) |
| S2[b] | (minimum–maximum) | 137.05 ± 8.98 (114–160) |
| S3[c] | (minimum–maximum) | 121.81 ± 6.92 (111–131) |

Abbreviations: mm, millimeter; POFP, patients with a potential osseous fixation pathway.
Notes: Data presented as mean ± SD, median (IQR], minimum and maximum.
[a]$n = 116$ (64.4%).
[b]$n = 178$ (98.9%).
[c]$n = 16$ (8.9%).

►**Table 4** shows gender-related differences for each POFP at each sacral level evaluated. In S1, women exhibited a mean (± SD) length of 151.64 (± 9.19) mm, whereas men showed a mean (± SD) length of 157.14 (± 9.70) mm (t, $p = 0.003$). In S2, there was no significant difference between genders, with women presenting a mean (± SD) length of 137.21 (± 9.00) mm and men, 136.77 (± 9.01) mm (t, $p = 0.752$). In S3, although not statistically significant (MW, $p = 0.055$), there was a trend towards a difference, with women presenting a

**Table 3** Differences between patients without and with sacral dysmorphism

| | Without sacral dysmorphism (N = 116) | With sacral dysmorphism (N = 64) | *p-value |
|---|---|---|---|
| S2 measurement[a] | 135.68 ± 8.54 | 139.50 ± 9.30 | 0.006 |
| PCOF present in S3 | 2 (1.7) | 14 (21.9) | ≤ 0.001 |

Notes: Data presented as mean ± SD, absolute frequencies (n), and relative frequencies (%). Abbreviation: p – statistical significance index.
*Student's t-test for independent samples or Chi-squared test for adjusted residual analysis. Significance was set at 5% for all analyses.
[a]with sacral dysmorphism, *n* = 64 (100.0%); without sacral dysmorphism, *n* = 116 (98.3%).

**Table 4** Measurement of the potential osseous fixation pathways at each sacral level according to gender

| Sacral level | POFP measurement in females (*N* = 115) | POFP measurement in males (*N* = 65) | *p-value |
|---|---|---|---|
| S1 | 151.64 ± 9.19 | 157.14 ± 9.70 | 0.003 |
| S2 | 137.21 ± 9.00 | 136.77 ± 9.01 | 0.752 |
| S3 | 130 [121.5–130.5] | 119 [116–123] | 0.055 |

Abbreviations: *p*-value, statistical significance level; PBCF, patients with a potential osseous fixation pathway.
Notes: *Student's t-test for independent samples or Mann-Whitney test (MW).
Data presented as mean ± SD, or median (IQR).
Significance was set at 5% for all analyses.

**Table 5** Patients with a potential osseous fixation pathways in S3

| Variable | | POFP in S3 (*n* = 16) |
|---|---|---|
| Gender | Female<br>Male | 7 (43.8)<br>9 (56.3) |
| Sacral dysmorphism | Yes<br>No | 14 (87.5)<br>2 (12.5) |

Abbreviation: PBCF, patients with a potential bone corridor for fixation.
Note: Data presented as absolute (n) and relative (%) frequencies.

median (IQR) POFP length of 130 (121.5–130.5) mm and men 119 (116–123) mm.

►**Table 5** presents data on patients with POFP in S3. We identified 16 (8.9%) cases of POFP in S3, including 7 women (43.8%) and 9 men (56.3%). In addition, we noted morphology consistent with sacral dysmorphism in 14 cases (87.5%) and 2 cases (12.5%) had no sacral dysmorphism.

## Discussion

Screws in TI-TS configuration offer better fixation than in the IS configuration, and their insertion is preferred whenever possible according to the OFPs available in each patient.[13–16] Biomechanical studies comparing different posterior pelvic ring injuries fixation methods favor the use of TI-TS screws;[18–23] however, their use depends on the availability of implants of sufficient length. Long screws provide better load distribution, reducing stress at the tip of the implant and preventing secondary displacement.[12] TI-TS screws have higher pullout resistance,[15] allowing anchorage of up to six cortices; moreover, their higher lever arm increases shear resistance.[17] In addition to the absolute measurement of the implant length, fully threaded long screws may offer the possibility of anchoring the highest number of threads, contributing to their effectiveness in maintaining posterior ring stability.[12] Furthermore, the insertion of two TI-TS screws at the same sacral level has been described and is advantageous as long as it is carefully planned according to the published technique.[24]

Recognition of sacral dysmorphism has fundamental practical implications for planning and executing percutaneous posterior ring fixation. Sacral dysmorphism is characterized by several radiographic peculiarities, such as noncircular sacral foramina and an acute alar slope.[25] However, in a more practical approach and with wider clinical applicability, a binary delineation is currently performed regarding the presence or absence of sacral dysmorphism.[13,16] The patient is defined as dysmorphic whenever the first sacral segment allows an intraosseous screw in the IS configuration but does not allow the safe intraosseous application of a TI-TS screw. In dysmorphic patients, the first sacral segment has a smaller and more obliquely oriented safe zone, allowing only the insertion of short screws in an oblique direction. In these subjects, S2 has a safety zone with a transverse orientation and a larger area[26,27] compared to the same segment in nondysmorphic patients. The identification of sacral dysmorphism in 35.5% (64/180) of the patients analyzed is compatible with previously published data and, in this group, the impossibility of TI-TS fixation in S1 due to the lack of a safe OFP increases the significance of using S2 OFP.

Studies have shown that S3 may be a viable and safe option for TI-TS fixation in approximately 15% of patients, with dysmorphic patients being more likely to have a OFP at this level.[17,28] Our sample demonstrated the existence of POFP at S3 in only 16/180 (8.9%) cases and corroborated that most of these patients (87.5%) have a morphology consistent with sacral dysmorphism. When advanced intraoperative imaging techniques are available,[29,30] S3 offers an additional fixation site when a more stable construct is required.

Although previously described, the insertion of TI-TS screws in S3 is compromised by the unavailability of a viable OFP in most of the population and the small number of studies defining its safety and indications. Furthermore, due to the high technical demand and precision required, as well as the structures at risk, percutaneous placement of screws in S3 presupposes the use of advanced intraoperative imaging techniques (such as three-dimensional fluoroscopy), which are rarely available in our setting.

Posterior pelvic ring percutaneous fixation requires a complete set of fully and partially threaded cannulated screws.[2] Although it is possible to apply implants with diameters ranging from 6.5 to 7.3 mm, 7.0-mm implants are the most widely available and studied. The production and commercialization of longer implants allowing TI-TS fixation occurred in major international centers only from the first decade of the 21st century onwards.[12]

Few scientific studies about this topic provide data specifically on screw lengths. Before the existence of longer screws and the popularization of the TI-TS fixation concept, Routt et al.[2] stated that screws up to 140 mm in length would be necessary to reach the contralateral sacral asa. In a study on percutaneous stabilization of "U"-shaped sacral fractures, Nork et al.[4] reported using screws of up to 150 mm. In a specific publication on TI-TS fixation, Gardner et al.[12] used implants of lengths ranging from 160 to 180 mm for S1 fixation and from 120 to 160 mm for S2 fixation.

To the authors' knowledge, in the Brazilian federation unit where this study occurred, the longest 7.0-mm cannulated screws currently on the market are 150-mm long (partially threaded only). In the same federation unit, the most significant orthopedic trauma public institutions, which account for managing most patients with pelvic fractures, provided, at the time of this study, only partially threaded implants with a maximum length of 120 mm. We believe this reality extends to the rest of the country. Considering minimum and maximum lengths of S1 and S2 POFPs identified in our sample (from 135–179 mm for S1 and 114–160 mm for S2), we noticed the unavailability of implants allowing TI-TS fixation in most patients. In our practice, we have exceptionally identified patients with small dimensions allowing TI-TS fixation in S2. In the case presented ►**Figures 3**–**7** (images from author's archive), preoperative planning indicated no sacral dysmorphism, with a wide OFP in S1, measuring 141 mm, and representing a length higher than the longer implant offered by the institution at that time. On the other hand, S2 OFP measured 118 mm, which allowed for planning and safe insertion of a 120 mm TI-TS screw without a washer.

Limitations of this study include the fact that planning TI-TS screw requires additional sagittal plane evaluation.[16]




**Fig. 3** Case example (preoperative radiographs). Anteroposterior (AP) (A), inlet (B), and outlet (C) radiographs of a female patient presenting a mechanically unstable pelvic ring injury, including a complete and nondisplaced sacral fracture on the right side, incomplete injury of the left sacroiliac joint, and a pubic symphysis injury.

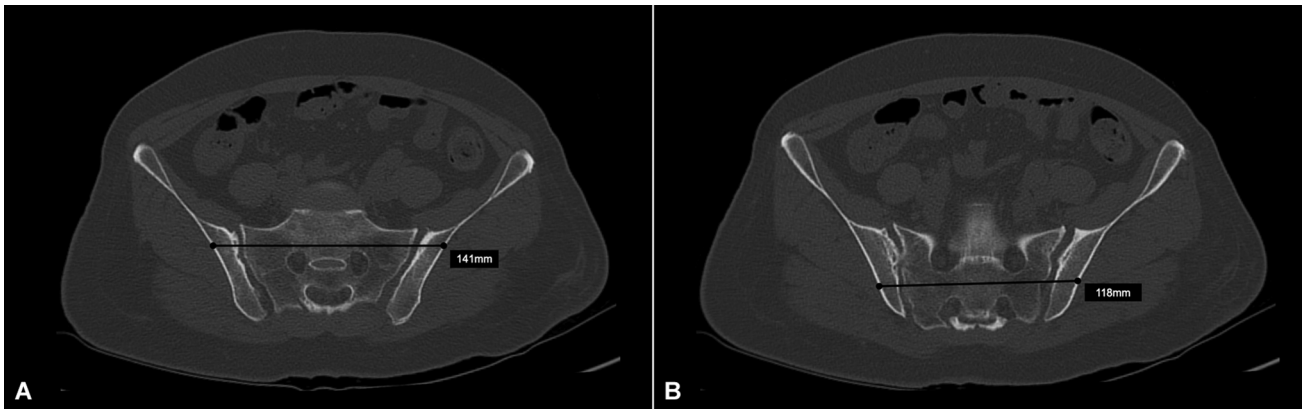


**Fig. 4** Case example (preoperative planning). Axial computed tomography scans demonstrating the measurement of the length of the bone corridors for fixation in the first (A) and second (B) sacral segments during preoperative planning.

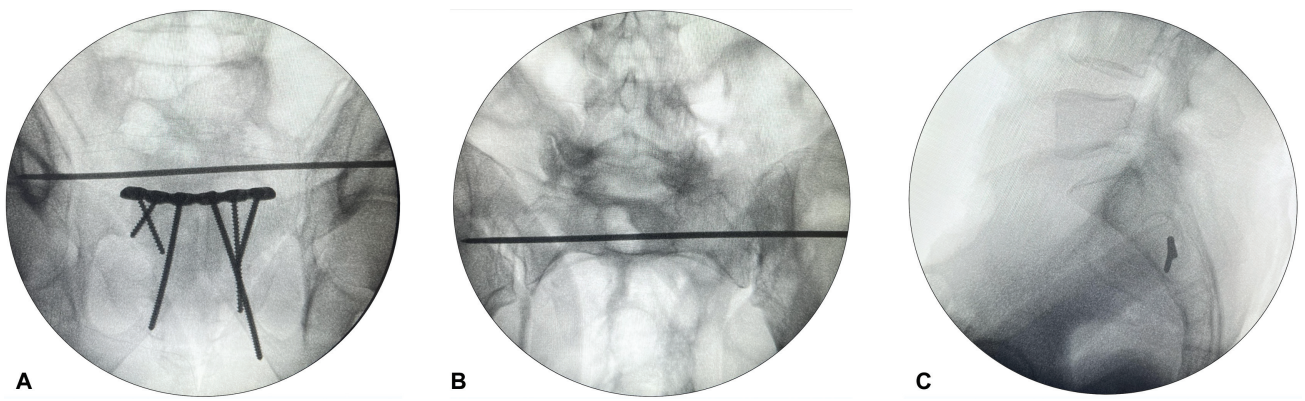


**Fig. 5** Case example (intraoperative images). Fluoroscopic (A) outlet, (B) inlet, and (C) lateral views of the sacrum acquired intraoperatively.

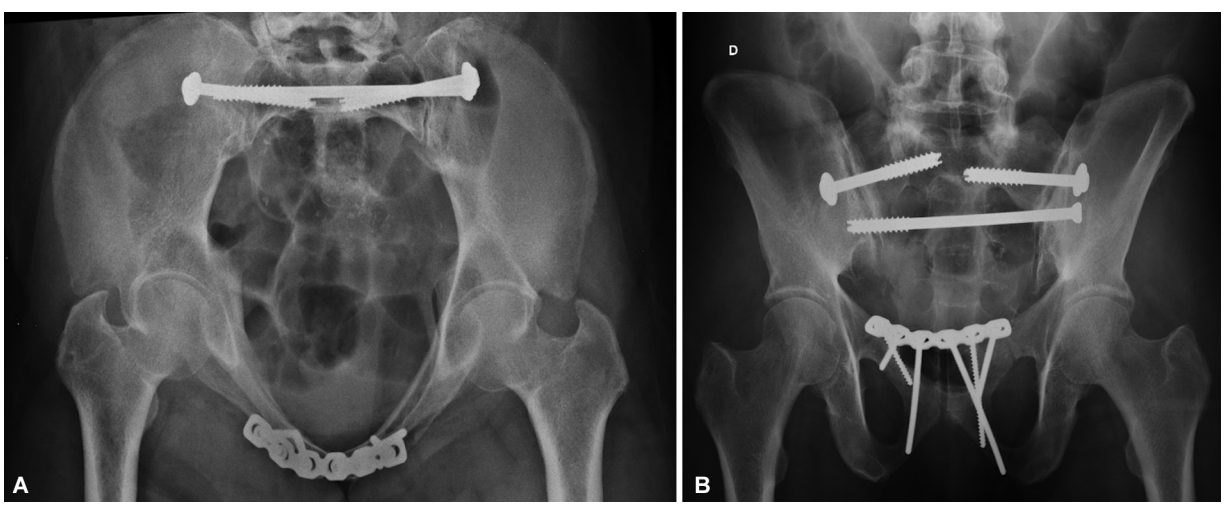


**Fig. 6** Case example (postoperative radiographs). Postoperative images in inlet (A) and outlet (B) views demonstrating the iliosacral fixation in S1 bilaterally and transiliac-transsacral fixation in S2.

The proposed measurement (between the external cortices of the posterior iliac as a way of determining the implant length) occurred in axial images alone and, therefore, we preferred the term "potential" OFP. It is worth mentioning that the measurement technique used in this study does not consider that, conceptually, an implant should exceed one or two threads the opposite cortex. In addition, there is a preference for using washers, which would increase the real implant length in a clinical situation by around 2 or 3 mm.

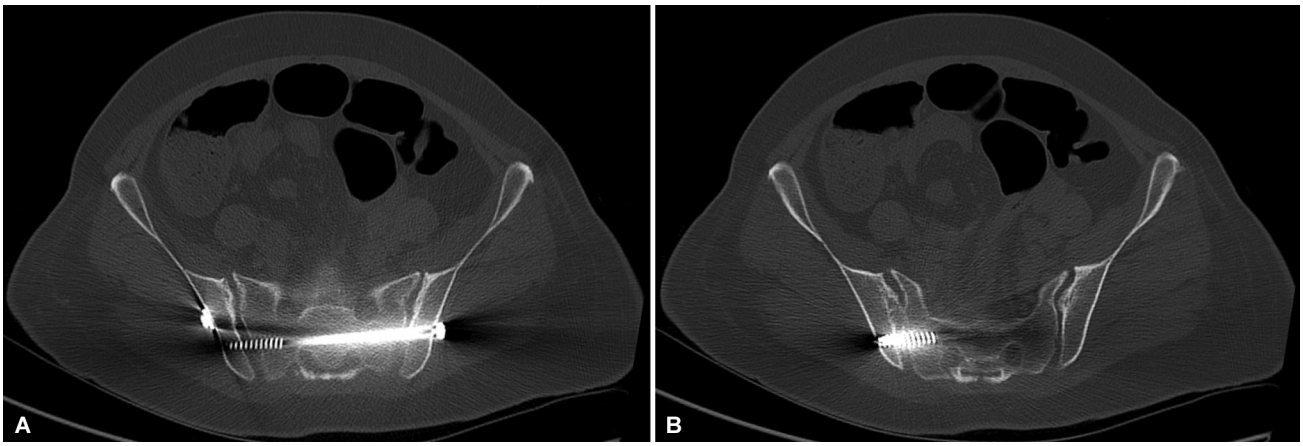


**Fig. 7** Case example (postoperative computed tomography [CT] scans). CT images demonstrating the safe and intraosseous positioning of the previously planned implant in S2.

## Conclusion

Percutaneous posterior pelvic ring fixation is a traditional, well-established method widely validated by clinical and biomechanical studies. From a historical perspective, it is clear that the production of longer implants for screw application in TI-TS configuration allowed the method to establish itself as the main method of treatment for traumatic injuries affecting the posterior iliac, sacroiliac joint, and sacrum.

In our sample, we demonstrated that the OFP lenghts are dissociated from the longer screws currently commercialized in our country, and an adequate percutaneous posterior pelvic ring fixation requires a complete set of cannulated screws with lengths of up to 180 mm.

Financial Support
The authors declare that they did not receive financial support from agencies in the public, private, or non-profit sectors to conduct the present study.

Conflict of Interests
The authors have no conflict of interests to declare.

## References

1 Matta JM, Saucedo T. Internal fixation of pelvic ring fractures. Clin Orthop Relat Res 1989;(242):83–97
2 Routt ML, Meier MC, Kregor PJ, Mayo KA. Percutaneous iliosacral screws with the patient supine technique. Oper Tech Orthop 1993;3(01):35–45
3 Routt ML Jr, Kregor PJ, Simonian PT, Mayo KA. Early results of percutaneous iliosacral screws placed with the patient in the supine position. J Orthop Trauma 1995;9(03):207–214
4 Nork SE, Jones CB, Harding SP, Mirza SK, Routt ML Jr. Percutaneous stabilization of U-shaped sacral fractures using iliosacral screws: technique and early results. J Orthop Trauma 2001;15(04): 238–246
5 Calafi LA, Routt ML Jr. Posterior iliac crescent fracture-dislocation: what morphological variations are amenable to iliosacral screw fixation? Injury 2013;44(02):194–198
6 Saiz AM Jr, Kellam PJ, Amin A, et al. Percutaneous sacral screw fixation alone sufficient for mildly displaced U-type sacral fractures with preserved osseous fixation pathways. Eur J Orthop Surg Traumatol 2023. Doi: 10.1007/s00590-023-03661-4
7 Cintean R, Fritzsche C, Zderic I, Gueorguiev-Rüegg B, Gebhard F, Schütze K. Sacroiliac versus transiliac-transsacral screw osteosynthesis in osteoporotic pelvic fractures: a biomechanical comparison. Eur J Trauma Emerg Surg 2023;49(06):2553–2560
8 Bishop JA, Routt ML Jr. Osseous fixation pathways in pelvic and acetabular fracture surgery: osteology, radiology, and clinical applications. J Trauma Acute Care Surg 2012;72(06):1502–1509
9 Kaiser SP, Gardner MJ, Liu J, Routt ML Jr, Morshed S. Anatomic Determinants of Sacral Dysmorphism and Implications for Safe Iliosacral Screw Placement. J Bone Joint Surg Am 2014;96(14): e120
10 Tabaie SA, Bledsoe JG, Moed BR. Biomechanical comparison of standard iliosacral screw fixation to transsacral locked screw fixation in a type C zone II pelvic fracture model. J Orthop Trauma 2013;27(09):521–526
11 Salazar D, Lannon S, Pasternak O, et al. Investigation of bone quality of the first and second sacral segments amongst trauma patients: concerns about iliosacral screw fixation. J Orthop Traumatol 2015;16(04):301–308
12 Gardner MJ, Routt ML Jr. Transiliac-transsacral screws for posterior pelvic stabilization. J Orthop Trauma 2011;25(06):378–384
13 Eastman JG, Shelton TJ, Routt MLC Jr, Adams MR. Posterior pelvic ring bone density with implications for percutaneous screw fixation. Eur J Orthop Surg Traumatol 2021;31(02):383–389
14 Beaulé PE, Antoniades J, Matta JM. Trans-sacral fixation for failed posterior fixation of the pelvic ring. Arch Orthop Trauma Surg 2006;126(01):49–52
15 Chang G, Fram B, Sobol K, Krieg JC. Two Transiliac-Transsacral Screws in a Single Sacral Level: Surgical Technique and Patient Outcomes. Tech Orthop 2021;36(01):50
16 Lucas JF, Routt ML Jr, Eastman JG. A Useful Preoperative Planning Technique for Transiliac-Transsacral Screws. J Orthop Trauma 2017;31(01):e25–e31
17 Eastman JG, Adams MR, Frisoli K, Chip Routt ML Jr. Is S3 a Viable Osseous Fixation Pathway? J Orthop Trauma 2018;32(02):93–99
18 Zhao Y, Zhang S, Sun T, et al. Mechanical comparison between lengthened and short sacroiliac screws in sacral fracture fixation: a finite element analysis. Orthop Traumatol Surg Res 2013;99 (05):601–606
19 Min KS, Zamorano DP, Wahba GM, Garcia I, Bhatia N, Lee TQ. Comparison of two-transsacral-screw fixation versus triangular

osteosynthesis for transforaminal sacral fractures. Orthopedics 2014;37(09):e754–e760
20 Chen PH, Chen CY, Lin KC, Hsu CJ. Quantification of the Safe Zone of the First to Third Sacral Segments for Transiliac-Transsacral Screw Fixation in Normal and Dysmorphic Sacra. Orthopedics 2024;47(01):e13–e18
21 Jazini E, Klocke N, Tannous O, et al. Does Lumbopelvic Fixation Add Stability? A Cadaveric Biomechanical Analysis of an Unstable Pelvic Fracture Model. J Orthop Trauma 2017;31(01): 37–46
22 Gonçalves RM, Freitas A, Aragão VAD, et al. Comparison of sacroiliac screw techniques for unstable sacroiliac joint disruptions: a finite element model analysis. Injury 2023;54(Suppl 6): 110783
23 Collinge CA, Crist BD. Combined Percutaneous Iliosacral Screw Fixation With Sacroplasty Using Resorbable Calcium Phosphate Cement for Osteoporotic Pelvic Fractures Requiring Surgery. J Orthop Trauma 2016;30(06):e217–e222
24 Schultz BJ, Mayer RM, Phelps KD, et al. Assessment of sacral osseous fixation pathways for same-level dual transiliac-transsacral screw insertion. Arch Orthop Trauma Surg 2023;143(10): 6049–6056
25 Miller AN, Routt ML Jr. Variations in sacral morphology and implications for iliosacral screw fixation. J Am Acad Orthop Surg 2012;20(01):8–16
26 Gardner MJ, Morshed S, Nork SE, Ricci WM, Chip Routt ML Jr. Quantification of the upper and second sacral segment safe zones in normal and dysmorphic sacra. J Orthop Trauma 2010;24(10): 622–629
27 Conflitti JM, Graves ML, Chip Routt ML Jr. Radiographic quantification and analysis of dysmorphic upper sacral osseous anatomy and associated iliosacral screw insertions. J Orthop Trauma 2010; 24(10):630–636
28 Hwang JS, Reilly MC, Shaath MK, et al. Safe Zone Quantification of the Third Sacral Segment in Normal and Dysmorphic Sacra. J Orthop Trauma 2018;32(04):178–182
29 Shaw J, Gary J, Ambrose C, Routt MC. Multidimensional pelvic fluoroscopy: A new and novel technique for assessing safety and accuracy of percutaneous iliosacral screw fixation. J Orthop Trauma 2020;34(11):572–577
30 Warner SJ, Haase DR, Chip Routt ML, Eastman JG, Achor TS. Use of 3D Fluoroscopy to Assist in the Reduction and Fixation of Pelvic and Acetabular Fractures: A Safety and Quality Case Series. J Orthop Trauma 2023;37(11S):S1–S6