Pectoralis Major Rupture in a 15-year-old Teenager: Case Report

Ruptura do peitoral maior em adolescente de 15 anos: Relato de caso

Paulo César Faiad Piluski[1] João Artur Bonadiman[1,2] Eduardo Necher Moreira[1] Carlos Humberto Castillo Rodriguez[1] Osvandré Lech[1]

[1] Instituto de Ortopedia e Traumatologia/Hospital São Vicente de Paulo, Passo Fundo, RS, Brazil
[2] Instituto Brasil de Tecnologias da Saúde, Rio de Janeiro, RJ, Brazil

Address for correspondence João Artur Bonadiman, MD, Rua Uruguai 2050, 99010-112, Passo Fundo, Rio Grande do Sul, Brazil (e-mail: joaoartur10@gmail.com).

Rev Bras Ortop 2024;59(S2):e199–e202.

Abstract

Rupture of the pectoralis major muscle is extremely rare in adolescents. The current literature contains only 5 reports of this condition in patients under 20 years old, with 2 reports in subjects under 16. In the present article, we report the case of a 15-year-old volleyball player who suffered a traumatic rupture of the pectoralis major in a match during the serve movement. After excluding endocrinological abnormalities as a cause of tendon weakening, the patient underwent surgical treatment due to muscle retraction, strength deficit, high demand, and esthetic concerns. Early diagnosis is crucial to successful outcomes, and the surgical intervention enabled early rehabilitation and a provided a higher likelihood of return to high-level competitive sports.

Keywords
- pectoralis muscles
- shoulder/surgery
- sports medicine
- tendon injuries

Resumo

A ruptura do músculo peitoral maior é extremamente rara em adolescentes. Na literatura atual, existem apenas 5 relatos em pacientes com menos de 20 anos, sendo 2 em pacientes com menos de 16 anos de idade. Neste artigo, relatamos o caso de uma jogadora de vôlei de 15 anos que sofreu uma ruptura traumática do peitoral maior em uma partida durante o movimento de saque. Após a exclusão de causas endocrinológicas – que poderiam ter provocado o enfraquecimento tendíneo –, o tratamento cirúrgico foi escolhido devido à retração muscular, ao déficit de força, à alta demanda e às preocupações estéticas. O diagnóstico precoce é crucial para que se obtenham bons resultados, e a intervenção cirúrgica propiciou a reabilitação precoce e uma maior probabilidade de retorno ao esporte de competição em alto nível.

Palavras-chave
- lesões dos tendões
- medicina esportiva
- músculos peitorais
- ombro/cirurgia

Work carried out at the Hospital São Vicente de Paulo/Instituto de Ortopedia e Traumatologia, Passo Fundo, RS, Brazil.

received
May 17, 2023
accepted
September 19, 2023

DOI https://doi.org/10.1055/s-0044-1785448.
ISSN 0102-3616.

© 2024. The Author(s).
This is an open access article published by Thieme under the terms of the Creative Commons Attribution 4.0 International License, permitting copying and reproduction so long as the original work is given appropriate credit (https://creativecommons.org/licenses/by/4.0/).

Thieme Revinter Publicações Ltda., Rua do Matoso 170, Rio de Janeiro, RJ, CEP 20270-135, Brazil

Introduction

Rupture of the pectoralis major muscle is an uncommon injury that occurs| more frequently in adults between 20 and 40 years old.[1] The main causes of pectoralis major muscle rupture include weight lifting (particularly bench press), followed by trauma resulting from football, water skiing, wrestling, and ice hockey.[2] Although this injury predominantly affects male individuals, women have been gradually increasing their participation in these predisposing sports.[3,4] Furthermore, this condition is considered extremely rare in adolescents, an age group with higher elasticity, in whom the muscles are still developing, and muscle strength is often lower than in adults.[5] As far as we know, the literature has only two reports[6,7] of pectoralis rupture in patients aged 16 or younger.

Despite its clinical relevance, virtually all studies on this injury focus on adults, which further highlights the rarity of this condition in female adolescents and the need for more research in this field. The objective of the present article is to review the literature currently available on rupture of the pectoralis major in adolescents, as well as to report a case of a 15-year-old female patient, a volleyball player at a high-demand school competitive level who suffered a traumatic rupture of the pectoralis major during a volleyball game and underwent surgical treatment.

Case Report

The institutional Review Board approved the present case report. The patient's legal guardian signed the informed consent form.

A 15-year-old female patient with no history of illness presented with a clinical picture of abrupt pain in the right pectoral region after executing a serve movement during a volleyball game 7 days ago. The physical examination revealed ecchymosis in the area corresponding to the right pectoral region and a palpable gap close to the axillary midline. The passive range of motion was preserved, with painful complaints at the end of the adduction and internal rotation movements of the right upper limb. The strength of adduction and internal rotation of the right upper limb was of grade 3, with sustained strength in other movements. The patient presented no neurological deficits. According to the Risser scale, the degree of skeletal maturation was stage 5. Regarding the development of secondary sexual characteristics, the patient was in Turner stages M3 and P4, with menarche occurring 1 year before.

Standard radiographs showed no changes. Next, magnetic resonance imaging (MRI) revealed extensive rupture in the distal myotendinous transition in the pectoralis major, mainly affecting the sternal portion, with signs of distal stump retraction (►**Fig. 1**).

After explaining the therapeutic options to the patient and her parents, surgical treatment was chosen and performed eight days after the first visit. During the operation, pectoralis major rupture was evident, with retraction of the sternal belly, and only a few fibers remaining in the native attachment (►**Fig. 2A**). After adequate exposure, we inserted a 5.5-mm Twinfix (Smith & Nephew, Watford, Hertfordshire, United Kingdom) titanium metal anchor double loaded with Ultrabraid wires (Smith & Nephew) into the footprint of the pectoralis major tendon, next to the medial surface of the humerus (►**Fig. 2B**), and the repair was performed with Krakow sutures on the distal stump of the pectoralis major, which brought the tendon close to the footprint, restoring physiological tension and length (►**Fig. 2C**). After two weeks of immobilization with a sling, a follow-up radiograph revealed the position of the anchor (►**Fig. 3**), and the patient started pendulum exercises and physical therapy for passive

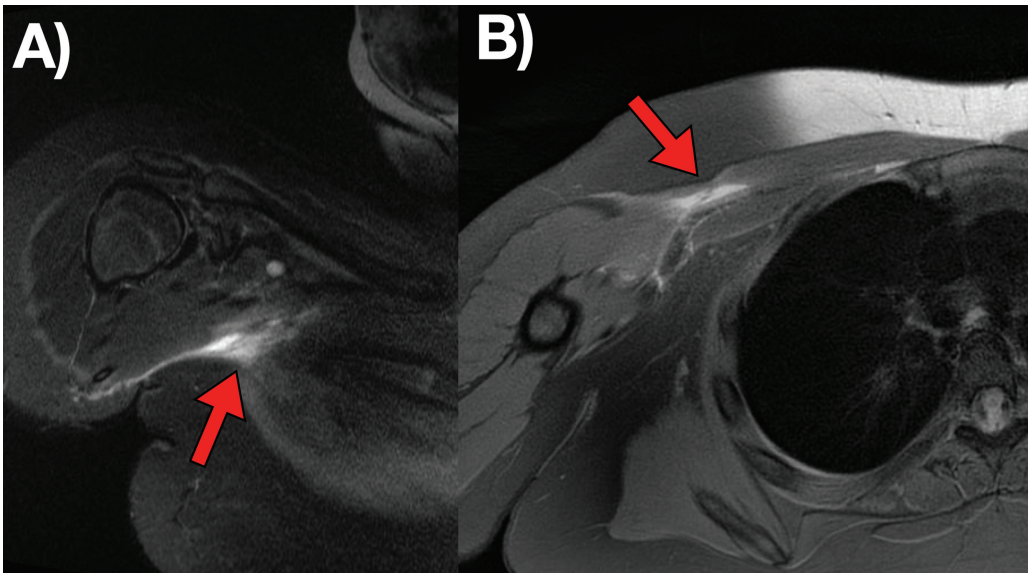

Fig. 1 T2-weighted magnetic resonance imaging scans showing rupture of the pectoralis major muscle in the axial (**A**) and oblique coronal (**B**) sections, with details of retraction (red arrow).

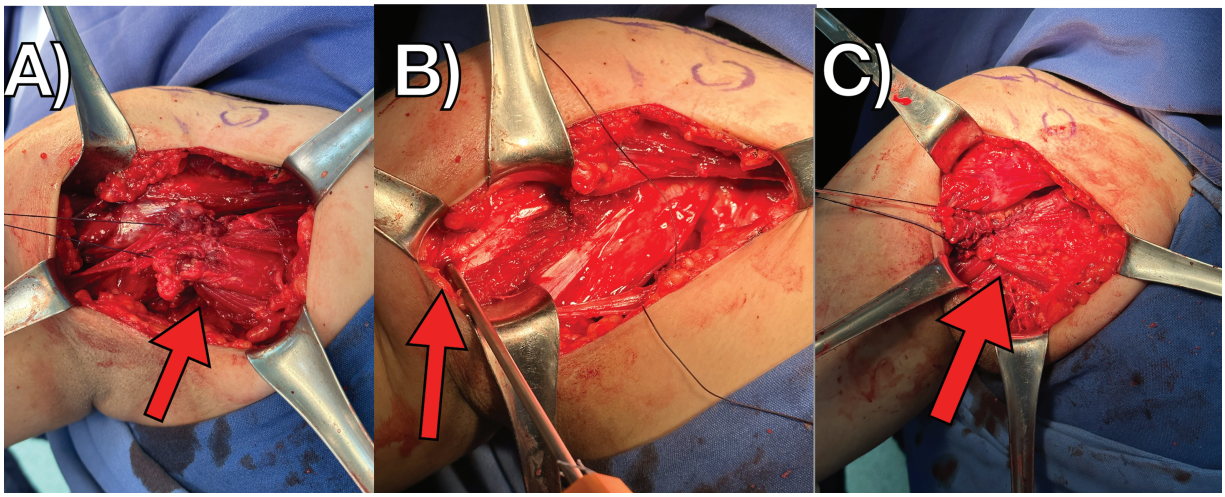

Fig. 2 Intraoperative images showing injury to the pectoralis major tendon with retraction (**A**), insertion of a metal anchor next to the footprint of the pectoralis major (**B**), and the final appearance after reattachment (**C**).

mobility. Six weeks after surgery, the patient stopped using the sling, and physical therapy progressed to active mobility exercises. Gradual muscle-strengthening exercises started after ten weeks. At that moment, laboratory tests investigated the levels of thyroid-stimulating hormone (THS), free thyroxine (T4), triiodothyronine (T3), follicle-stimulating hormone (FSH), luteinizing hormone (LH), progesterone, prolactin, estradiol, and antidiuretic hormone (ADH), which were within normal limits. We requested these tests to exclude any endocrinological abnormalities that could justify the occurrence of this uncommon lesion regarding the patient's profile and age range, since certain endocrinological conditions, such as hyperthyroidism, hypogonadism, and hyperparathyroidism, may result in myotendinous lesions.[8] After 15 weeks, the patient returned for reevaluation; she was asymptomatic, presenting good muscle contour, complete range of motion, grade-4 strength for adduction and internal rotation, and grade-5 for other movements (clinically assessed by the examiner), and an American Shoulder and Elbow Surgeons (ASES) score of 90 (it was of 28 before surgery) (►**Fig. 4**). We advised the patient to progress with gym activities and return to volleyball after completing 20 weeks of surgery. Six months after the procedure, the patient returned for a final follow-up visit, asymptomatic, with physiological muscle contour, and a complete return to volleyball activities, with no limitations and an ASES score of 94.

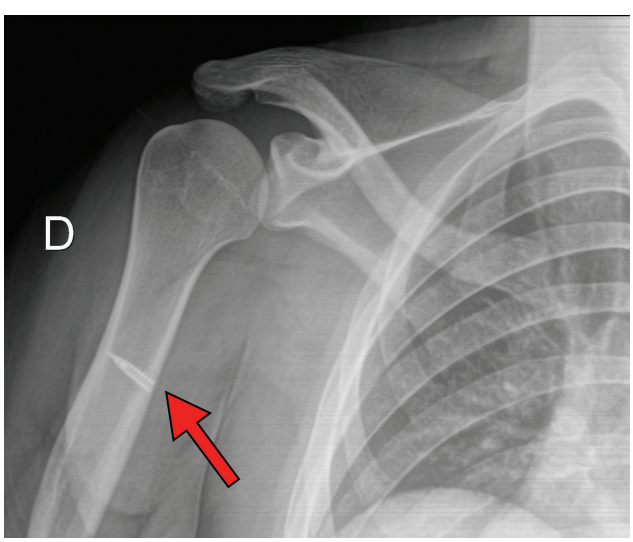

Fig. 3 Follow-up radiograph of the position of the metallic anchor (red arrow).

Discussion

Rupture of the muscle of the pectoralis major tendon is extremely rare in this patient's age group. Pochini et al.[9] studied 27 patients with pectoralis major rupture; the average age was 29.9 years old, with the youngest subject being 21 years old.[9] In another study by the same group of authors,[10] with a sample of 60 cases, the youngest patient was also 21 years old. In the systematic review of 365 cases by ElMaraghy and Deveraux,[11] the average age was of approximately 31 years, with a standard deviation of 9.9 years. Moreover, this study[11] revealed that, out of the 365 cases analyzed, only 11 occurred in women. The systematic review by Yu et al.[12] included 536 cases of pectoralis major rupture; the mean age was of 28 ± 3 years, and there was only one female subject. These data highlight the rarity of this condition in adolescent and female patients. There are only 5 reports[6,7,13–15] in the literature with patients under 20 with this type of injury. Virtually in all cases, the patients practiced some sport, such as tennis,[6] wrestling,[7] judo,[13] and softball.[15] In the case herein reported, the 15-year-old teenager played volleyball at a school competition level. It is worth mentioning that, according to Reeser et al.,[16] 63% of volleyball players present some degree of shortening of the pectoral muscles. This factor may have contributed to the injury in question, since laboratory tests ruled out endocrinological changes.

The option for surgical treatment was based on the high-demand activity of the patient, the retraction associated with

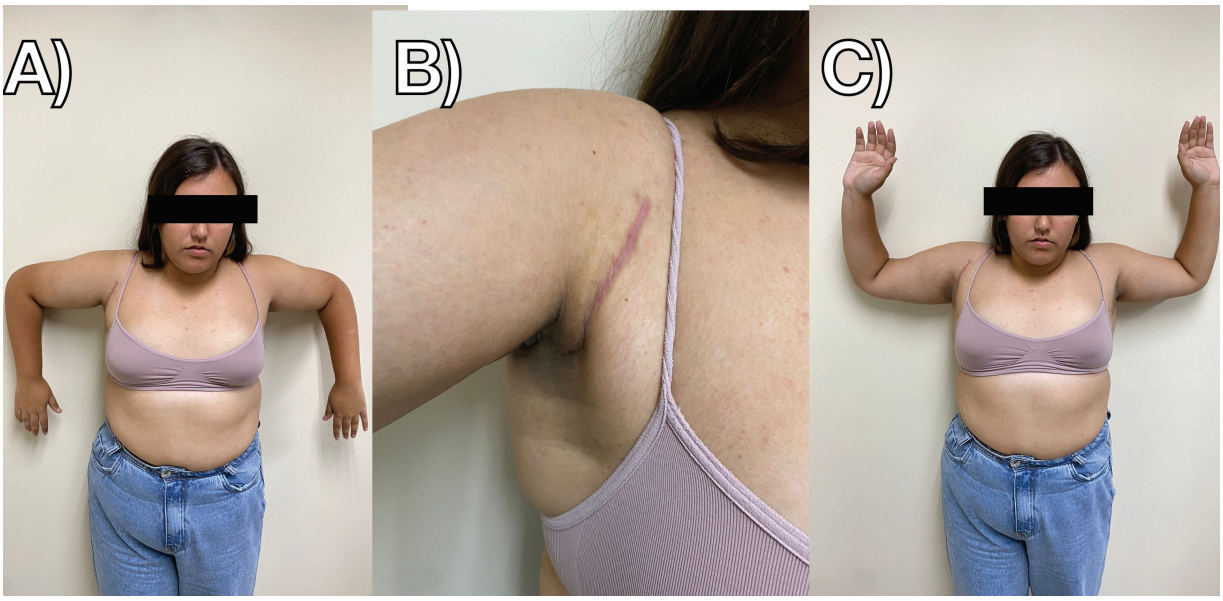

Fig. 4 Postoperative clinical follow-up after 15 weeks. (**A**) Internal rotation. (**B**) Surgical scar. (**C**) External rotation.

strength deficit, and cosmetic concerns. Several studies advocate that surgical intervention improves strength and cosmesis, in addition to enabling the athlete to return to preinjury levels.[2,9,10,13] Early detection of this injury is essential to obtain good outcomes and high satisfaction levels.[10,17]

The present article aimed to report a rare case of rupture of the pectoralis major muscle in an adolescent (an unusual age group for this condition), an injury whose incidence has increased in recent years. Due to the rarity of this condition, it is crucial to always suspect it for an accurate and timely diagnosis. Early diagnosis can enable rapid surgical intervention aiming at early rehabilitation and greater predictability of return to sport, as demonstrated in our patient. We hope future investigations will address appropriate treatments for adolescent athletes along with conditions and mechanisms to prevent this injury.

Financial Support
The authors declare that there was no financial support from public, commercial,or non-profit sources.

Conflict of Interests
The authors have no conflict of interests to declare.

References

1 Kowalczuk M, Elmaraghy A. Pectoralis Major Rupture: Evaluation and Management. J Am Acad Orthop Surg 2022;30(07):e617–e627
2 Petilon J, Carr DR, Sekiya JK, Unger DV. Pectoralis major muscle injuries: evaluation and management. J Am Acad Orthop Surg 2005;13(01):59–68
3 Haley CA, Zacchilli MA. Pectoralis major injuries: evaluation and treatment. Clin Sports Med 2014;33(04):739–756
4 Hanna CM, Glenny AB, Stanley SN, Caughey MA. Pectoralis major tears: comparison of surgical and conservative treatment. Br J Sports Med 2001;35(03):202–206
5 DeFroda S, McGlone P, Levins J, O'Donnell R, Cruz AI, Kriz PK. Shoulder and Elbow Injuries in the Adolescent Throwing Athlete. R I Med J (2013) 2020;103(07):21–29
6 Esser S, Arnold SL, Yellin J, Bryant D. "My Chest Hurts": Pectoralis Major Tear in a 15-Year-Old Tennis Athlete. Curr Sports Med Rep 2022;21(10):351–354
7 Pitts RT, Garner HW, Ortiguera CJ. Pectoralis major avulsion in a skeletally immature wrestler: a case report. Am J Sports Med 2010;38(05):1034–1037
8 Lioté F, Orcel P. Osteoarticular disorders of endocrine origin. Best Pract Res Clin Rheumatol 2000;14(02):251–276
9 Pochini AC, Rodrigues MSB, Yamashita L, Belangero PS, Andreoli CV, Ejnisman B. Surgical treatment of pectoralis major muscle rupture with adjustable cortical button. Rev Bras Ortop 2017;53 (01):60–66
10 de Castro Pochini A, Andreoli CV, Belangero PS, et al. Clinical considerations for the surgical treatment of pectoralis major muscle ruptures based on 60 cases: a prospective study and literature review. Am J Sports Med 2014;42(01):95–102
11 ElMaraghy AW, Devereaux MW. A systematic review and comprehensive classification of pectoralis major tears. J Shoulder Elbow Surg 2012;21(03):412–422
12 Yu J, Zhang C, Horner N, et al. Outcomes and return to sport after pectoralis major tendon repair: A systematic review. Sports Health 2019;11(02):134–141
13 Shepard NP, Westrick RB, Owens BD, Johnson MR. Bony avulsion injury of the pectoralis major in a 19 year-old male judo athlete: a case report. Int J Sports Phys Ther 2013;8(06):862–870
14 Simonian PT, Morris ME. Pectoralis tendon avulsion in the skeletally immature. Am J Orthop 1996;25(08):563–564
15 Kuechly HA, Figueras JH, Figueras J, et al. Pectoralis Major Muscle Belly Rupture in a 17-Year-Old Female Softball Player: A Case Report. JBJS Case Connect 2023;13(01):. Doi: 10.2106/JBJS.CC.22.00592
16 Reeser JC, Joy EA, Porucznik CA, Berg RL, Colliver EB, Willick SE. Risk factors for volleyball-related shoulder pain and dysfunction. PM R 2010;2(01):27–36
17 de Castro Pochini A, Ejnisman B, Andreoli CV, et al. Pectoralis major muscle rupture in athletes: a prospective study. Am J Sports Med 2010;38(01):92–98