Long-term Outcomes 18 Years after the Arthroscopic Fixation of a Scapular Articular Fracture: A Case Report

Resultados a longo prazo após 18 anos de fixação artroscópica de fratura articular da escápula: Relato de caso

Carlos Henrique Ramos[1] Rafaella Monteiro Barbosa[2] Yasmin Netto Costa Gomes[3] Ana Luisa Garcia de Paula[4] Laysla Danyela Coradin Gulicz[1]

[1] Hospital de Clínicas, Universidade Federal do Paraná, Curitiba, PR, Brazil
[2] Faculdade Pequeno Príncipe, Curitiba, PR, Brazil
[3] Faculdade Evangélica Mackenzie do Paraná, Curitiba, PR, Brazil
[4] Residency in Orthopedics and Traumatology, Hospital XV, Curitiba, PR, Brazil

Address for correspondence Carlos Henrique Ramos, Médico Ortopedista e Traumatologista do Hospital de Clínicas da Universidade Federal do Paraná, Curitiba, Paraná, Brazil (e-mail: chramos5673@gmail.com; carlos.ramos@hc.ufpr.br).

Rev Bras Ortop 2024;59(S2):e194–e198.

Abstract

Reduction and fixation of glenoid cavity fractures using arthroscopy cause little surgical trauma, allowing the complementary diagnosis and treatment of potentially associated injuries (either capsular, ligamentous or tendon lesions) with promising outcomes. The authors report a case of Ideberg type III glenoid fracture with a distal clavicle fracture which underwent percutaneous reduction and bone fixation (with Kirschner wires) using an arthroscopic technique. We describe the procedure and the outcomes after 18 years of follow-up. The clinical assessment included the functional University of California at Los Angeles (UCLA) score criteria and radiographic studies. The result was excellent/satisfactory, with the patient asymptomatic over time and without relevant radiographic changes. Although the management of glenoid fractures by arthroscopy remains evolving, it is a good treatment alternative to the open approach, especially in less complex fractures.

Keywords

- arthroscopy
- fracture fixation
- glenoid cavity
- scapula
- shoulder fractures

Resumo

A redução e fixação das fraturas articulares da cavidade glenoidal pela técnica artroscópica causam pouco trauma cirúrgico, possibilitando o diagnóstico complementar e tratamento de eventuais lesões associadas (capsulares, ligamentares e/ou tendinosas), sendo demonstrados resultados promissores até o momento. Os autores relatam um caso de fratura glenoidal tipo III de Ideberg, associada à fratura da clavícula distal, submetida a redução e fixação óssea percutânea (fios de K) assistida pela técnica

Work carried out at the Hospital XV, Curitiba, PR, Brazil.

received
July 4, 2023
accepted
September 19, 2023

DOI https://doi.org/10.1055/s-0044-1790595.
ISSN 0102-3616.

© 2024. The Author(s).
This is an open access article published by Thieme under the terms of the Creative Commons Attribution 4.0 International License, permitting copying and reproduction so long as the original work is given appropriate credit (https://creativecommons.org/licenses/by/4.0/).

Thieme Revinter Publicações Ltda., Rua do Matoso 170, Rio de Janeiro, RJ, CEP 20270-135, Brazil

Palavras-chave
- artroscopia
- cavidade glenoide
- escápula
- fixação de fratura
- fraturas do ombro

artroscópica. Descrevem a técnica e o resultado após 18 anos de acompanhamento, com a avaliação clínica realizada segundo critérios funcionais do *score* University of California at Los Angeles (UCLA) e o estudo radiográfico. O resultado foi considerado excelente/satisfatório, com paciente assintomático ao longo do tempo e ausência de alterações radiográficas relevantes. Apesar do manejo de fraturas da glenoide pela artroscopia ainda estar em evolução, apresenta-se como boa alternativa de tratamento em relação à abordagem aberta, especialmente nas fraturas de menor complexidade.

Introduction

Scapular fractures account for approximately 1% of all fractures, affecting the articular surface in 10% of cases.[1] Percutaneous reduction and fixation of these fractures using arthroscopy provide articular visualization with precise reduction, diagnosis, and treatment of any associated injuries (either capsular, ligamentous, or tendon lesions), lower surgical trauma reduced blood loss, and better aesthetic results.[2] Studies demonstrating good outcomes are promising, but most have short or medium-term follow-up.[3,4] This paper aims to report one case of displaced glenoid fracture submitted to percutaneous reduction and fixation with arthroscopy and demonstrate long-term outcomes (18 years).

Case Report

The ethics committee of our institution approved this case report under number CAAE 52798421.4.0000.0020.

A 27-year-old male, right-handed patient, working as a systems analyst, suffered trauma to the left shoulder after falling off a motorcycle in January 2005. On physical examination, he presented edema and pain in the left scapular and clavicular regions with functional loss of the same shoulder. The patient presented preserved neurological function and perfusion of the upper limb and no other systemic injuries. A simple radiograph showed a scapular fracture involving the glenoid cavity, transverse and displaced, extending to the base of the coracoid process, classified as type III by the Ideberg criteria.[4] On the same side, there was a displaced distal clavicular fracture (►**Fig. 1**). The patient underwent surgical treatment on the second day after the trauma, with reduction and percutaneous fixation of the glenoid and clavicle fractures assisted by arthroscopy.

Surgical Technique and Outcome

We put the patient in the supine "beach chair" position under general anesthesia, interscalene block, and the image intensifier in place. After arthroscopic joint inspection to rule out associated injuries, we debrided and reduced the fracture site using a dissector-type instrument under simultaneous radioscopic control (►**Fig. 2**). After satisfactory reduction, we performed bone fixation with two percutaneous 1.5 mm Kirschner (K) wires inserted through the superior surface of the glenoid. Lastly, we performed the supplementary percutaneous fixation of the clavicle fracture. Postoperative radiographs confirmed good reduction and K wire positioning (►**Fig. 3**). We immobilized the shoulder with a simple sling for four weeks and instructed the patient to start elbow, wrist, and hand exercises immediately. Gain in joint range of motion and muscle strength began after 3 and 6 weeks,

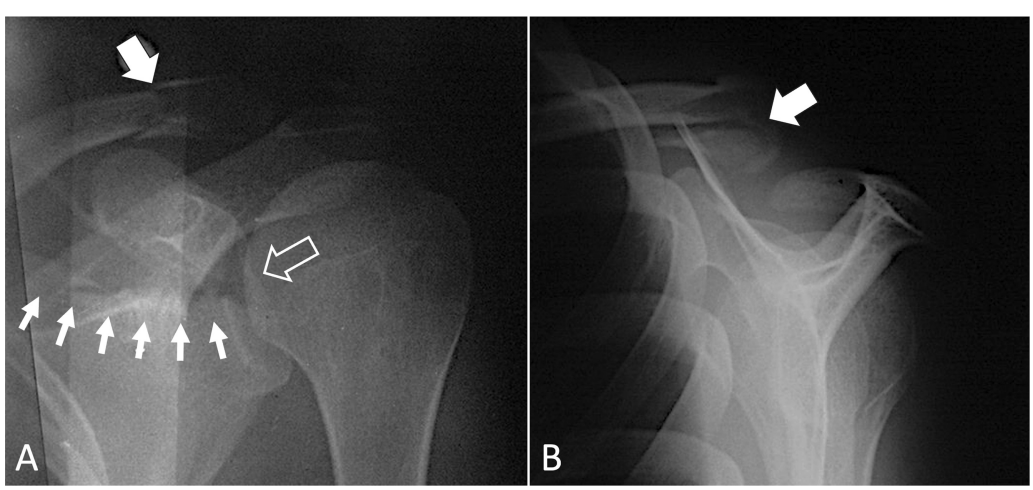

Fig. 1 Radiographs of the left shoulder. The anteroposterior view (A) demonstrates the transverse and displaced scapular fracture involving the glenoid cavity and extending to the base of the coracoid process, classified as Ideberg type III (small arrows); detail of the joint displacement (large empty arrow); detail of the fracture in the distal clavicle (large solid arrow). The lateral view (B) details the displacement in the distal clavicular fracture (large solid arrow). Source: authors' archive.

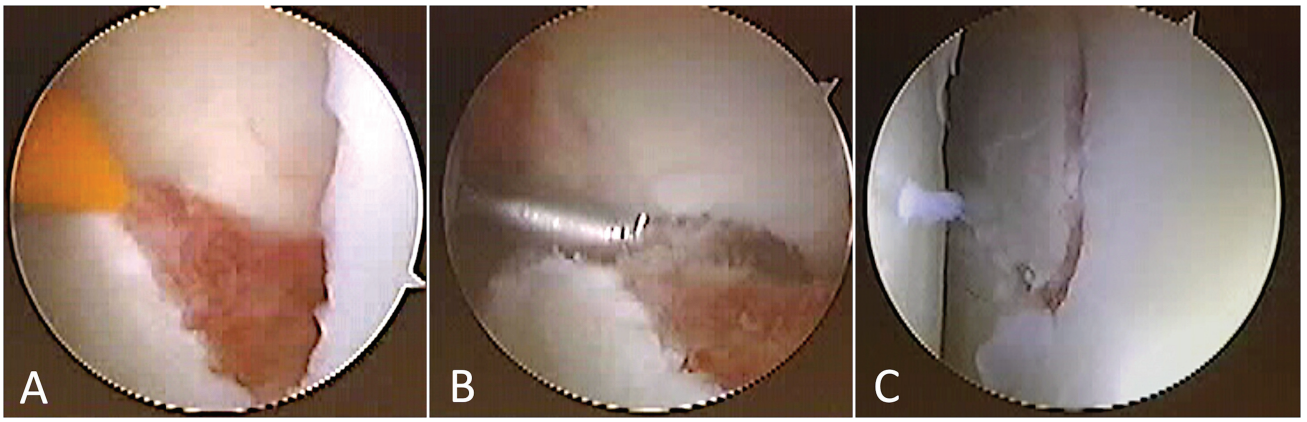

Fig. 2 Photographs of the arthroscopic surgical procedure. (A) Detail of the glenoid joint displacement after debridement of the fracture hematoma. (B) Detail of the reduction with a dissector-type instrument. (C) Detail of the final joint reduction. Source: authors' archive.

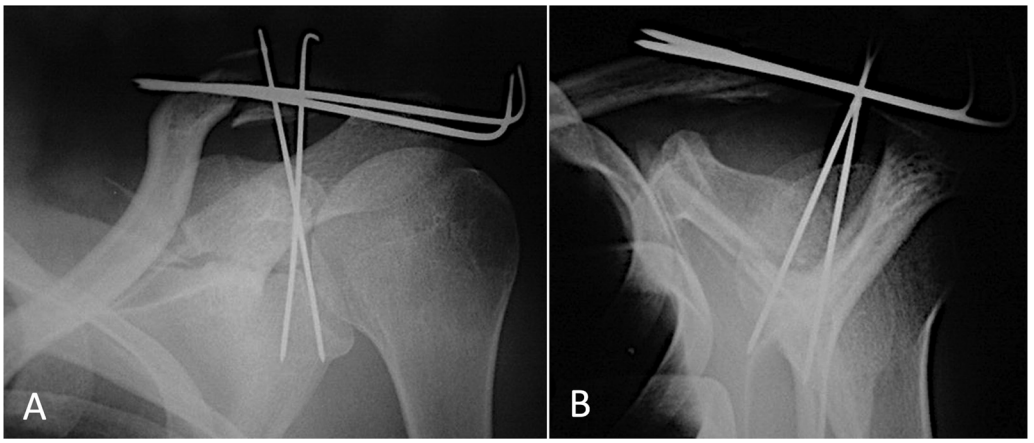

Fig. 3 Radiographs of the left shoulder demonstrating immediate postoperative follow-up in anteroposterior (A) and lateral (B) views after percutaneous fixation of the scapula and distal clavicle fractures with Kirschner wires. Source: authors' archive.

respectively. We removed the K wires after radiographic confirmation of the consolidation six weeks after the index procedure. The outcome assessment included clinical examination, radiographs, and the University of California at Los Angeles (UCLA) score criteria.[5] In follow-up visits 1 and 18 years after surgery, the patient was asymptomatic, with a symmetrical shoulder range of motion (UCLA score of 35, i.e., satisfactory/excellent) and no relevant radiographic changes (►**Figs, 4** and **5**).

Discussion

The current management of scapular fractures involving the glenoid cavity and displacements higher than 3 to 5 mm

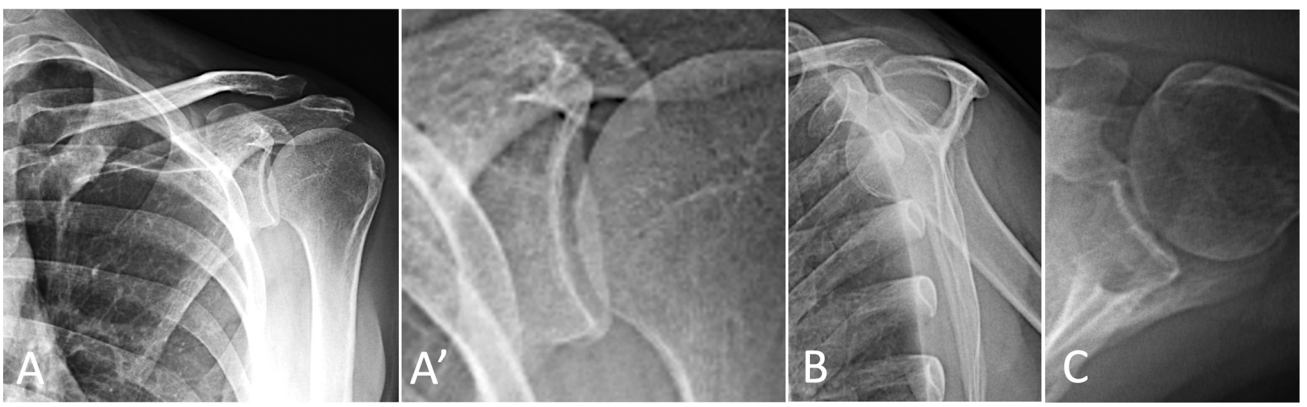

Fig. 4 Photographs showing details of the clinical examination at 18 years of postoperative follow-up, with symmetrical shoulder joint range, trophism, and satisfactory aesthetic appearance. (A) Anterior flexion range. (B) Medial rotation range. (C and D) Trophism and posterior and anterior aesthetic appearance of the shoulders, respectively; (E) Lateral rotation range. Source: authors' archive.



Fig. 5 Radiographs of the left shoulder in anteroposterior (A), lateral (B), and axillary (C) views 18 years after the initial surgical treatment, demonstrating good appearance and no relevant changes. (A) Details of the glenoid contour and joint space. Source: authors' archive.

recommends surgical reduction and osteosynthesis.[4] Traditional surgical approaches use arthrotomy, which allows good visualization, reduction, and fixation of the fracture for early mobilization. Although effective, they usually involve extensive accesses, with significant surgical morbidity.[1,2,4] The arthroscopic alternative introduced by Carro et al.[6] in 1999 to treat glenoid rim fractures is an efficient option and causes less surgical trauma. Other authors have demonstrated the technique for more complex fractures, including recommendations and tips.[2,4] Most publications refer to the fixation of Ideberg type III fractures, similar to our case, demonstrating satisfactory outcomes, no complications, and the advantages previously mentioned. Disadvantages include the need for local hospital structure, learning curve, and surgeon skills. Regarding the technique, most authors recommend the beach chair position due to the eventual need for conversion to open surgery.[2,3,7] In 2016, Park[8] reported using cannulated screws as an easier alternative, considering that the upper fragment is often single (type III fractures). Their insertion in an anterograde manner through the superior Neviaser portal offers a low risk of nerve and vessel injury.[9] Guides for knee surgery can facilitate wire insertion.[3] Bonczek et al.[7] suggested another technical detail, i.e., using the coracoid process as a joystick for indirect reduction. Associated injuries may require fixation, such as the distal clavicle presented by our patient.[10] The literature is scarce, with limited experience and short- to medium-term outcomes. Yang et al.[3] reported the largest experience, with 18 cases and a mean follow-up of 2 to 5 years. Although this report refers to a single case, we demonstrated the longest follow-up time according to the literature, and our patient is asymptomatic and has no radiographic signs of glenohumeral osteoarthritis for this fracture profile. While the arthroscopic management of glenoid fractures is still evolving and requires studies with longer case series and follow-up time, it is a good treatment alternative to the open approach, especially in less complex fractures.

Financial Support
The authors declare that the authors received no financial support from public, commercial, or not-for-profit sources

Conflict of Interests
The authors declare no conflicts of interest.

References

1 Dimopoulos L, Antoniadou T, Desai C, Nikolaides AP, Kalogrianitis S. Operative treatment of complex intra-articular scapular fractures: long-term functional outcomes in a single-center study. Eur J Orthop Surg Traumatol 2023;33(05):1621–1627
2 Lin IH, Lin TL, Chang HW, et al. Arthroscopy-Assisted Reduction and Internal Fixation versus Open Reduction and Internal Fixation for Glenoid Fracture with Scapular Involvement: A Retrospective Cohort Study. J Clin Med 2022;11(04):1131
3 Yang HB, Wang D, He XJ. Arthroscopic-assisted reduction and percutaneous cannulated screw fixation for Ideberg type III glenoid fractures: a minimum 2-year follow-up of 18 cases. Am J Sports Med 2011;39(09):1923–1928
4 Seidl AJ, Joyce CD. Acute fractures of the glenoid. J Am Acad Orthop Surg 2020;28(22):e978–e987
5 Ellman H, Hanker G, Bayer M. Repair of the rotator cuff. End-result study of factors influencing reconstruction. J Bone Joint Surg Am 1986;68(08):1136–1144

6 Carro LP, Nuñez MP, Llata JI. Arthroscopic-assisted reduction and percutaneous external fixation of a displaced intra-articular glenoid fracture. Arthroscopy 1999;15(02):211–214
7 Bonczek SJ, Hutchinson R, Chakravarthy J. An innovative method of fracture reduction in an arthroscopically assisted cannulated screw fixation of an Ideberg type III glenoid fracture. Int J Shoulder Surg 2015;9(02):56–59
8 Park SG. Arthroscopy assisted 2 cannulated screw fixation for transverse glenoid fracture: A case report. Clin Shoulder Elbow 2016;19(02):105–109 Available from https://www.cisejournal.org/journal/view.php?number=402
9 Marsland D, Ahmed HA. Arthroscopically assisted fixation of glenoid fractures: a cadaver study to show potential applications of percutaneous screw insertion and anatomic risks. J Shoulder Elbow Surg 2011;20(03):481–490
10 Branco PM, Marques TP, Pires L, Alonso R. Fixação percutânea da fractura da glenóide com apoio artroscópico, em disrupção tripla do complexo suspensor superior do ombro caso clínico sociedade portuguesa de ortopedia e traumatologia. Rev Port Ortop Traumatol 2018;26(03):267–275