Radiocarpal Fracture Dislocation: Minimally Invasive Treatment Assisted by Arthoscopic – Case Report

Fratura-luxação radiocárpica: Tratamento minimamente invasivo assistido por artroscopia – Relato de caso

Marcio Aurelio Aita[1] Ricardo Kaempf de Oliveira[2] Bruno Gianordoli Biondi[3] Gustavo Luis Rodriguez Gómez[4] Marcos Jun Tamura[5] Gustavo Mantovani Ruggiero[6]

[1] Surgery Department, Orthopedic and Trauma, Hand and Microsurgery Division, Faculdade de Medicina do ABC, São Bernardo do Campo, SP, Brazil
[2] Orthopedic and Trauma Department, Santa Casa de Porto Alegre, Porto Alegre, RS, Brazil
[3] Orthopedic and Trauma Department, Hand and Microsurgery Division, Faculdade de Medicina do ABC, Santo Andre, SP, Brazil
[4] Hand Surgery Department, Clínica de la Mano de Buenos Aires, Buenos Aires, Argentina
[5] Orthopedic and Trauma Department, Hospital Assunção, Rede D'or, São Bernardo do Campo, SP, Brazil
[6] Plastic Surgery Department, Universita Degli Studi Di Milano, Milan, Italy

Address for correspondence Marcio Aurelio Aita, PhD, Faculdade de Medicina do ABC, Department of Surgery, Orthopedics and Trauma, Division of Hand and Microsurgery, Av. Príncipe de Gales, 821, Príncipe de Gales, Santo André, SP, 09060-650, Brazil (e-mail: marcioaita@me.com).

Rev Bras Ortop 2024;59(S2):e168–e172.

Abstract

To measure the life quality, clinical-functional outcomes of a patient who had undergone acute reconstruction of radio scapho capitate (RSC), radio lunate (RLL) ligaments, using brachiorradialis tendon in treatment of radiocarpal fracture dislocation. 21-years-old, man with radiocarpal fracture dislocation in his left wrist, after motorcycle accident. Percutaneous screw fixation of the distal radius and acute reconstruction of the RSC and RLL was performed, assisted by arthroscopy. One year later, the patient experienced good evaluation. ROM was full, grip strength was 96% compared with the unaffected side were obtained. Wrist radiographic aspects showed fracture healed and radiocarpal joint congruency. Good stability and joint congruency of the radiocarpal joint were obtained and improving the life quality of that patient. Radiocarpal fracture dislocation management is difficult and complicated. There is no consensus. As there is still a lack of long-term results, the indications for surgery, and options, type of the intervention have been a matter of controversy in the

Keywords
- carpal bone
- joint dislocations
- radius fractures
- wrist injuries

received
November 29, 2020
accepted
April 23, 2021

DOI https://doi.org/10.1055/s-0044-1790593.
ISSN 0102-3616.

© 2024. The Author(s).
This is an open access article published by Thieme under the terms of the Creative Commons Attribution 4.0 International License, permitting copying and reproduction so long as the original work is given appropriate credit (https://creativecommons.org/licenses/by/4.0/).

Thieme Revinter Publicações Ltda., Rua do Matoso 170, Rio de Janeiro, RJ, CEP 20270-135, Brazil

literature. Would radiocarpal (RC) joint be stable when reconstruction of the radiocarpal ligaments, using brachiorradialis tendon was obtained? Is it possible to reduce and to maintain stable radiocarpal joint with this technique? The clinical relevance of this work is our suggestion of reconstruction of the RC ligament to improve this treatment. We believe that this will maintain a stable and functional wrist. We agree that the best time to perform corrections is as soon as possible and we prefer to reconstruct the RC ligament with suture or temporary or permanent radioscapholunate arthrodesis.

Resumo

Este estudo mediu a qualidade de vida e os desfechos clínicos e funcionais de um paciente com fratura-luxação radiocárpica submetido a reconstrução aguda dos ligamentos radioescafocapita-to (REC) e radiosemilunar (RSL) usando o tendão braquiorradial. O paciente era um homem de 21 anos com fratura-luxação radiocárpica no punho esquerdo após acidente de moto. A fixação percutânea foi realizada com parafuso no rádio distal e reconstrução aguda assistida por artros-copia do REC e RSL. Um ano depois, o paciente apresentou boa avaliação. A amplitude de mo-vimento era completa e a força de preensão era de 96% em comparação ao lado não acometido. Os aspectos radiográficos do punho mostraram a fratura consolidada e congruência da articula-ção radiocárpica. A boa estabilidade e congruência da articulação radiocárpica melhoraram a qualidade de vida do paciente. O tratamento da fratura-luxação radiocárpica é difícil e compli-cado. Não há consenso. Como ainda não há resultados em longo prazo, as indicações para ci-rurgia e opções terapêutica têm sido motivo de controvérsia na literatura. A articulação radio-cárpica (RC) seria estável após a reconstrução dos ligamentos radiocárpicos usando o tendão braquiorradial? Seria possível reduzir e manter a articulação radiocárpica estável com esta téc-nica? A relevância clínica deste trabalho é a nossa sugestão de reconstrução do ligamento RC para melhorar este tratamento. Acreditamos que manteremos o punho estável e funcional. Con-cordamos que o melhor momento para realizar as correções é o mais breve possível e preferi-mos reconstruir o ligamento RC com sutura ou artrodese radioescafosemilunar temporária ou definitiva.

Palavras-chave
- fraturas do rádio
- luxações articulares
- ossos do carpo
- traumatismos do punho

Introduction

Radiocarpal fracture-dislocation is an uncommon traumatic disorder associated with injuries to the radiocarpal (RC) and radioulnar ligaments (RU). Diagnosis is delayed because of the lack of radiographic findings, and is made following chronic failure (instability) of the joint and wrist pain. Treatment of acute dislocation usually involves stabilization and ligament suture. In this patient, we stabilized the radiocarpal joint by RC reconstruction using a brachiorradialis tendon graft.

Case Description

A 21-year-old patient with motorcycle injury (politrauma) was presented with pain and deformity on the left dominant forearm. Initial radiographs revealed Radio carpal and DRUJ incongruence with radial styloid fracture (►**Fig. 1**). The patient had received treatment with closed reduction and percutaneous fixation (Headless compression screw HCS®, Synthes®, Davos, Switzerland) in styloid radial. After, physical examination revealed RC/DRUJ unstables, and the ulnar head had dorsal prominence. We decided (intra-operative) to perform wrist arthroscopy and diagnosed complex lesion: radio carpal ligaments and TFCC foveal avulsion (hook and trampolim tests were positive). Therefore, addressed the radio carpal instability by reconstruction of the radio carpal ligaments (RSC,RLL) using BR tendon.

The patient was kept with a long removable splint above the elbow for two weeks after the surgery, with his wrist in a neutral position for the improvement of the natural regain of pronation and supination. We started occupational therapy for the improvement of the forearm range in the first week after surgery. Four months after, the patient achieved with no pain and a stable radio carpal joint and DRUJ, exhibited good range of motion (ROM) for wrist, forearm, elbow and all digits. DASH



Fig. 1 Wrist radiographic preoperative aspect – radiocarpal fractures dislocation.

score of 6, a VAS score of 0, and grip strength of 96% as compared with the opposite wrist. X-ray images revealed the articular congruency of DRUJ, styloid radial healing, and better bone attachment to the implants (►**Video 1**).

Video 1

Clinical case: pre-, intra-, and postoperative aspects: from diagnosis to daily activities return.
Online content including video sequences viewable at: https://www.thieme-connect.com/products/ejournals/html/10.1055/s-0044-1790593.

Surgical Technique

Wrist radial approach, wherein the BR tendon was identified, harvested, and shared in two parts: to RSC and other part to RLL. Therefore, we prepared with an internal brace (FiberTape® wire suture, Arthrex Inc., Naples, FL) by sectioning the tendon on its muscle transition and preserving the insertion on the radius styloid. After, we employed a medial ulnar approach for the reinsertion of TFCC in ulna by using the DX® anchor, through transverse tunnel, according the technique recommended by the manufacturer. After, we created three tunnels (scaphoid, lunate and capitate) by using a 3.5-mm cannulated drill, according the technique described by the authors, assisted by arthroscopy. We passed the BR tendon graft through the tunnel and kept it tensed on the palmar face on the lunate first (►**Fig. 2**) and, scaphoid and capitate (►**Fig. 3**) after, thereby providing stability between the radiocarpal joint. The definitive implants on the scaphoid, capitate and lunate were only inserted after accomplishing stability (DX®). (►**Figs. 4**, **5** and ►**Video 1**).

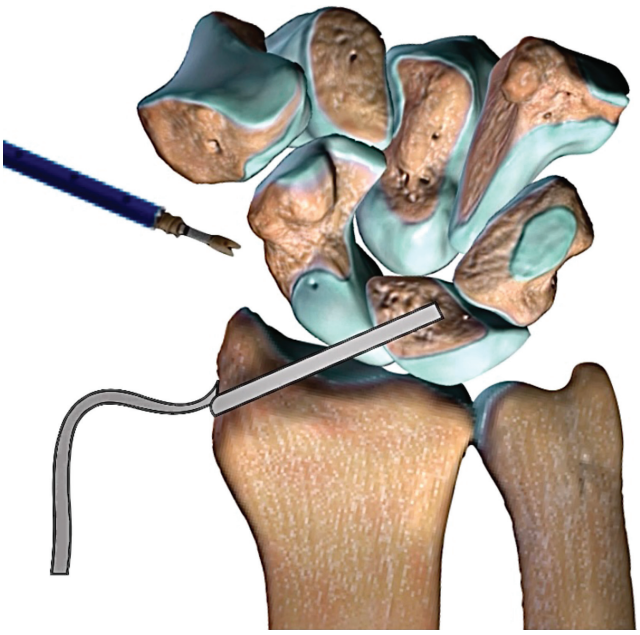

Fig. 2 Schematic draw: reconstruction of radiolunate ligament.



Fig. 3 Schematic draw: reconstruction of radio scaphocapitate ligament.

Discussion

Conventional treatment suggests open reduction and fixation of the styloid radial (screw, k-wires or specific plate) and direct suture repair the radio carpal and TFCC ligaments with k-wires.[1]



Fig. 4 Postoperative aspects of anteroposterior wrist radiography.



Fig. 5 Postoperative aspects of wrist radiography in lateral view.

In acute lesions, it is possible directly repair the radio carpal ligaments and TFCC, however, there is no consensus to the overall management.

In chronic lesions (the most common), we often need to reduce RC / DRUJ. Moreover, there is a need for procedures such as: Wrist partial arthrodesis, shortening the ulna and reconstructing the radio carpal ligaments. Aita et al.[2] published reconstruction of the RSC and obtained promising results for the stabilization of wrist and prevention of the osteoarthritis.

Aita and Mantovani[3] suggested algorithm for treating ligament lesions and introduced the wrist arthroscopy and internal brace® for the repair/reconstruction of intrinsic/extrinsic wrist carpal ligaments. It was advantageous as a direct view of the articular structures, avoid wrist dorsal capsule incision, to preserve upper limb proprioception, thereby avoiding other surgical sites.

Potter et al.[4] described the "spanning" as a stabilizer of the radio carpal joint, as opposed direction to that treat here, using the specific radio carpal plate with temporary arthrodesis and achieved positive results.

Here, we suggest that "internal brace" is also sufficient to treat RC and DRUJ traumatic instabilities, as this is an anatomical repair/reconstruction similar to that of the RSC/RLL or TFCC reconstruction. All procedures preserve the stability and mobility of the wrist and to increase the strength of the reconstruction and its protection.[3]

The authors have a wide range of experience of using the BR tendon graft, offered a promising and efficient solution on this case and appears to be reproducible for future surgical interventions.[5]

We agree that a long-term result, especially on a young patient as this one, is uncertain, and there will be some known and unknown complications in the future. There might be an additional need of another salvage procedure; however, the excellent functional outcome on this mid-term follow-up seems to justify this indication on these special circumstances.

Authors 'Contributions

1. Marcio Aurelio Aita, author of the article, main surgeon in this case.
2. Ricardo Kaempf de Oliveira, author of the article, researcher who raised the articles and acted in correcting the text, including the proficiency of the english language.
3. Bruno Gianordoli Biondi, author of the article, auxiliary surgeon of this case.
4. Luis Gustavo Rodriguez Gómez, author of the article, researcher who worked on correcting the text and made all the drawings of the surgical technique.
5. Marcos Jun Tamura, author of the article, auxiliary surgeon of this case.
6. Gustavo Mantovani Ruggiero, author of the article, researcher who worked on the description of the idea and the surgical technique applied here.

Financial Support
The authors declare that this study received no funding from public, commercial, or not-for-profit sector agencies.

Conflict Interests
The authors declare that they have no conflicts of interest to disclose.

References

1 Jebson PJ, Adams BD, Meletiou SD. Ulnar translocation instability of the carpus after a dorsal radiocarpal dislocation: a case report. Am J Orthop 2000;29(06):462–464

2 Aita MA, Alves RS, Ibanez DS, Consoni DAP, de Oliveira RK, Ruggiero GM. Reconstruction of Radioscaphocapitate Ligament in Treatment of Ulnar Translation. J Wrist Surg 2019;8(02):147–151
3 Aita MA, Mantovani GR. Manejo Artroscópico para Fraturas do Cotovelo, Punho e Mão. In: Ribak S, Rezende MR, Pignataro MB, Santos JBG, Neder Filho AR, Costa AC, editores. Atualização em Cirurgia da Mão Traumatologia. São Paulo: DiLivros;; 2021: 237–251
4 Potter MQ, Haller JM, Tyser AR. Ligamentous radiocarpal fracture-dislocation treated with wrist-spanning plate and volar ligament repair. J Wrist Surg 2014;3(04):265–268
5 Aita MA, Mallozi RC, Ozaki W, Ikeuti DH, Consoni DAP, Ruggiero GM. Ligamentous reconstruction of the interosseous membrane of the forearm in the treatment of instability of the distal radioulnar joint. Rev Bras Ortop 2018;53(02): 184–191