Popliteal Neurovascular Bundle Medialization and Axial Flap Rotation to Avoid Bone Impingement in Tibial Turn-up Plasty: A Case Report

Medialização do feixe neurovascular poplíteo e rotação axial do retalho para evitar o impacto ósseo na plastia de inversão tibial: Relato de caso

Manuel Ricardo Medellin Rincon[1] Oscar Fernando Gomez-Ricaurte[1]
Hermann Alfredo Riveros-Riveros[1] Andrea Sambri[2]

[1] Department of Orthopedic Surgery, Grupo Bogotano de Ortopedia y Sarcomas, Bogotá, Colombia
[2] Department of Orthopedic Surgery, IRCCS Azienda Ospedaliera Universitaria di Bologna, Bologna, Italy

Address for correspondence Manuel Ricardo Medellin Rincon, MD, Spc., Fundación CTIC Luis Carlos Sarmiento Angulo, Calle 168 # 14 - 42, Bogotá, Cundinamarca, Colombia (e-mail: manuel.medellinrincon@gmail.com).

Rev Bras Ortop 2024;59(S2):e163–e167.

Abstract

A 33-year-old male patient developed distal femur chronic osteomyelitis with massive bone loss after an open grade-3b fracture. Following several failed treatments to eradicate infection, a tibial turn-up procedure was performed to provide a stable and functional stump. To avoid neurovascular problems, the popliteal vessels and sciatic nerve were moved medially, and the flap was rotated externally to decrease the collapse. The progression after surgery was satisfactory, no vascular or neurological claudication was observed, and the patient has been able to wear an external prosthesis after flap healing. Tibial turn-up plasty is a rarely described reconstructive technique capable of providing longer stumps. The releasing and medialization of popliteal vessels, with axial rotation of the flap, may prevent the development of neurovascular impingement.

Keywords
- amputation stumps
- bone transplantation
- osteomyelitis
- surgical flaps

Resumo

Um paciente do sexo masculino, de 33 anos, apresentou osteomielite crônica do fêmur distal com perda óssea maciça após fratura exposta de grau 3b. Após vários tratamentos ineficazes para erradicar a infecção, foi realizado um procedimento de aumento da tíbia para proporcionar um coto estável e funcional. Para evitar problemas neurovasculares, os vasos poplíteos e o nervo ciático foram movidos em sentido medial e o retalho foi rotacionado externamente para diminuição do colapso. A evolução após a cirurgia foi satisfatória; não houve claudicação vascular ou neurológica, e o paciente pôde usar prótese externa após a cicatrização do retalho. A plastia tibial é uma técnica reconstrutiva raramente descrita, que pode aumentar o comprimento dos cotos. A liberação e medialização dos vasos poplíteos, com rotação axial do retalho, pode prevenir o desenvolvimento de impacto neurovascular.

Palavras-chave
- cotos de amputação
- osteomielite
- retalhos cirúrgicos
- transplante ósseo

Work carried out at the Clinica Nueva, Calle, Bogotá, Colombia.

received
March 9, 2023
accepted
May 29, 2023

DOI https://doi.org/10.1055/s-0044-1779308.
ISSN 0102-3616.

© 2024. The Author(s).
This is an open access article published by Thieme under the terms of the Creative Commons Attribution 4.0 International License, permitting copying and reproduction so long as the original work is given appropriate credit (https://creativecommons.org/licenses/by/4.0/).

Thieme Revinter Publicações Ltda., Rua do Matoso 170, Rio de Janeiro, RJ, CEP 20270-135, Brazil

Introduction

Tibial turn-up is a uncommon type of amputation-rotationplasty that has several potential indications.[1] The objective of this technique is to develop a longer and functional stump, using the patient's leg or foot to reconstruct femoral or tibial defects.[2] Since the first report by Sauerbruch,[3] less than 30 cases have been published. It differs from a Van Nes rotationplasty[4] regarding the axis of rotation, as the leg is turned 180° over the thigh in the coronal plane instead of the axial plane.

Due to the very rare indication for this surgery, very little information has been written regarding the management of the neurovascular bundle. The purpose of the present paper is to describe an approach to the tibial turn-up technique to avoid impingement of the popliteal vessels and sciatic nerve.

Case Report

Ethical clearance for the study was obtained from the institutional Ethics in Research Committee on September 12, 2022, and written informed consent was obtained from the patient.

A 33-year-old male patient sustained a Grade-IIIB open fracture of the distal femur and patella after a motorcycle accident in a rural area. He was initially treated in a low-complexity rural center through external fixation and several debridements due to gross contamination. As the process could not be managed locally, the patient was referred to our institution with a diagnosis of soft-tissue sepsis and osteomyelitis.

A distal femoral resection was required due to bone necrosis and persistence of the sepsis after wide-spectrum antibiotics and debridements. A temporary cement spacer was placed, and control of the septic process was achieved.

The wounds healed and the hardware remained stable during a six-week antibiotic course. Patellar osteosynthesis was performed to preserve the extensor mechanism. The patient remained with the fixator for six months due to loss to follow-up. At that point, the implants were removed and converted into a new spacer over a long intramedullary nail for arthrodesis.

The patient decided to continue with the spacer, but after one year the infection reactivated (►**Fig. 1A**). Considering the difficulties to reconstruct the femur, soft-tissue compromise, and extension of the infection (►**Fig. 1B**), the patient selected an ablative surgery. A tibial turn-up plasty was proposed to preserve length, following a debridement with samples, and a new antibiotic scheme.

In the final surgery, the hardware was removed, and the tibial/femoral canals were cleaned using an irrigation-aspiration system (Reamer Irrigator Aspirator [RIA], Johnson & Johnson MedTech, New Brunswick, NJ, United States). The flap was designed, resecting the anterolateral thigh skin, patella, ligaments, proximal and distal thirds of the tibia, the fibula, and the anterior part of the skin of the leg skin and foot



Fig. 1 Clinical and radiological aspect one year after the knee arthrodesis procedure. (**A**) In the soft tissue, a fistula with purulent drainage can be observed. (**B**) Reconstructed anteroposterior panoramic X-ray view. The extension of the nail can be observed, including the changes in the femur, such as the sclerotic areas and the new bone formation around the cement spacer. In the distal tibia, radiolucent areas with relationship with the tip of the nail were identified.

(►**Fig. 2A**). The anterior tibial periosteum was preserved by removal of the tibialis anterior muscle (►**Fig. 2B**).

The tibialis vessels were tied distally; the popliteal vessels and sciatic nerve were identified and medially moved in the flexion area of the flap (►**Fig. 2C** and **2D**). The remaining tibia was adjusted and fixed to the femur with a 4.5-mm titanium dynamic compression plate (DCP) (Königsee Implantate GmbH, Allendorf, Hessen, Germany), after rotating the flap 45° in the axial plane (►**Figs. 2E** and **3**). The soft tissue and skin were closed in a normal fashion.

An uneventful recovery was observed, with bone consolidation at six months, (►**Fig. 4**). The patient was followed up for more than 40 months. He is fully recovered and is able to perform his activities with an external prosthesis (►**Fig. 5A** and **5B**).

Discussion

Tibial turn-up is a highly uncommon type of surgery performed when no other reconstructive alternatives are available.[5] Although it is an ablative intervention, its main objective is to develop longer amputation stumps, when total or almost total resection of the femur or tibia must be performed.[6]

Due to the anatomical repairs in this reconstruction, the popliteal vessels and sciatic nerve will lie behind the tibial segment after the flap inversion. Therefore, there is a risk of

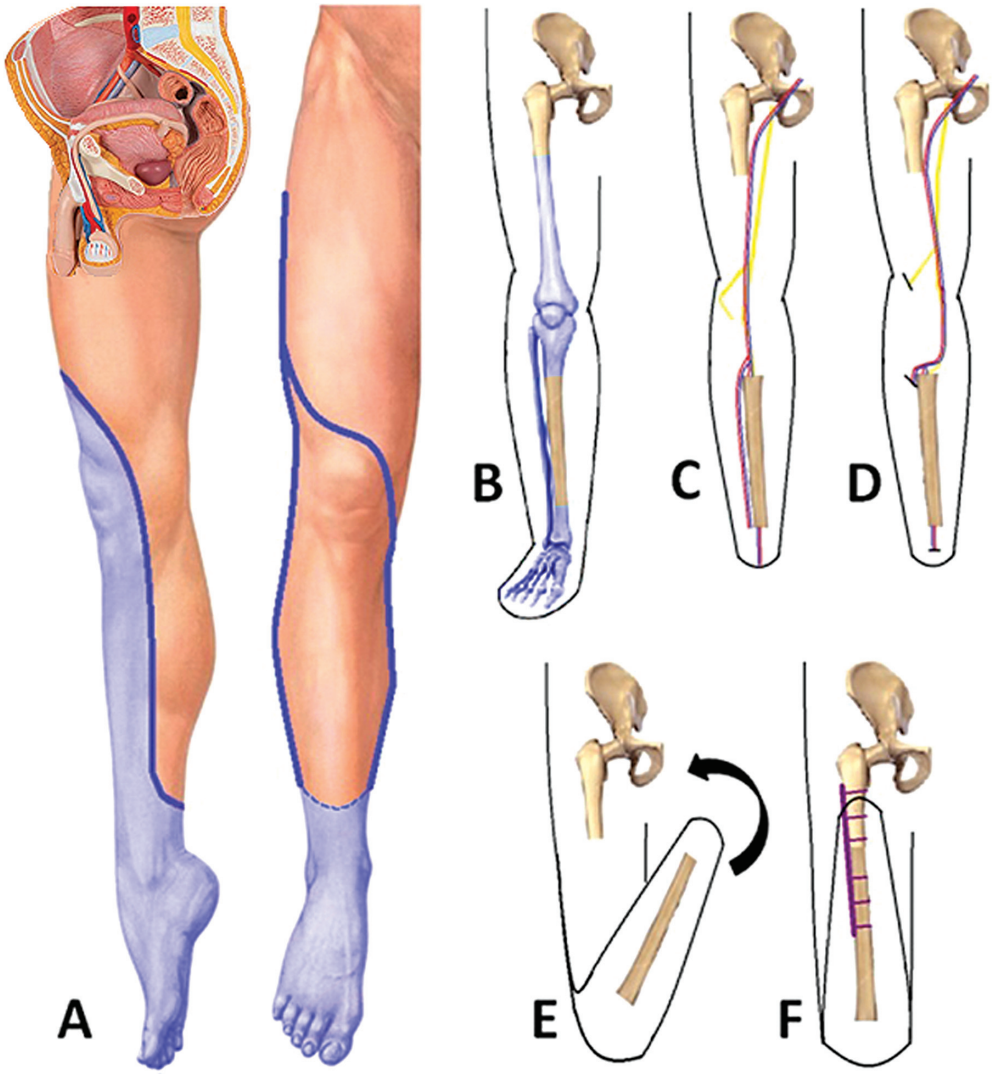

Fig. 2 Summary of the steps involved in the surgical technique and intraoperative images. (**A**) Flap design on anteroposterior and medial views, indicating the areas to be resected. (**B**) In light blue color, the bone segments to be removed were identified. (**C**) Preliminary aspect of the flap after bone excision with the normal distribution of the neurovascular structures. (**D**) Medial displacement of the popliteal vessels and ligation of the anterior and posterior tibial vessels. The common peroneal nerve was also moved after fibula resection. (**E**) Tibial turn-up and length adjustment of the intercalary segment. (**F**) Internal fixation of the tibial and femoral components with a dynamic compression plate.

impingement with vascular or neurological claudication following the prosthetic fitting.

Since the first report by Ferdinand Sauerbruch in 1922,[3] a total of 18 papers have been published in indexed databases. (PubMed, Hinari, ScienceDirect). The description of the proper management of the popliteal neurovascular bundle is available only in two[7,8] of those reports.

In the first one, Peterson et al.[7] mentioned that popliteal vessels may need to be freed for 8 cm to 10 cm at the point of rotation, to avoid tethering with the tibia. No further description was made regarding the neurovascular management.

In the second one, McDonald et al.,[8] described a pedicled tibial bone flap without soft tissue. Although the usefulness of medializing the vascular component is mentioned in this paper, this technique depends on thigh flaps and sacrifices the sciatic nerve. Therefore, their observations cannot be evaluated in the conventional Sauerbruch reconstruction.

In the case herein reported, releasing the popliteal artery and sciatic nerve at the area of flexion enabled its medial displacement, avoiding impingement with the bone. Additionally, rotating the flap 45° in the axial plane increased the length of the vessel and nerve, decreasing the possible loop collapse.

In conclusion, tibial turn-up is a very useful but not frequently used last resource technique to reconstruct long femoral stumps. Although several modifications can be made,[9] the medialization and relative elongation of the neurovascular structures by rotating the flap seem to be a useful strategy to prevent bone impingement with early or late complications in the stump.

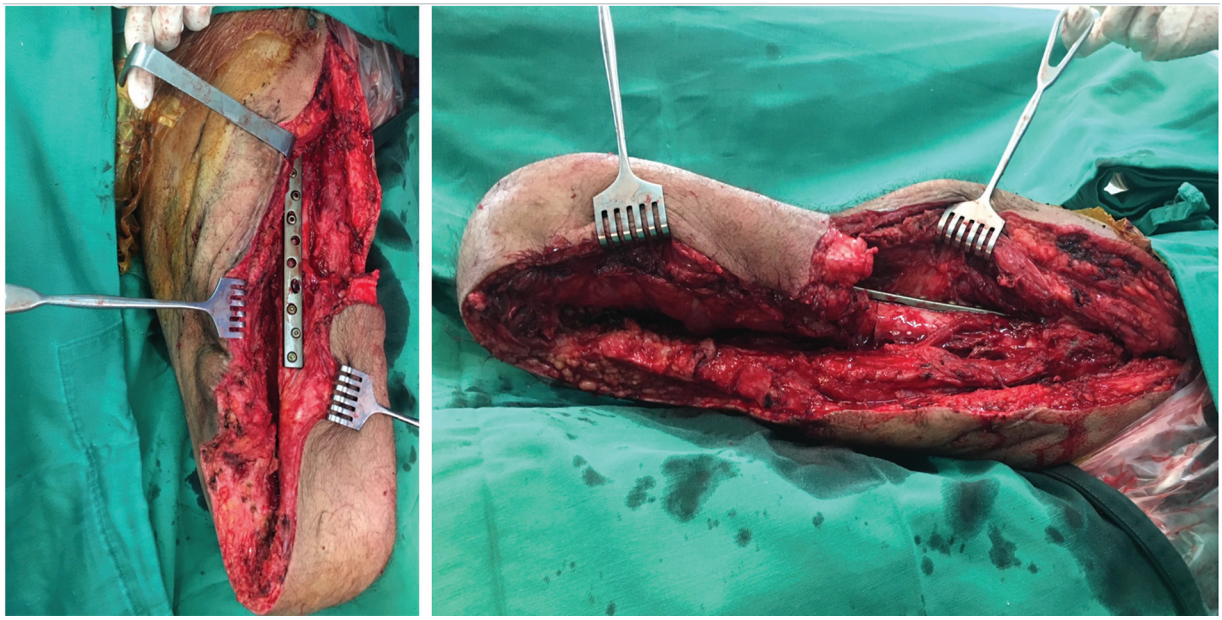

Fig. 3 Intraoperative anteroposterior and lateral images displaying the osteomusculocutaneous flap once it was turned up and fixed to the femur.

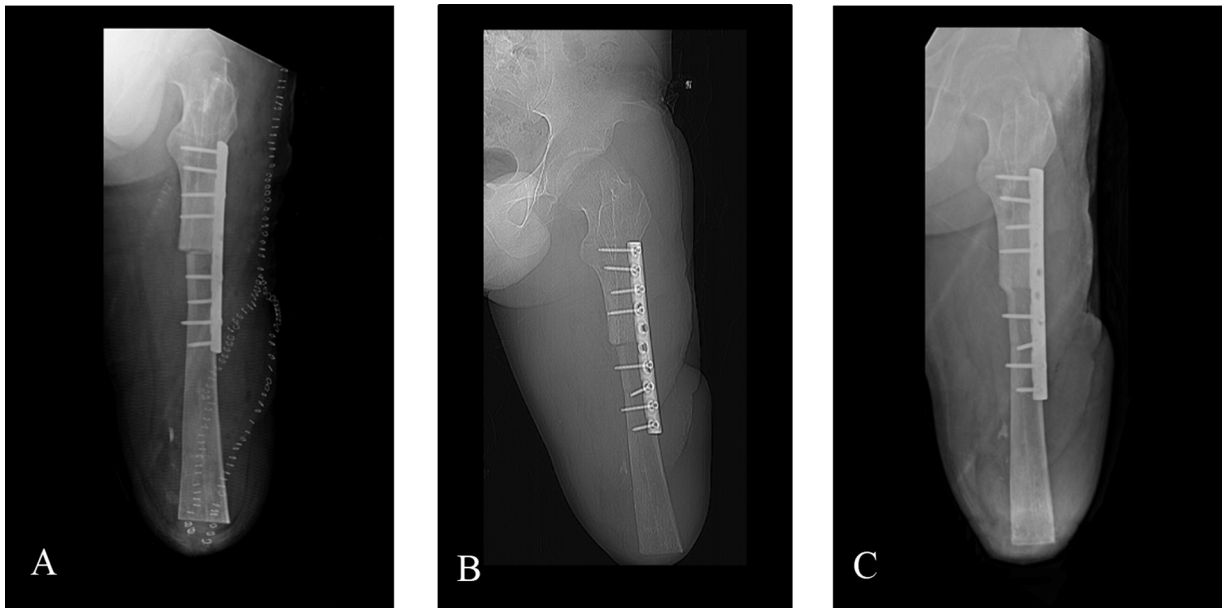

Fig. 4 The sequence presents the progression of the consolidation between the femur and tibia. (**A**) The X-rays were taken in the immediate postoperative period. Skin clips can be observed in the wound area delimitating the flap. (**B**) Image acquired two months after surgery. Some callus formation was observed, but no solid findings of consolidation could be identified. (**C**) X-rays obtained after six months, showing complete consolidation at the junction.

Financial Support
The authors declare that the present research did not receive any specific grants from funding agencies in the public, commercial, or not-for-profit sectors.

Conflict of Interests
The authors have no conflict of interests to declare.

References

1 Tronzo RG, Janek AM. The “turn-up” plasty: one solution to a complex problem. Orthop Nurs 1995;14(03):41–47
2 Song EK, Moon ES, Rowe SM, Chung JY, Yoon TR. Below knee stump reconstruction by turn-up technique. Report of 2 cases. Clin Orthop Relat Res 1994;(307):229–234
3 Sauerbruch F. Die Exstirpation des Femur mit Umkipp-Plastik des Unterschenkels. Deutsche Zeitschrift Chir 1922;169:1–12

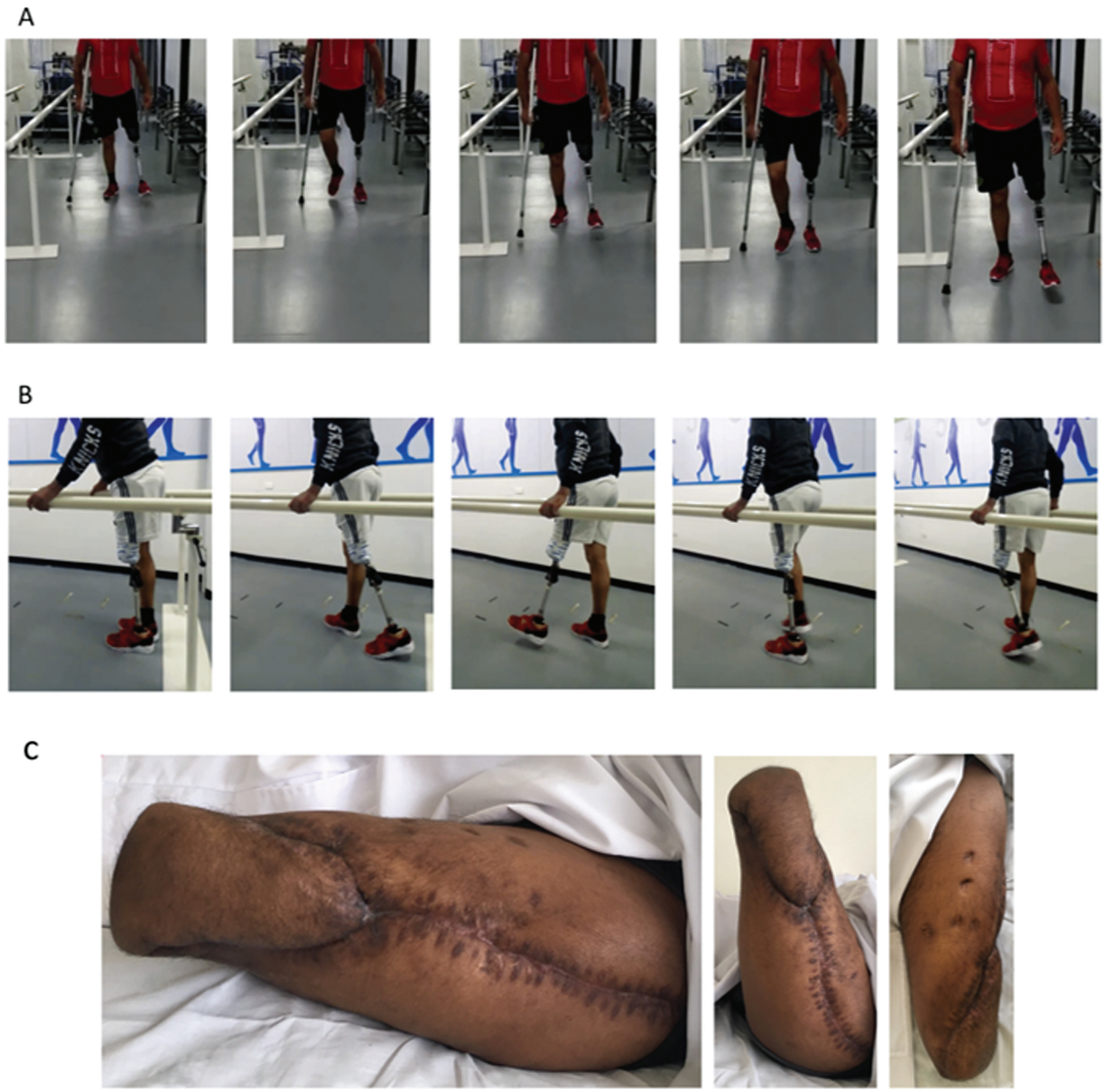

Fig. 5 Final clinical aspect during gait rehabilitation with the use of external prosthesis. The patient is walking with partial weight bearing using one crutch. (**A**) Full weight bearing was performed in line with the lateral supports. (**B**) Photos of the stump once the wounds healed. (**C**) Lateral view of the two images on the left-hand side. The patient is performing active hip flexion and extension effortlessly.

4 Van Nes CP. Transplantation of the tibia and fibula to replace the femur following resection; turn-up-plasty of the leg. J Bone Joint Surg Am 1948;30A(04):854858

5 Sojka JH, Everhart JS, Skoracki RJ, Mayerson JI. Modified femorotibial turn-up plasty using an intercalary fibular autograft strut, femoral potting, and plate fixation. Curr Orthop Pract 2017;28 (05):503–507

6 Enkhbaatar A, Kong CB, Song WS, Cho WH, Koh J-S, Jeon D-G, Lee S-Y. Tibia-hindfoot turn-up rotationplasty in uncontrollable infection after total femoral resection: Report of two cases. J Orthop Sci 2020;25(06):1123–1126

7 Peterson CA II, Koch LD, Wood MB. Tibia-hindfoot osteomusculocutaneous rotationplasty with calcaneopelvic arthrodesis for extensive loss of bone from the proximal part of the femur. A report of two cases. J Bone Joint Surg Am 1997;79(10): 1504–1509

8 McDonald DJ, Scott SM, Eckardt JJ. Tibial turn-up for long distal femoral bone loss. Clin Orthop Relat Res 2001;(383):214–220

9 Kong GY, Rudiger HA, Ek ET, Morrison WA, Choong PF. Reconstruction after external hemipelvectomy using tibia-hindfoot rotationplasty with calcaneo-sacral fixation. Int Semin Surg Oncol 2008;5:1