Fixation of an Osteochondral Fragment with Autologous Bone Picks in the Knee – A Case Report

Fixação de fragmento osteocondral com palitos ósseos autólogos em joelho – Um relato de caso

Elemar da Silva Resch[1] Sandrey da Rosa Machry[1] Caio César Zottis[2] Fernando Knoll Barros[1]

[1] Orthopedics and Traumatology, Hospital Universitário de Santa Maria, Santa Maria, RS, Brazil
[2] Orthopedics and Traumatology, Hospital Independência, Porto Alegre, RS, Brazil

Address for correspondence Elemar da Silva Resch, Médico Ortopedista, Preceptor na Residência Médica em Ortopedia e Traumatologia do Hospital Universitário de Santa Maria, Rua Um, número 227, Santa Maria, RS, Brazil (e-mail: elemarsr@gmail.com).

Rev Bras Ortop 2024;59(S2):e145–e148.

Abstract

Osteochondral injuries in the knee are uncommon in the immature skeleton and are usually related to sporting activities.

Fixation is required depending on the size and location of the fragment. The standard technique is open reduction and internal fixation with metal screws, which are removed in a second procedure after consolidation.

As an alternative to reduce risk and morbidity, fixation of the osteochondral fragment may use autologous bone picks.

This study reports the execution of this surgical technique on a 13-year-old patient who injured his right knee during a soccer match.

Keywords

- bone and bones
- knee fractures
- osteochondritis

Resumo

Lesões osteocondrais no joelho são incomuns no esqueleto imaturo e costumam estar relacionadas com atividades esportivas.

De acordo com o tamanho e a localização do fragmento, a fixação se faz necessária. A técnica padrão é realizada através da redução aberta e fixação interna com parafusos metálicos, que precisam retirados em um segundo procedimento, após consolidação.

Como alternativa, visando a redução de risco e morbidade, existe a fixação do fragmento osteocondral com palitos ósseos autólogos.

O presente trabalho relata a execução dessa técnica cirúrgica, em um paciente de 13 anos que lesionou o joelho direito durante uma partida de futebol.

Palavras-chave

- fraturas do joelho
- osso e ossos
- osteocondrite

Work carried out at the Hospital Universitário de Santa Maria, Santa Maria, RS, Brazil.

received
May 29, 2023
accepted
July 21, 2023

DOI https://doi.org/10.1055/s-0044-1787550.
ISSN 0102-3616.

© 2024. The Author(s).
This is an open access article published by Thieme under the terms of the Creative Commons Attribution 4.0 International License, permitting copying and reproduction so long as the original work is given appropriate credit (https://creativecommons.org/licenses/by/4.0/).

Thieme Revinter Publicações Ltda., Rua do Matoso 170, Rio de Janeiro, RJ, CEP 20270-135, Brazil

Introduction

Articular cartilage is a connective tissue covering the bony surfaces of joints. It is avascular, highly hydrated, and has no neural components.[1] In joint trauma, injuries can be purely chondral or associated with bone fragments, configuring an osteochondral injury.[2,3]

The standard technique for fixation is open reduction and internal fragment fixation with screws. However, these screws require removal in a second surgical procedure. Bioabsorbable synthetic material use is not widespread and can induce foreign body reactions.[4] As such, this study aims to report a technique for osteochondral fragment fixation in the knee using autologous bone sticks from tibial cortical bone.



Fig. 1 Initial X-ray.

Case Report

The Research Ethics Committee of our institution approved this case report under the number (CAAE 68381222.0.0000.5304). The patient's guardian signed the informed consent form.

A male, 13-year-old patient, previously healthy, arrived at the consultation with a history of trauma to the right knee, 2 days prior, resulting from a valgus stress mechanism during soccer practice. Since the event, the patient had moderate pain, inability to mobilize the knee, and 2+/4+ effusion. The radiographic examination revealed a dislocated osteochondral fragment of the lateral condyle of the right knee measuring approximately 3 cm in its largest diameter (►**Fig. 1**).

Therefore, we opted for surgical treatment, i.e., open reduction and internal fixation with the cortical bone stick technique.

The surgery occurred 14 days after initial care. We performed a longitudinal lateral parapatellar arthrotomy, measuring approximately 8 cm, on the patient's right knee. Under direct visualization, the anatomical site was cleaned and grafted, and the fragment measuring 35 mm × 27 mm was identified (►**Fig. 2A**).

Next, we removed a cortical window from the middle diaphysis of the ipsilateral tibia to create bone sticks. To do so, we made a 4-cm longitudinal skin incision over the anteromedial proximal metaphysis of the right tibia. After elevating the periosteum, we opened a window measuring approximately 30 × 15 mm, longer in the longitudinal direction, with a saw to make bone sticks (►**Fig. 2B** and ►**Fig. 3**).

We prepared 5 cortical bone sticks, each measuring approximately 3 mm in diameter and 30 mm in length. The provisional fixation of the osteochondral fragment employed 2.5-mm Kirschner wires. Each Kirschner wire was successively replaced by a bone stick. Subsequently, we lowered the sticks to enter 3 mm into the articular surface. It is worth highlighting that the fixation of the chondral fragment at the site of origin, with the five bone sticks, occurred through an angular insertion divergent to the surface (►**Fig. 4**).

At discharge, we instructed the patient to perform exercises for early limb movement with no support. Two weeks

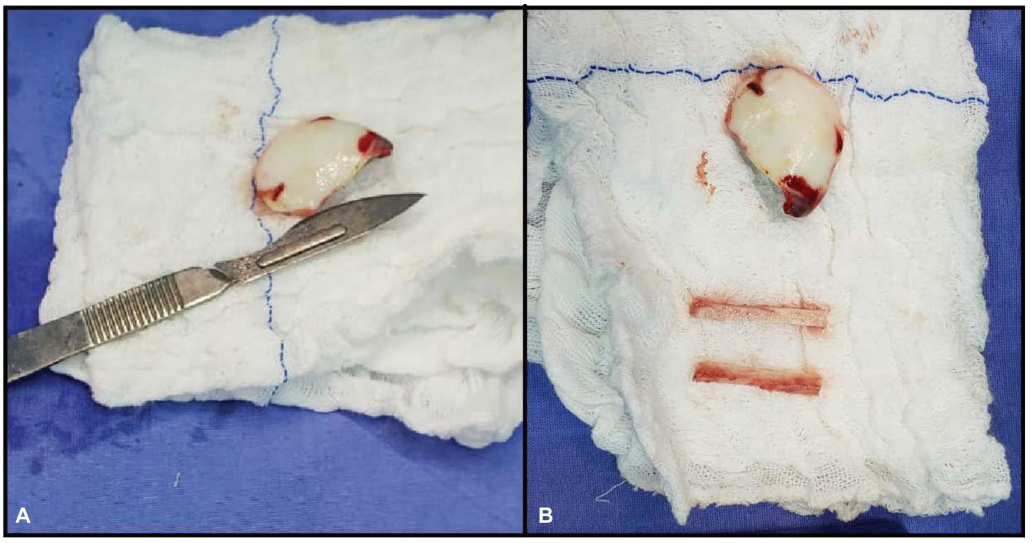

Fig. 2 Osteochondral fragments.

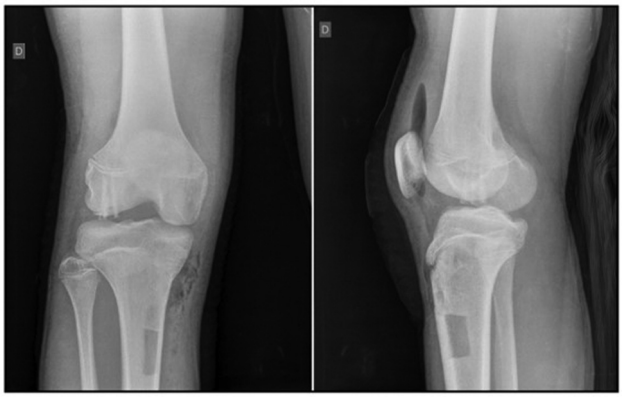

Fig. 3 Post operative X-ray



Fig. 4 Surgery image.

after surgery, he started motor physical therapy, walking with crutches and no support. We allowed partial loading at 2 months and full loading as tolerated at 4 months after surgery. The patient underwent periodical supplementary imaging exams confirming the good evolution and right knee recovery. At 4 months, the radiological examination demonstrated a proper bone consolidation of the fractured fragment (►**Fig. 5**).



Fig. 5 X-ray 4 months after the surgery.

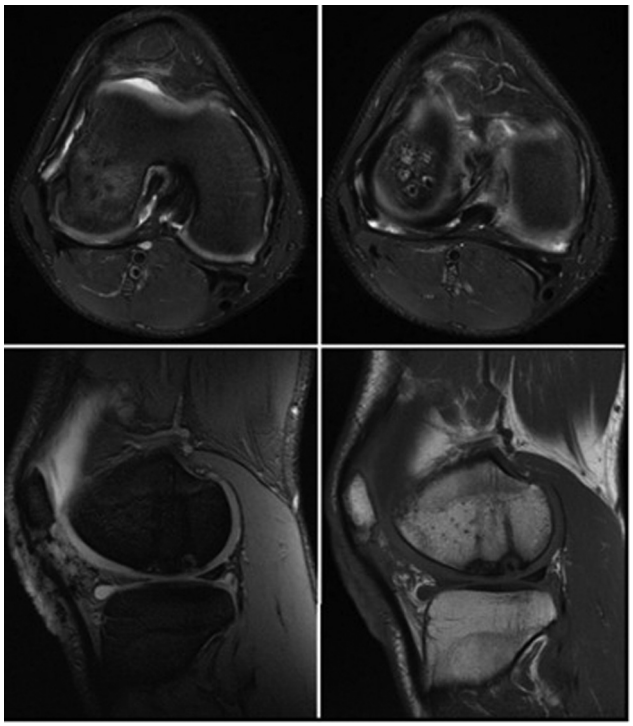

Fig. 6 Magnetic resonance 1 year and 2 months after the surgery.

The patient resumed his regular sports and impact activities 1 year and 2 months after surgery. A follow-up magnetic resonance imaging (MRI) scan demonstrated the good evolution of joint reconstruction (►**Fig. 6**).

Discussion

Osteochondral fractures of the lateral femoral condyle are infrequent.[3] Physical examination may reveal edema, movement limitation, and joint blockage. The investigation must begin with a plain radiography. Pure chondral injuries require other imaging tests, such as MRI and arthroscopy.[5]

After diagnosing an osteochondral fracture, the anatomy of the articular surface needs restoration to avoid early osteoarthrosis. The most common fixation technique employs metal screws. Despite being efficient and widely used, the screws have to be removed in a second surgical procedure. To overcome this issue, bioabsorbable synthetic materials have emerged for fragment fixation. However, these materials are not widespread and can generate a foreign body reaction.[4]

The fixation technique with bone sticks has already been used as a form of fixation in osteochondritis dissecans of the knee, and numerous studies have proven the good bone consolidation provided.[6,7] The sticks are made from cortical bone, usually from the tibia. The number of sticks used for fixation in osteochondritis dissecans is variable; some studies report an average of 3 to 4 sticks per lesion,[8] while others describe 4 to 6.[7]

In the present case report, we selected five rectangular bone sticks. The incompatibility between the circular hole and the square stick ensures a firmer fixation.[8] Bone sticks

can be described as autologous bone grafts. Thus, for fracture consolidation, they have osteoconductive and osteoinductive properties.[9]

The advantage of using bone sticks to fix osteochondral fragments in the knee is allowing fracture fixation in a single surgery with no risk of a foreign body reaction. Despite the short follow-up period and the lack of histological follow-up of the lesion, imaging tests, and the patient's complete physical rehabilitation demonstrate that fixation of the osteochondral fragment of the knee with bone sticks is an effective technique.

Financial Support
The authors did not receive any financial support from public, commercial, or not-for-profit sources.

Conflict of Interests
The authors declare no conflict of interests.

References

1 Armiento AR, Stoddart MJ, Alini M, Eglin D. Biomaterials for articular cartilage tissue engineering: Learning from biology. Acta Biomater 2018;65:1–20
2 Levy AS, Lohnes J, Sculley S, LeCroy M, Garrett W. Chondral delamination of the knee in soccer players. Am J Sports Med 1996;24(05):634–639
3 Walsh SJ, Boyle MJ, Morganti V. Large osteochondral fractures of the lateral femoral condyle in the adolescent: outcome of bioabsorbable pin fixation. J Bone Joint Surg Am 2008;90(07): 1473–1478
4 Nakayama H, Yoshiya S. Bone peg fixation of a large chondral fragment in the weight-bearing portion of the lateral femoral condyle in an adolescent: a case report. J Med Case Reports 2014; 8:316
5 Severino NR, Camargo OPA, Aihara T, et al. Comparação entre a ressonância magnética e a artroscopia no diagnóstico das lesões do joelho. Rev Bras Ortop 1997;32(04):275–278
6 Gillespie HS, Day B. Bone peg fixation in the treatment of osteochondritis dissecans of the knee joint. Clin Orthop Relat Res 1979;(143):125–130
7 Victoroff BN, Marcus RE, Deutsch A. Arthroscopic bone peg fixation in the treatment of osteochondritis dissecans in the knee. Arthroscopy 1996;12(04):506–509
8 Navarro R, Carneiro Filho M, Cohen M, Silva RT. Tratamento artroscópico da osteocondrite dissecante do joelho (OCDJ) por meio de "palitos ósseos" autólogos. Rev Bras Ortop 1997;32(12): 959–962
9 Finkemeier CG. Bone-grafting and bone-graft substitutes. J Bone Joint Surg Am 2002;84(03):454–464