Giant Baker Cyst Extending Up to the Gastrocnemius: A Case Report

Cisto de Baker gigante com extensão ao gastrocnêmio: Relato de caso

Adeel Ahmed Siddiqui[1] Muhammad Waqas Khan[1] Taimoor Ali[1] Sajjad Ahmed[1] Shahzaeb Solangi[1] Javeria Qamar[2]

[1] Orthopedic Surgery Department, Dr. Ruth K. M. Pfau Civil Hospital, Karachi, Pakistan
[2] Dow Medical University of Health Sciences, Karachi, Pakistan

Address for correspondence Muhammad Waqas Khan, MBBS, Orthopedics Department Unit II, Dr. Ruth K. M. Pfau Civil Hospital Karachi, Pakistan (e-mail: muhammadwaqad343@gmail.com).

Rev Bras Ortop 2024;59(S2):e141–e144.

Abstract

Baker cyst is an abnormal enlargement of the gastrocnemius-semimembranous bursa behind the knee joint due to an exit of joint fluid.

We herein report a rare case of giant Baker cyst in a rheumatic arthritic female patient. An MRI scan showed a complex, multiloculated cyst measuring 11.8 cm x 4.6 c, x 3.3 cm, arising from the left knee joint. Open surgical excision of the lesion was performed, and no recurrence was observed during the one-year follow up in the Rheumatology and Orthopedics Department.

A natural tendency towards intermuscular extension is observed; thus, intramuscular extensions are rarely reported in the literature. To the best of our knowledge, no Baker cyst of such size has been operated in a rheumatoid arthritis patient.

Keywords

- cyst
- gastrocnemius muscle
- osteoarthritis, knee
- synovial membrane

Resumo

O cisto de Baker é um aumento anormal da bursa gastrocnêmio-semimembranosa atrás da articulação do joelho devido ao efluxo de fluido articular.

Relatamos um caso raro de cisto de Baker gigante em uma paciente com artrite reumatoide. A ressonância magnética mostrou um cisto complexo e multiloculado que media 11,8 cm x 4,6 cm x 3,3 cm, com origem na articulação do joelho esquerdo. Foi realizada excisão cirúrgica aberta da lesão. Não houve recidiva durante o acompanhamento de um ano no Departamento de Reumatologia e Ortopedia.

Há uma tendência natural de extensão intermuscular, de modo que os relatos de extensões intramusculares são raros na literatura. Pelo que sabemos, nenhum cisto de Baker desse tamanho foi operado em pacientes com artrite reumatoide.

Palavras-chave

- cisto
- membrana sinovial
- músculo gastrocnêmio
- osteoartrite do joelho

Work carried out at the Orthopedic Surgery Department of Dr. Ruth K. M .Pfau Civil Hospital, Karachi, Pakistan.

received
February 26, 2023
accepted after revision
November 6, 2023

DOI https://doi.org/10.1055/s-0044-1787546.
ISSN 0102-3616.

© 2024. The Author(s).
This is an open access article published by Thieme under the terms of the Creative Commons Attribution 4.0 International License, permitting copying and reproduction so long as the original work is given appropriate credit (https://creativecommons.org/licenses/by/4.0/).

Thieme Revinter Publicações Ltda., Rua do Matoso 170, Rio de Janeiro, RJ, CEP 20270-135, Brazil

Introduction

Baker cyst, an abnormal growth of the gastrocnemius-semimembranous bursa caused by the leakage of fluid from the knee joint into the bursa, is one of the most prevalent cystic lesions around the knee joint.[1–4] It may happen by normal movement of the fluid or synovial membrane herniation through a weak posterior knee capsule, whose damage may result from any direct or indirect trauma.[2] The frequently affected areas are the inferomedial or superficial layers of the knee joint, rarely spreading laterally or proximally.[1,3] It is a common pathological finding on sonography of the popliteal fossa, and 4.7% to 19% of magnetic resonance imaging (MRI) scans of the posterior knee masses show Baker cyst.

Naturally, the bursa tends to expand along the intermuscular planes or the spaces between the muscle and the joint capsule. Intramuscular extensions are rarely reported in the international literature, and not at all in Pakistan. We herein report a case of ruptured Baker cyst with an intraoperative extension in the gastrocnemius (GC) muscle.

Case Report

A 35-year-old female patient with rheumatoid arthritis for past 5 years presented with a complaint of pain and swelling at the back of the left knee for 6 months. The pain was initially mild in intensity, aggravated by movement, and relieved with rest and analgesics. The swelling grew progressively, and the patient was initially managed with multiple aspirations in a local hospital, and negative fluid cultures were reported.

Upon examination, there was tender swelling measuring 10 cm x 5 cm at the left-sided popliteal fossa with intact, shiny overlying skin. The laboratory investigations included a complete blood profile, which showed a total leukocyte count (TLC) of 6.5×10^9/L, C-reactive protein of 82.0 mg/dL, and erythrocyte sedimentation rate of 33 mm/h.

A detailed report of the aspirated fluid indicated a yellowish turbid fluid with a specific gravity of 1.030, protein value of 4.48 g/dl, red blood cell (RBC) count of 4,500, and white blood cell (WBC) count of 28,480 microliters with 90% of polymorphonuclear (PMN) cells and 10% of mononuclear cells. The culture, however, showed no growth.

An ultrasound showed a bilobed, well-defined lesion to the hypoechoic area seen along the posterior aspect of the left knee, extending inferiorly up to the mid-alf and measuring 10.4 cm x3.5 cm. However, there was no evidence of vascularity on Doppler imaging. The popliteal vessels appeared unremarkable.

An MRI scan showed a complex, multiloculated cyst with an internal hemorrhagic component measuring 11.8 cm x4.6 cm x3.3 cm, arising from the posteromedial aspect of the left knee joint and extending inferiorly into the calf region, causing compression over the posterior muscular compartment. Its anteromedial margin appeared irregular. These were suggestive of a ruptured hemorrhagic Baker cyst. Mild to moderate joint effusion was noted as well (►**Fig. 1**).

After all aseptic measures, preparation and draping were performed, a longitudinal incision was made at the left popliteal fossa, and subcutaneous tissue was dissected. A sac-like structure was found intramuscularly between the two heads of the GC muscles; it was dissected from the underlying muscle fibers, and a cheese-like material leaked from the cyst. The wound was closed in layers after proper irrigation. An aseptic dressing was applied, and the resected cyst was submitted to a histopathological analysis (►**Fig. 2A–C**).

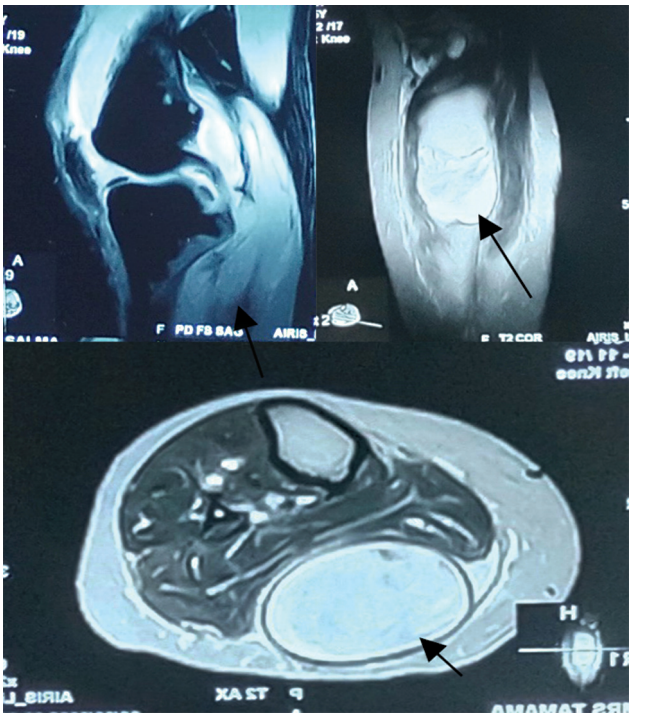

Fig. 1 Magnetic resonance imaging (MRI) scan of the knee joint sequences showing a complex, multiloculated cyst with an internal hemorrhagic component arising from the posteromedial aspect of the knee joint and extending inferiorly into the calf region, causing compression over the posterior muscular compartment (upper left: sagittal section; right: coronal view; and bottom: axial view); all sections are slices > 2 mm, and T2-weighted images are shown, with all arrows pointing toward lesions in different views.

Microscopically, the cystic tissue fragments had fibrous walls with no definitive lining. There was chronic inflammatory infiltrate dominated by plasma cells, lymphocytes, histiocytes, and hemosiderin-laden cells. Together with fibrin and palisading histiocytes, fibrinoid necrosis was also observed; however, there was no evidence of malignancy or granuloma.

A postoperative MRI scan with contrast showed complete excision of the lesion (►**Fig. 3**), and no complaints or recurrence were recorded in one year of follow up.

The present case report was approved by the institutional Review Board (ref: 04-2023); informed consent was obtained from the patient, and the purpose of the publication of the case report was briefed to patient.

Discussion

Baker cyst, also known as a secondary popliteal cyst, is usually asymptomatic and observed on MRI scans when investigating other knee problems. It may present as a

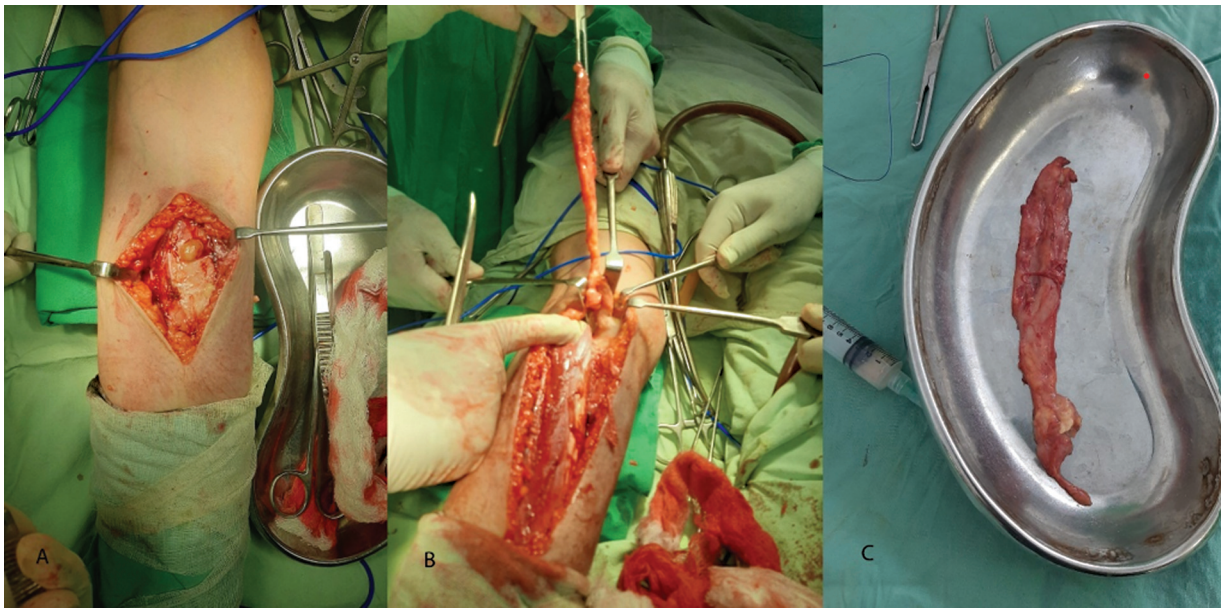

Fig. 2 (**A**,**B**) Longitudinal incision with cheese-like material coming out of the lesion, and the size of the excised cyst is compared to that of a standard kidney dish. One can appreciate excised cyst that was found intramuscularly in the gastrocnemius muscle. (**C**) Size comparison between the huge cyst and a standard kidney dish measuring 25 cm to 26 cm in length and 11 cm in width.

popliteal fossa mass, with or without pain, limited range of motion of the knee joint, and other compressive symptoms like thrombophlebitis, compartment syndrome, or entrapment neuropathy (either from the cyst or later, after its rupture).[4–7]

We found eight cases of Baker cysts extending into the vastus medialis and medial head of the GC.[1–4] Fang et al.,[1] in their case series, documented a Baker cyst that communicated to the joint via a narrow stalk between the GC and semimembranosus muscles and two additional cases of cysts within the GC muscle. In 2012, Kim et al.[2] reported a Baker cyst with intramuscular extension in the vastus medialis muscle through the weakened fascia, although there was no history of trauma. Moreover, the cyst was filled with hemorrhagic fluid.

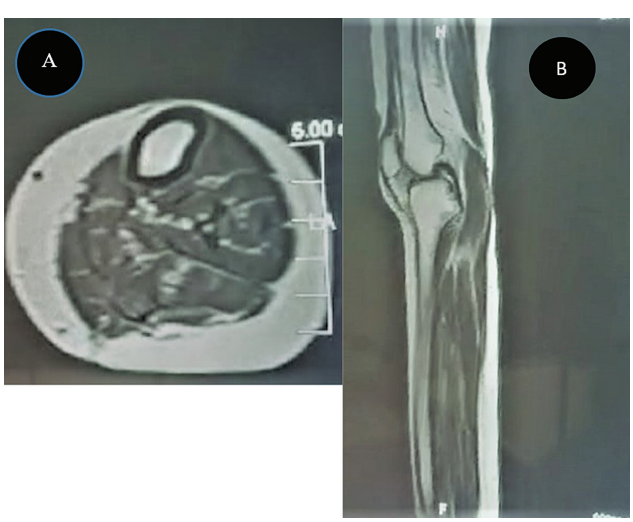

Fig. 3 Postoperative MRI scan with contrast after open resection of a giant Baker cyst. (**A**) Axial view with absence of the lesion observed the in preoperative axial view; and (**B**) sagittal view of the knee with no residual cyst present.

Two similar cases were published by Li et al.,[3] of two female patients who presented with knee pain and radiographic features of osteoarthritis. Effusion was detected via ultrasound, and later they were found to have Baker cyst extending into the medial head of the GC muscle.

Another intriguing case of posterior tibial neuropathy from a ruptured Baker cyst caused sole discomfort and paresthesia. Baker cyst is never examined in the differential diagnosis of individuals with calf and sole pain because it is rarely reported.[4]

The current case is that of a female who presented with no symptoms of neuropathy or compression. The diagnosis of ruptured hemorrhagic Baker cyst was made through an MRI scan, and later turned out to be extending intramuscularly and involving the GC muscle on imaging; however, intramuscular extension was not identified.

In the literature, various conservative and operative interventions are mentioned. Conservative treatment options include aspirations, corticosteroid therapy, and methotrexate (an alternative for patients who are at high risk for surgery) injection intra-articularly and in the cysts.[8] Bandinelli et al.[9] reported satisfactory outcomes with ultrasound-guided direct steroid injection into a cyst and intra-articular steroid injection in situations identical to these; both techniques were deemed effective. In cases involving osteoarthritis, Acebes et al.[10] reported positive outcomes after the cyst contents were aspirated and corticosteroids were injected. Our results favored open excision because our patient was symptomatic and had multiple aspirations.

Although rare, lesions like a Baker cyst, primarily when ruptured, can involve the muscles around and below the knee joint. Lesions like these should be thoroughly

investigated at the time of presentation rather than waiting for the appearance of compressive symptoms or neuropathy.

Authors' Contributions

Each author contributed individually and significantly to the development of the present article: AAS worked on the conception and design, while MWK, TA, and SA performed drafting, data collection, acquisition, analysis, and interpretation of data. JQ and SS played a role in critical revision and appraisal and contributed equally to all the tasks.

Financial Support

The authors declare that they have received no funding from agencies in the public, private, or non-profit sectors for the conduction of the present study.

Conflict of Interests

The authors have no conflict of interests to declare.

References

1 Fang CS, McCarthy CL, McNally EG. Intramuscular dissection of Baker's cysts: report on three cases. Skeletal Radiol 2004;33(06): 367–371

2 Kim TW, Suh JT, Son SM, et al. Baker's Cyst with Intramuscular Extension into Vastus Medialis Muscle. Knee Surg Relat Res 2012; 24(04):249–253

3 Li TY. A Case Study of Baker Cysts With Intramuscular Extension into the Medial Head of the Gastrocnemius. J Diagn Med Sonogr 2016;32(06):382–386

4 Moon SH, Im S, Park GY, et al. Compressive neuropathy of the posterior tibial nerve at the lower calf caused by a ruptured intramuscular baker cyst. Ann Rehabil Med 2013;37(04):577–581

5 Hamlet M, Galanopoulos I, Mahale A, Ashwood N. Ruptured Baker's cyst with compartment syndrome: an extremely unusual complication. BMJ Case Rep 2012;2012:bcr2012007901

6 Valle Alonso J, Fonseca del Pozo FJ, Van der Bergh E, Kinderman H. Infected Baker's cyst, diagnosed in the emergency department using POCUS. POCUS J 2019;4(01):6–8

7 Hung LP, Leung YF, Archie LB, Tony CKF. A Huge Infected Popliteal Cyst Dissecting into Gastrocnemius Mimicking Calf Abscess. J Orthop Trauma Rehabil 2015;19(02):107–110

8 Adiyeke L, Bılgın E, Duymus TM, Ketencı İE, Ugurlar M. Giant Baker's Cyst Associated with Rheumatoid Arthritis. Case Rep Orthop 2017;2017:4293104

9 Bandinelli F, Fedi R, Generini S, et al. Longitudinal ultrasound and clinical follow-up of Baker's cysts injection with steroids in knee osteoarthritis. Clin Rheumatol 2012;31(04):727–731

10 Acebes JC, Sánchez-Pernaute O, Díaz-Oca A, Herrero-Beaumont G. Ultrasonographic assessment of Baker's cysts after intra-articular corticosteroid injection in knee osteoarthritis. J Clin Ultrasound 2006;34(03):113–117