Retrospective Analysis of the Clinical and Radiological Outcomes Following Modified Dunn Osteotomy in Patients with Stable, Moderate-to-severe Chronic Slipped Capital Femoral Epiphysis

Análise retrospectiva dos desfechos clínicos e radiológicos após a osteotomia de Dunn modificada em pacientes com escorregamento epifisário proximal do fêmur estável, crônico e moderado a grave

Basant Kumar Bhuyan[1]

[1] Department of Orthopedics and Trauma, Faculty of Medicine, GMERS Medical College and General Hospital, Himmatnagar, Sabarkantha, Gujarat, India

Rev Bras Ortop 2024;59(6):e913–e921.

Address for correspondence Basant Kumar Bhuyan, MS, Department of Orthopedics and Trauma, Pediatric Orthopedics Division, Faculty of Medicine, GMERS Medical College and General Hospital, Himmatnagar, Sabarkantha, Gujarat, India (e-mail: drbasantkr@gmail.com).

Abstract

Objective The management of slipped capital femoral epiphysis (SCFE) has been completely transformed by modified Dunn osteotomy, a subcapital realignment osteotomy achieved through a safe surgical dislocation technique originally described by Ganz. The purpose of this study was to evaluate the clinical and radiological outcomes of patients with moderate to severe SCFE after modified Dunn osteotomy.

Methods A total of 15 patients (16 hips, with one bilateral case; 12 males, 3 females) aged from 10.2 to 17-years-old (mean: 14.3) with stable, moderate to severe, chronic SCFE (moderate = 6; severe = 10) underwent modified Dunn osteotomy as treatment. The hip joint range of motion (ROM), Harris (HHS), and Merle d'Aubigné (MdA) hip scores were used for clinical assessments. They were assessed radiographically using the Southwick and Alpha angles.

Results At the most recent follow-up (mean: 8.6 years, 3.1–14), the mean hip joint ROM, the mean HHS (preoperative: 69.20 ± 5.94; postoperative: 86 ± 7.37; $p < 0.00001$), and the mean MdA score (preoperative: 12.47 ± 1.13; postoperative: 14.27 ± 1.83; $p < 0.00001$) all showed statistically significant clinical improvements. The radiological results demonstrated improvements in the mean Southwick angle (preoperative: $56.60 \pm 12.89°$; postoperative: $16.4 \pm 4.69°$; $p < 0.00001$), and the Alpha angle (preoperative: $101.87 \pm 12.88°$;

Keywords
- hip
- osteonecrosis
- osteotomy
- slipped capital femoral epiphysis

Work carried out at the Department of Orthopedics and Trauma, GMERS Medical College and General Hospital, Himmatnagar, Sabarkantha, Gujarat, India.

received
March 12, 2024
accepted
May 21, 2024

DOI https://doi.org/10.1055/s-0044-1788672.
ISSN 0102-3616.

© 2024. The Author(s).
This is an open access article published by Thieme under the terms of the Creative Commons Attribution 4.0 International License, permitting copying and reproduction so long as the original work is given appropriate credit (https://creativecommons.org/licenses/by/4.0/).

Thieme Revinter Publicações Ltda., Rua do Matoso 170, Rio de Janeiro, RJ, CEP 20270-135, Brazil

postoperative: 29.33 ± 7.29°; $p < 0.00001$). There were two significant postoperative complications identified: femoral head avascular necrosis (AVN) and deep infection.

Conclusion According to the study's findings, the modified Dunn osteotomy is a safe, efficient treatment option for stable moderate-to-severe chronic SCFE with a manageable risk of complications.

Resumo

Objetivo O manejo do escorregamento epifisário proximal do fêmur (EEPF) foi completamente transformado pela osteotomia de Dunn modificada, uma osteotomia de realinhamento subcapital por meio da técnica segura de luxação cirúrgica originalmente descrita por Ganz. O objetivo deste estudo foi avaliar os desfechos clínicos e radiológicos de pacientes com EEPF moderado a grave após a osteotomia de Dunn modificada.

Métodos Um total de 15 pacientes (16 quadris, com um caso bilateral; 12 homens, 3 mulheres) com idade entre 10,2 e 17 anos (média: 14,3) e EEPF crônico, estável e moderado a grave (moderado = 6; grave = 10) foram submetidos à osteotomia de Dunn modificada como tratamento. A amplitude de movimento (ADM) da articulação do quadril e os escores de quadril de Harris (HHS) e Merle d'Aubigné (MdA) foram utilizados para avaliações clínicas. A avaliação radiográfica usou os ângulos de Southwick e alfa.

Resultados No acompanhamento mais recente (média: 8,6 anos; 3,1–14), a média da ADM da articulação do quadril, o HHS médio (pré-operatório: 69,20 ± 5,94; pós-operatório: 86 ± 7,37, $p < 0,00001$) e o MdA médio (pré-operatório: 12,47 ± 1,13; pós-operatório: 14,27 ± 1,83, $p < 0,00001$) demonstraram melhoras clínicas estatisticamente significativas. Os resultados radiológicos demonstraram melhoras no ângulo Southwick médio (pré-operatório: 56,60 ± 12,89°; pós-operatório: 16,4 ± 4,69°, $p < 0,00001$) e no ângulo alfa (pré-operatório: 101,87 ± 12,88°; pós-operatório: 29,33 ± 7,29°, $p < 0,00001$). Foram observadas duas complicações pós-operatórias significativas: necrose avascular (NAV) da cabeça femoral e infecção profunda.

Conclusão De acordo com os achados do estudo, a osteotomia de Dunn modificada é uma opção terapêutica segura e eficaz no EEPF estável, crônico e moderado a grave, com risco controlável de complicações.

Palavras-chave
- escorregamento das epífises proximais do femur
- osteonecrose
- osteotomia
- quadril

Introduction

Slipped capital femoral epiphysis (SCFE) is a well-known debilitating hip condition in children and young adults with a global incidence ranging from 0.33 to 24.58 per 100,000 people between the ages of 8 and 15 years, depending on gender and ethnicity.[1] Proximal femoral deformity in SCFE results from the migration and displacement of the capital femoral epiphysis from the metaphysis through the physeal plate in a postero-inferior direction.

According to the length of symptoms, the stability of the slip and the magnitude of the slip three distinct classification systems are universally accepted. The severity of SCFE can be classified as acute (lasting less than 3 weeks), chronic (more than 3 weeks), or acute and chronic (more than 3 weeks with exacerbation of symptoms).[2] Based on its capacity to support weight with or without assistance, the classification categorizes SCFE into stable and unstable types.[3] By using the Southwick method which splits the slip angle into mild (< 30°), moderate (30–60°), and severe (> 60°) degrees to measure the radiological magnitude of the slip.[4]

The primary objectives of treating SCFE are preventing additional slip progression, stabilizing and reinstating hip function, preventing early hip osteoarthritis (OA), and reducing the risk of avascular necrosis (AVN). There has been discussion about the best course of treatment for SCFE, but disagreements still persist between conventional in situ pinning and more aggressive reconstructive procedures. Femoroacetabular impingement (FAI) is the result of an aberrant head–neck offset in moderate to severe cases of SCFE after in situ pinning, where the hip remains malformed despite some remodelling.[5] Furthermore, it is the primary cause of mechanical derangement of the hip joint, which results in cartilage damage and labral damage, predisposing to the early development of secondary hip OA.[6]

A number of distinct realignment osteotomy techniques have been reported at the subcapital, basicervical, intertrochanteric, and subtrochanteric levels to enhance the long-term

prognosis of patients with SCFE.[7–11] The Dunn procedure, a realignment osteotomy carried out at the sub-capital level, offers the greatest amount of correction. However, it carries a possible risk of AVN that may be caused by iatrogenic damage to the blood supply of the proximal femoral epiphysis. For the treatment of SCFE, Leunig et al.[12] invented subcapital osteotomy, by using a safe surgical hip dislocation approach developed by Ganz et al.[13] The capital femoral head vascularity is preserved by this modified Dunn osteotomy, which enables the identification and preservation of the retinacular vessels through meticulous preparation of an extended retinacular flap.[13] The purpose of this study was to assess the clinical and radiological results and complications of patients treated for stable, moderate to severe, chronic SCFE with this procedure, and to compare these findings with those of similar published series.

Materials and Methods

The present work was approved by the institutional committee under the Independent Ethics Committee (IEC) number /49/01/09/2023.

All teenage patients with stable, moderate-to-severe, chronic SCFE and open physis who presented between January 2010 and December 2020 were included in this retrospective case series. The exclusion criteria were acute, acute on chronic, or unstable SCFE, as well as other related congenital or acquired hip deformities, and any history of previous hip surgery. The index procedure was carried out with the full informed written consent of all parents.

The modified Dunn osteotomy procedure was performed using the operative technique outlined by Leunig et al.[12] Following a trochanteric flip osteotomy and Z-shaped capsulotomy, the hip joint was exposed through the Gibson interval (►**Fig. 1a** and **b**). After the ligamentum teres was excised and the femoral epiphysis was temporarily fixed with K-wires, safe surgical dislocation of the hip was carried out. The stable portion of the greater trochanter was carefully trimmed on its posterior and superior aspects to the size of the femoral neck, and an extended retinacular soft tissue flap was created, housing the retinacular vessels up to the capital femoral epiphysis. A cautious and controlled mobilization of the epiphysis was attempted following resection of the posteromedial metaphyseal callus. After careful femoral neck trimming, which did not strain the vessels, a capital realignment was performed (►**Fig. 1c** and **d**). Femoral head perfusion was evaluated both during surgical dislocation and following a capital realignment procedure (►**Video 1**). There were two 6.5-mm partially threaded cannulated screws used to

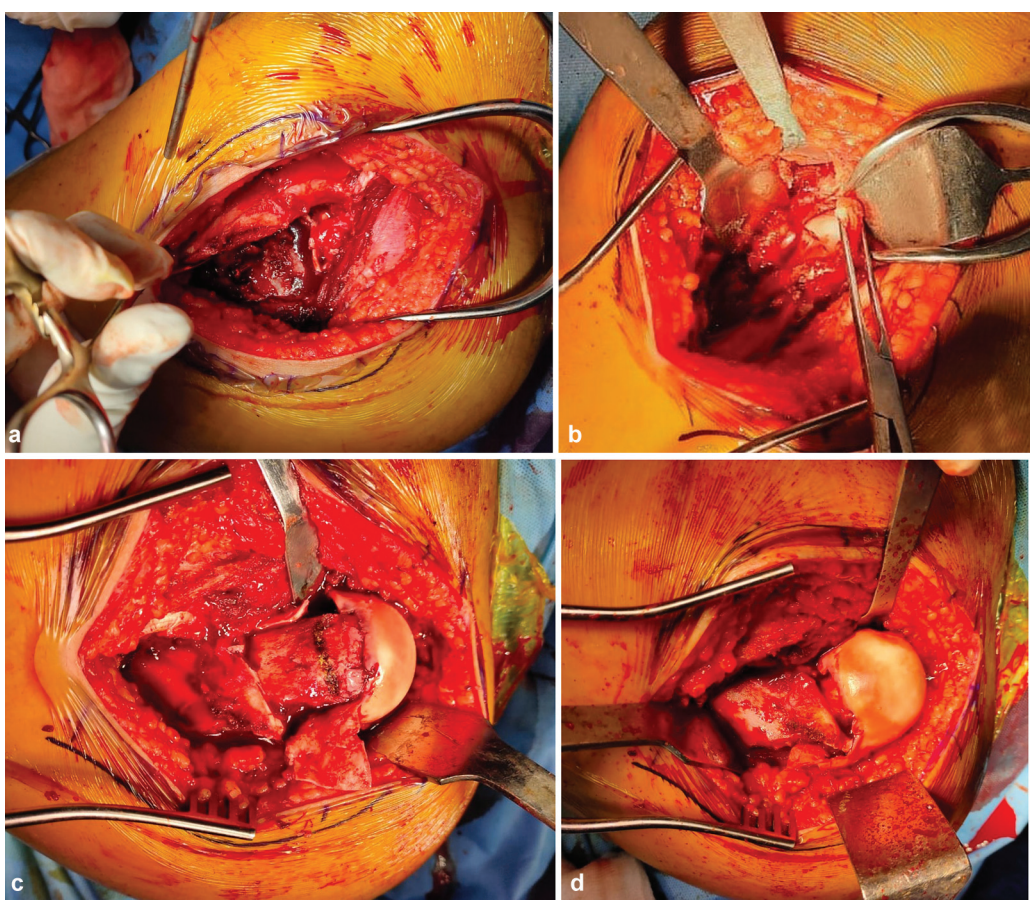

Fig. 1 Hip joint is exposed through (**a**) trochanteric osteotomy (**b**) capsulotomy. (**c**) Subcapital osteotomy area is marked. (**d**) Subcapital realignment without tension.

precisely fix the epiphysis, and two 4 mm cannulated cancellous screws used to reattach the osteotomized greater trochanter.

Video 1

Evaluation of epiphyseal perfusion after capital realignment osteotomy. Online content including video sequences viewable at: https://www.thieme-connect.com/products/ejournals/html/10.1055/s-0044-1788672.

Information was gathered from the hospital medical records database about demographics, clinical characteristics, surgical technique, intraoperative findings, type of fixation, postoperative follow-up, and complications. The range of motion (ROM) of the hip joint, encompassing internal and external rotation with 90° of hip flexion, was measured for both preoperative and postoperative functional assessments. Using questionnaires based on the Harris (HHS) and Merle d'Aubigné (MdA) hip scores, subjective outcomes were evaluated.[14,15] Anteroposterior pelvis and Lauenstein frog-leg lateral view radiographs are used in radiological evaluation to measure the Southwick slip angle and Alpha angle.[4,16] These values were computed and compared to the preoperative values.

Statistical Analysis

The means and standard deviations were used to represent the values of the radiographic measurements and the clinical assessment scores on the various scales. The pre- and postoperative values were compared using paired *t* tests. A *p*-value lower than 0.05 was considered statistically significant. The Statistical Package for Social Science (SPSS, IBM Corp., New York, USA), version 27.0 for Microsoft Windows, was used for statistical analysis.

Results

The data of 15 patients (16 hips) with an average age of 14.3 ± 1.8 (range, 10.2–17) years at the time of surgery were retrospectively reviewed. Of these, 12 (80%) were male and 3 (20%) were female. The age distribution was of 12.5 ± 1.6 (7–17) years for the male patients and 10.8 ± 1.3 (9–13) for the females. Every slip met the stable variety classification criteria established by Loder and the chronicity criteria established by Fahey and O'Brien. According to the Southwick classification of slip angle, 10 hips (62.5%) had a severe degree of slip, with a mean slip angle of $66.1 \pm 13.9°$ (61–76°), and 6 hips (37.5%) had a moderate degree of slip, with a mean slip angle of $42.3 \pm 6.3°$ (39–45°). There were 9 affected hips (56.2%) on the right side and 7 (43.7%) on the left side, with one patient with bilateral involvement.

►**Table 1** displays the patients' demographic and clinical information, such as their stability, degree of Southwick's slip angle, and chronicity of symptoms.

A mean follow-up period of 8.6 (3.1–14) years was observed for all patients. The hip ROM at the final follow-up significantly improved with respect to mean hip flexion, internal (IR) and external (ER) rotation in 90° of flexion. After surgery, the average flexion angle was $91 \pm 17.24°$ (65–120°), the average IR angle was $28 \pm 6.5°$ (15–30°), and the average ER angle was $27.3 \pm 5.3°$ (20–35°).

Table 1 Patient characteristics

Case nr.	Gender	Age (years)	Side	Duration (weeks)	Fahey and O'Brien Classification	Loder classification	Southwick classification	Follow-up (years)
1	Male	10.2	Left	4	Chronic	Stable	Moderate	14
2	Male	15.3	Both	12	Chronic	Stable	Severe	13.2
3	Male	14.5	Right	9	Chronic	Stable	Severe	12.4
4	Female	11.8	Left	8	Chronic	Stable	Severe	11.7
5	Male	14.6	Right	6	Chronic	Stable	Moderate	11
6	Male	15.7	Right	10	Chronic	Stable	Severe	10.5
7	Male	17	Left	8	Chronic	Stable	Severe	9.7
8	Female	12.8	Right	9	Chronic	Stable	Severe	9
9	Male	13.6	Right	4	Chronic	Stable	Moderate	8.1
10	Male	14.4	Left	5	Chronic	Stable	Moderate	7.2
11	Male	16	Right	6	Chronic	Stable	Severe	6
12	Female	13.6	Left	4	Chronic	Stable	Moderate	5.6
13	Male	15	Right	11	Chronic	Stable	Severe	4.2
14	Male	14.7	Right	5	Chronic	Stable	Moderate	3.9
15	Male	16.2	Left	12	Chronic	Stable	Severe	3.1

According to the HHS evaluation results, 4 patients had excellent clinical outcomes ($\geq$ 90 points), 7 good (80–90), and one each had a fair (70–80) and poor ($<$ 70) outcome. Preoperatively, the average HHS was 69.2 ± 5.9 (61–78); postoperatively, it improved to 86 ± 7.3 (75–95), with $p < 0.00001$.

The postoperative MdA score were rated as good (15–17) in 8 patients, fair (13 or 14) in 6, and poor ($<$13) in 2 patients. At the most recent follow-up, the mean MdA score improved from 12.47 ± 1.13 (11–14) points preoperatively to 14.27 ± 1.83 (10–17) postoperatively, with $p < 0.00001$.

The radiographic anatomy of the proximal femur improved in every patient after the modified Dunn osteotomy procedure. Between the pre- and postoperative periods, the mean Southwick slip angle improved from $56.60 \pm 12.86°$ (39–76°) to $16.40 \pm 4.69°$ (5–25°), with $p < 0.00001$. Similarly, the mean Alpha angle improved from $101.87 \pm 12.88°$ (85–125°) to $29.33 \pm 7.29°$ (20–40°), with $p < 0.00001$. Patient No.10 (►**Fig. 2a–f**) had good to excellent radiographic and clinical outcomes.

►**Table 2** summarizes the clinical and radiological parameter evaluations performed both prior to surgery and at the most recent follow-up visit.

Deep infection and AVN of the femoral head were the two main postoperative complications. A deep infection that was eventually treated with debridement and exploration resulted in a stiff hip joint. A patient who had bilateral severe SCFE and hypothyroidism experienced a poor outcome after developing AVN of the left hip joint and partial femoral head collapse 12 weeks after surgery (►**Fig. 3a** and **b**). He was counselled to schedule routine check-ups and THR following skeletal maturity. No other patients had any records of chondrolysis, heterotopic ossification (HO), implant failure, FAI symptoms, or early OA following surgery.

Discussion

The natural history of SCFE has shown that as the degree of slip increases, there is a noticeable and progressive deterioration of the hip joint.[17] The FAI results from altered proximal femoral anatomy caused by anterolateral metaphyseal prominence. This has been linked to chondrolabral damage, reduced ROM, increased hip pain, and early hip OA.[18]

Significant advancements in surgical techniques have occurred over time, and more aggressive joint reconstructive procedures have recently emerged to preserve femoral head vascularity in SCFE while offering greater anatomic correction of the deformity. Restoring normal hip function while addressing residual metaphyseal deformity and physeal stability has been reported to be a potential positive outcome of the modified Dunn osteotomy.

This procedure was first described by Leunig et al. using a safe surgical dislocation technique that allowed for ongoing intraoperative monitoring of the epiphyseal blood supply. All 30 patients had successful anatomical reduction and no AVN of the femoral head, according to their positive reports.[19]

Ziebarth et al.[20] followed 40 patients from two institutions with moderate to severe SCFE for 1 or 3 years. With a modified Dunn procedure, they were able to replicate the 0% rate of AVN or chondrolysis and reported a good success rate.

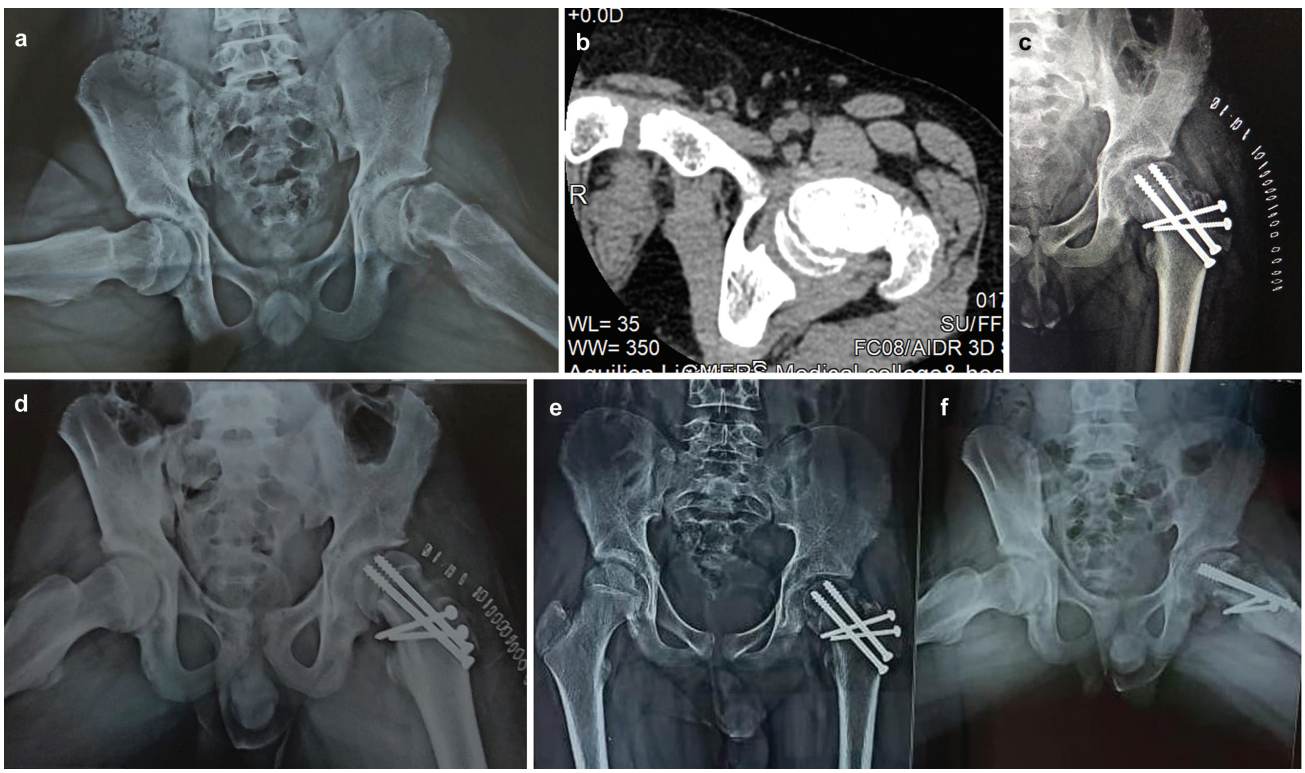

Fig. 2 (**a**) Preoperative radiograph of the 14.4-year-old boy's frog leg; lateral view demonstrating moderate degree slip on the left hip. (**b**) Axial CT image showing displacement of capital femoral epiphysis. (**c–d**) Anteroposterior and frog leg lateral view immediately after surgery. (**e–f**) Anteroposterior and frog leg lateral view radiographs taken 4.3 years after a modified Dunn osteotomy.

Table 2 Clinical and radiographic outcomes

Parameter	Preoperative (mean)	Postoperative (mean)	Mean correction	*p*-value	*t*-value	Complications
Clinical results						AVN ($n = 1$), deep infection ($n = 1$)
ROM						
Flexion	61.67	91.00	29.33	< 0.00001	15.59	
ER in flexion	52.67	27.33	25.34	< 0.00001	12.42	
IR in flexion	0	28.00	28	< 0.00001	16.7	
HHS	69.20	86	16.8	< 0.00001	19.85	
MdA score	12.47	14.27	1.8	< 0.00001	6.87	
Radiographic results						
Southwick slip angle	56.60	16.40	40.2	< 0.00001	-15.07	
Alpha angle	101.87	29.33	72.54	< 0.00001	-36.1	

Abbreviations: ER, external rotation; HHS, Harris hip score; IR, internal rotation; MdA, Merle d' Aubignè score; ROM, range of motion.

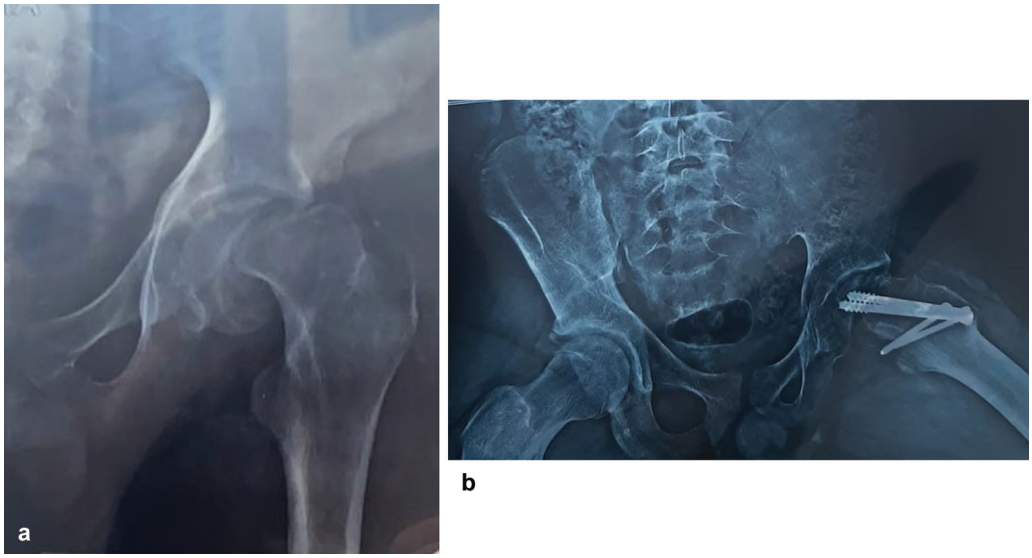

Fig. 3 (**a**) Anteroposterior view radiograph of a 15.3-year-old boy with severe SCFE on the left side taken prior to surgery. (**b**) Following a modified Dunn osteotomy, a 2.5-year follow-up radiograph revealed signs of AVN left hip joint.

Using a modified Dunn procedure, Madan et al.[21] reported the treatment of 28 patients with severe SCFE. The mean modified HHS at the final follow-up (mean: 38.6 months), was 89.1, and the mean nonarthritic hip score (NAHS) was 91.3. At the final follow-up, the lateral slip angle was corrected by a mean of 50.9°, and the ROM was almost normal. Furthermore, two patients had AVN that was proven to have existed beforehand, and another two acquired it after surgery. Nonunion, implant failure, infection, DVT, or HO were not observed in any of the patients.

Among the 43 SCFE patients treated by Upasani et al.,[22] 37 (86%) experienced severe slip; 16 (37%) experienced 22 complications; 10 (23%) experienced AVN of the femoral head; 4 (9%) experienced femoral neck nonunion necessitating revision surgery; and 2 (5%) experienced hip dislocation following surgery.

Abdelazeem et al.[23] conducted a prospective study after the modified Dunn procedure on 31 patients (32 hips) with moderate to severe SCFE. Following treatment, all clinical and radiological measurements showed a significant improvement at a mean follow-up of 24.1 months. Major complications following surgery included one case of postoperative AVN with complete femoral head collapse and arthritis, as well as one case of deep infection.

A prospective case series with 30 patients (32 hips) with stable chronic SCFE was reported by Elmarghany et al.[24] A total of 30 hips (94%) had good and excellent clinical and radiographic outcomes over a mean follow-up period of 14.5 months with regard to radiographic parameters and hip function. However, 3 patients experienced postoperative AVN, 1 experienced a poor reduction that required revision, and 1 experienced a postoperative deep infection. Their clinical outcome results ranged from fair to poor.

A modified Dunn procedure was used by Lerch et al.[25] to treat 46 patients (46 hips) with severe SCFE. Of that total, 2 hips (5%) experienced AVN of the femoral head, requiring

Table 3 Comparison of the included studies data and outcomes

Author (year)	Number of hips	Type of SCFE (moderate/severe)	Length of follow-up (years)	Postoperative clinical results	Postoperative radiological results	AVN of femoral head	Complications
Ziebarth et al.[20] (2009)	40	16/19 (5 Hips - no information)	2.6	HHS: 99.6 WOMAC: 1.2 (pain), 3 (function) MdA: 17.8	Slip angle:8.6 ° Alpha angle: 40.6°	0%	HO: 2.5% Residual impingement: 2.5% Delayed union: 7.5% Implant failure: 7.5%
Madan et al.[21] (2013)	28	0/28	3.2	Modified HHS: 89.1 NAHS: 91.3	Slip angle: 8°	7.1%	Condrolysis: 3.6%
Upasani et al.[22] (2014)	43	6/37	2.6	Dindo-Clavien classification Grading: I - 4.6% II - 6.9% III - 34.5% IV - 4.6%	–	23%	Femoral neck nonunion: 9% Hip dislocation: 5%
Abdelazeem et al.[23] (2016)	32	10/22	2Y	HHS: 96.3 WOMAC: 97 MdA: 16.7	Slip angle: 12.2° Alpha angle: 46.9°	3.1%	Deep infection: 3.1%
Elmarghany et al.[24] (2017)	32	11/21	1.2	HHS: 96.2 WOMAC: 3.3 MdA: 16.8 Heyman and Herdon outcome: excellent or good - 93.7%	Slip angle: 5.6° Alpha angle: 51.1°	9.3%	Deep infection: 3% Revision: 3%
Lerch et al.[25] (2019)	46	0/46	9	HHS: 94 MdA: 17 HOOS: 91	Slip angle: 7°	5%	OA: 2%, Implant failure: 7%
Ebert et al.[26] (2019)	15	0/15	3.8	HHS: 85.7 NHP: 0.91 VAS: 1.6	–	26.6%	Hip subluxation: 13.3% Implant failure: 13.3%
Zuo et al.[27] (2020)	21	0/21	2.7	HHS: 96.7 WOMAC: 95.4	Slip angle: 7.5° alpha angle: 42°	0%	Implant failure: 5%
Agashe et al.[28] (2020)	30	20/10	2.1	HHS: 81.8	Slip angle: 9.9° Alpha angle: 33.6°	6.6%	Hip subluxation: 3.3%
Present series	16	6/10	8.6	HHS: 86 MdA: 14.2	Slip angle: 16.4° Alpha angle: 29.3°	6.2%	Deep infection: 6.2%

Abbreviations: AVN, avascular necrosis; HHS, Harris hip score; HO, heterotopic ossification; HOOS, hip disability and osteoarthritis outcome score; MdA, Merle d'Aubignè score; NAHS, nonarthritic hip score; NHP, Nottingham health profile; VAS, visual analogue scale; WOMAC, Western Ontario and McMaster Universities arthritis index.

additional surgery; 3 (7%) experienced implant revision; and 1 (2%) experienced OA progression. At the 10-year follow-up, the cumulative survival rate was 86%.

Ebert et al.[26] used a modified Dunn procedure to treat 15 patients who had severe slip SCFE. Within that total, 8 patients achieved good results at a mean follow-up of 3.8 years, according to both clinical and functional outcome analysis (HHS >80). In 10 patients, the Nottingham health profile (NHP) measured quality of life, which was deemed good. There was AVN occurrence in 4 (26%) of the 15 patients.

Zuo et al.[27] evaluated the results of 20 patients (21 hips) with severe SCFE in retrospect. From that total, 19 patients showed excellent clinical and radiographic outcomes in terms of hip function and radiographic parameters at a mean follow-up of 31.2 months. However, 1 patient (5%) developed an implant failure experienced a poor outcome. There were no cases of AVN, FAI, OA, growth plate closure, HO, trochanteric nonunion, or disparity in limb length noted.

Using a modified Dunn technique, Agashe et al.[28] treated 30 consecutive hips with moderate and severe SCFE. The HHS mean follow-up functional outcome at 25.36 months indicated that all the operated hips had nearly normal ROMs, with results being excellent in 6 patients, good in 17, fair in 6, and poor in 1 patient. Furthermore, one hip experienced postoperative subluxation, which was rectified through revision surgery, while 2 hips (6.6%) developed AVN.

►**Table 3** lists the studies' references, along with the number of cases, classifications, duration of follow-up, postoperative clinical and radiological outcomes, incidence of AVN, and other complications.

The number of patients in this study who were treated with the modified Dunn osteotomy procedure for moderate to severe SCFE was similar to the number reported in the literature. At the most recent follow-up, two complications were found (AVN, deep infection), along with notable improvements in ROM, mean HHS, and mean MdA. According to these findings, a modified Dunn osteotomy technique can be used to realign SCFE with an open physis and a low risk of complications.

For the treatment of moderate to severe forms of SCFE, modified Dunn osteotomy is a safe and reliable surgical technique that should be strongly considered. With a manageable complication rate, this procedure can restore the proximal femoral anatomy by addressing the slip angle and head-neck offset, helping to maintain normal hip function.[29]

This study's strengths include the use of a well-defined patient population with moderate to severe SCFE and postoperative functional and radiological assessment results that are positively correlated with successful long-term results. This study has several limitations, such as its small sample size, retrospective single cohort study design, potential selection bias due to lack of randomization, and noncomparative design without a control group.

Conclusion

The modified Dunn osteotomy, by meticulously preserving the posterior retinacular soft tissue flap, aids in the anatomical realignment of a displaced capital femoral epiphysis while maintaining femoral head perfusion. The successful execution of this intricate reconstructive procedure with favorable long-term results requires a precise understanding of the hip's vascular anatomy and a thorough understanding of the surgical technique.

Financial Support
The author declares that the present study did not receive any financial support from public, commercial, or not-for-profit sources.

Conflict of Interests
The author has no conflict of interests to declare.

Acknowledgment
The author thanks Dr. Chetan Prajapati and Dr. Shipra Samanta for their assistance with statistical analysis and linguistic support for this study.

References

1 Loder RT, Skopelja EN. The epidemiology and demographics of slipped capital femoral epiphysis. ISRN Orthop 2011; 2011:486512
2 Fahey JJ, O'Brien ET. Acute slipped capital femoral epiphysis: Review of the literature and report of ten cases. J Bone Joint Surg Am 1965;47:1105–1127
3 Loder RT, Richards BS, Shapiro PS, Reznick LR, Aronson DD. Acute slipped capital femoral epiphysis: the importance of physeal stability. J Bone Joint Surg Am 1993;75(08):1134–1140
4 Southwick WO. Osteotomy through the lesser trochanter for slipped capital femoral epiphysis. J Bone Joint Surg Am 1967;49 (05):807–835
5 Galletta C, Aprato A, Giachino M, et al. Modified Dunn procedure versus percutaneous pinning in moderate/severe stable slipped capital femoral epiphyses. Hip Int 2022;32(06):813–819
6 Jones CE, Cooper AP, Doucette J, et al. Relationships Between Severity of Deformity and Impingement in Slipped Capital Femoral Epiphysis. J Pediatr Orthop 2017;37(04):272–278
7 Dunn DM, Angel JC. Replacement of the femoral head by open operation in severe adolescent slipping of the upper femoral epiphysis. J Bone Joint Surg Br 1978;60-B(03):394–403
8 Fish JB. Cuneiform osteotomy of the femoral neck in the treatment of slipped capital femoral epiphysis. J Bone Joint Surg Am 1984;66 (08):1153–1168
9 Abraham E, Garst J, Barmada R. Treatment of moderate to severe slipped capital femoral epiphysis with extracapsular base-of-neck osteotomy. J Pediatr Orthop 1993;13(03):294–302
10 Kramer WG, Craig WA, Noel S. Compensating osteotomy at the base of the femoral neck for slipped capital femoral epiphysis. J Bone Joint Surg Am 1976;58(06):796–800
11 Imhäuser G. [Late results of Imhäuser's osteotomy for slipped capital femoral epiphysis (author's transl)]. Z Orthop Ihre Grenzgeb 1977;115(05):716–725
12 Ganz R, Huff TW, Leunig M. Extended retinacular soft-tissue flap for intra-articular hip surgery: surgical technique, indications, and results of application. Instr Course Lect 2009;58:241–255
13 Leunig M, Slongo T, Ganz R. Subcapital realignment in slipped capital femoral epiphysis: surgical hip dislocation and trimming of the stable trochanter to protect the perfusion of the epiphysis. Instr Course Lect 2008;57:499–507
14 Harris WH. Traumatic arthritis of the hip after dislocation and acetabular fractures: treatment by mold arthroplasty. An end-result study using a new method of result evaluation. J Bone Joint Surg Am 1969;51(04):737–755

15 D'Aubigne RM, Postel M. Functional results of hip arthroplasty with acrylic prosthesis. J Bone Joint Surg Am 1954;36-A(03): 451–475
16 Nötzli HP, Wyss TF, Stoecklin CH, Schmid MR, Treiber K, Hodler J. The contour of the femoral head-neck junction as a predictor for the risk of anterior impingement. J Bone Joint Surg Br 2002;84 (04):556–560
17 Mathew SE, Larson AN. Natural History of Slipped Capital Femoral Epiphysis. J Pediatr Orthop 2019;39(6, Supplement 1 Suppl 1) S23–S27
18 Rab GT. The geometry of slipped capital femoral epiphysis: implications for movement, impingement, and corrective osteotomy. J Pediatr Orthop 1999;19(04):419–424
19 Leunig M, Slongo T, Kleinschmidt M, Ganz R. Subcapital correction osteotomy in slipped capital femoral epiphysis by means of surgical hip dislocation. Oper Orthop Traumatol 2007;19(04):389–410
20 Ziebarth K, Zilkens C, Spencer S, Leunig M, Ganz R, Kim YJ. Capital realignment for moderate and severe SCFE using a modified Dunn procedure. Clin Orthop Relat Res 2009;467(03):704–716
21 Madan SS, Cooper AP, Davies AG, Fernandes JA. The treatment of severe slipped capital femoral epiphysis via the Ganz surgical dislocation and anatomical reduction: a prospective study. Bone Joint J 2013;95-B(03):424–429
22 Upasani VV, Matheney TH, Spencer SA, Kim YJ, Millis MB, Kasser JR. Complications after modified Dunn osteotomy for the treatment of adolescent slipped capital femoral epiphysis. J Pediatr Orthop 2014;34(07):661–667
23 Abdelazeem AH, Beder FK, Abdel Karim MM, Abdelazeem H, Abdel-Ghani H. The anatomical reduction of a moderate or severe stable slipped capital femoral epiphysis by modified Dunn subcapital osteotomy using the Ganz approach: functional and radiological outcomes. Bone Joint J 2016;98-B(09):1283–1288
24 Elmarghany M, Abd El-Ghaffar TM, Seddik M, et al. Surgical hip dislocation in treatment of slipped capital femoral epiphysis. SICOT J 2017;3:10
25 Lerch TD, Vuilleumier S, Schmaranzer F, et al. Patients with severe slipped capital femoral epiphysis treated by the modified Dunn procedure have low rates of avascular necrosis, good outcomes, and little osteoarthritis at long-term follow-up. Bone Joint J 2019; 101-B(04):403–414
26 Ebert N, Rupprecht M, Stuecker R, et al. Outcome of the modified Dunn procedure in severe chronic or acute on chronic slipped capital femoral epiphysis. J Orthop Surg Res 2019;14(01):349
27 Zuo B, Zhu JF, Wang XY, Wang CL, Ma F, Chen XD. Outcome of the modified Dunn procedure in severe slipped capital femoral epiphysis. J Orthop Surg Res 2020;15(01):506
28 Agashe MV, Pinto DA, Vaidya S. Modified Dunn Osteotomy for Moderate and Severe Slipped Capital Femoral Epiphysis - A retrospective study of thirty hips. Indian J Orthop 2020;55(01): 100–108
29 Gorgolini G, Caterini A, Efremov K, et al. Surgical treatment of slipped capital femoral epiphysis (SCFE) by Dunn procedure modified by Ganz: a systematic review. BMC Musculoskelet Disord 2022;22(Suppl 2):1064