Article published online: 2020-10-29

THIEME OPEN ACCESS

Case Report

Supracondylar Apophysis of the Humerus: Rare Cause of High Compression of the Median Nerve*

Apófise supracondilar do úmero: Causa rara de compressão alta do nervo mediano

Luísa Vital[1] Vitor Vidinha[1] Nuno Neves[1] Pedro Negrão[1]

[1] Department of Orthopedics and Traumatology, Centro Hospitalar Universitário de São João, Porto, Portugal

Rev Bras Ortop

Address for correspondence Luísa Vital, MD, Departamento de Ortopedia e Traumatologia, Centro Hospitalar Universitário de São João, Alameda Professor Hernâni Monteiro, Porto, 4200-319, Portugal (e-mail: luisavital1203@gmail.com).

Abstract

Supracondylar apophysis (SA) is a bony prominence that originates from the anteromedial aspect of the distal humerus with a lower projection and which, although usually asymptomatic, due to the relationship with adjacent structures can cause symptoms. We describe the case of a 42-year-old woman with pain complaints radiating from her elbow to her hand, with 6 months of evolution. On objective examination, the patient had a sensory deficit in the median nerve territory and decreased grip strength. Radiographs of the distal humerus were performed, in which a bone spike was visible, and magnetic resonance imaging showed thickening of the median nerve epineurium. Electromyography showed severe axonal demyelination of the median nerve proximal to the elbow. A median nerve compression caused by a SA was diagnosed. The patient underwent surgery and, 1 year after the operation, she had a complete clinical recovery. Supracondylar apophysis is a rare, but possible and treatable cause of high median nerve compression.

Keywords

- supracondylar apophysis
- median nerve
- compressive neuropathy
- median nerve compression

Resumo

A apófise supracondilar (ASC) é uma proeminência óssea que tem origem na face anteromedial do úmero distal com projeção inferior e que apesar de habitualmente assintomática, pela relação com as estruturas adjacentes pode causar sintomatologia. Descrevemos o caso de uma mulher de 42 anos, com queixas álgicas irradiadas do cotovelo à mão, com 6 meses de evolução. Ao exame objetivo, a paciente apresentava um déficit sensorial no território do nervo mediano e diminuição da força de preensão. Foram realizadas radiografias do úmero distal nas quais era visível uma espícula óssea, e na ressonância magnética era evidente o espessamento do epineuro do nervo mediano. A eletromiografia apresentou uma desmielinização axonal grave do nervo mediano proximal ao cotovelo. Foi diagnosticada uma compressão do nervo mediano por uma ASC. A paciente foi submetida à cirurgia e 1 ano pós-operatório apresentou recuperação clínica total. A ASC é uma causa rara, mas possível e tratável da compressão alta do nervo mediano.

Palavras-chave

- apófise supracondilar
- nervo mediano
- neuropatia compressiva
- compressão do nervo mediano

* Work developed at the Department of Orthopedics and Traumatology, Centro Hospitalar Universitário de São João, Porto, Portugal.

received
April 29, 2020
accepted
July 6, 2020

DOI https://doi.org/10.1055/s-0040-1718509.
ISSN 0102-3616.

Copyright © by Sociedade Brasileira de Ortopedia e Traumatologia. Published by Thieme Revinter Publicações Ltda, Rio de Janeiro, Brazil

License terms

Introduction

Supracondylar apophysis (SA) is an anatomical structure described by Knox in 1841. This bone prominence of variable size originates from the anteromedial face of the distal humerus, protrudes inferiorly and represents a vestigial remnant typical of climbing animals. The fibrous band known as the *Struthers* ligament, usually appears as a continuation of the SA and forms a foramen in which the median nerve and the brachial artery can be compressed in their path.[1] The prevalence of this anatomical structure varies widely in studies (0.7–2.5%); however, it is unanimous that it is rare and more marked in the Caucasian ethnicity and in females.[2]

Case Report

A 42-year-old Caucasian woman with no major medical history was observed in an Orthopedics consultation due to progressive pain complaints radiating from the elbow to the left hand, with 6 months of evolution. On objective examination, the patient had a sensory deficit in the median nerve territory and decreased grip strength. No palpable swelling in the left upper limb, no positive Tinel throughout the median nerve path, and no vascular changes. Then, she underwent imaging exams to study the symptoms presented, which revealed: on the radiographs of the distal humerus, a bone spike of inferior orientation (►**Figure 1**), and magnetic resonance imaging showed a thickening of the epineurium of the median nerve suggestive of nerve compression. On electromyography, the patient had severe axonal demyelination of the median nerve proximal to the elbow. Therefore, a compression of the median nerve was diagnosed by a SA.

The patient underwent surgery to excise this structure through an anterior route of the distal humerus. Intraoperatively, compression of the median nerve was confirmed (►**Figures 2** and **3**) and excision of the SA and *Struthers* ligament was performed without complications. In the postoperative evaluation at 2 months, the patient had a significant improvement in neurological symptoms with gain in grip strength and decreased paresthesia. An electromyography was performed that showed an appreciable recovery of the left median nerve with normalization of the motor neurography. One year after the surgery, there was a complete regression of symptoms and strength recovery, comparable to the contralateral side.



Fig. 1 Radiographs (face and profile views) of the left elbow showing the supracondylar apophysis of the distal humerus.

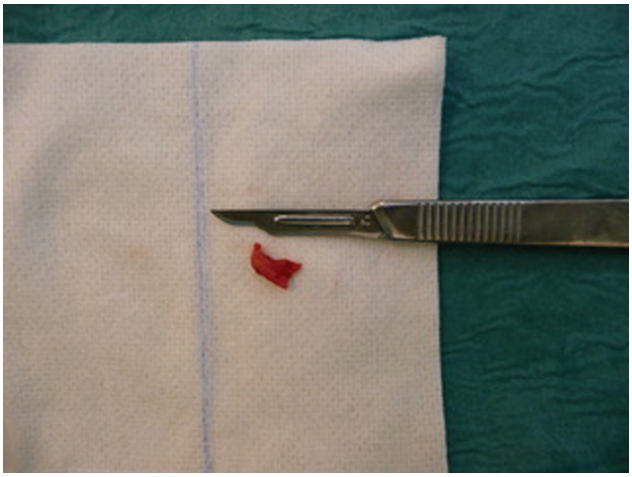

Fig. 3 Image of the supracondylar apophysis after excision.

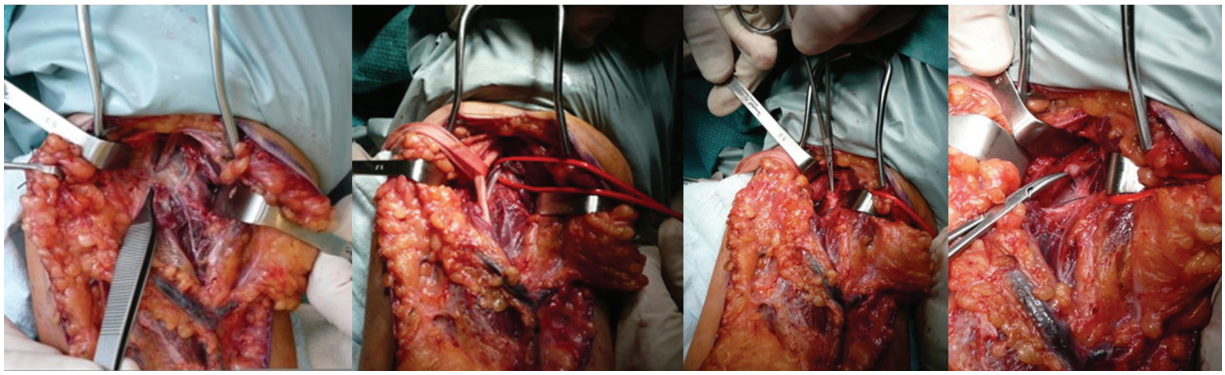

Fig. 2 Intraoperative images of the anterior plane dissection. Observation of several structures involved: median nerve, brachial artery, Struthers ligament, and supracondylar apophysis.

Discussion

Supracondylar apophysis is an anatomical structure usually without clinical manifestations; however, in some cases, it can become symptomatic and manifest by swelling and/or symptoms of compression of the median nerve and brachial artery.[3] Soliere[4] reported, in 1929, the first case of clinical changes caused by the presence of a SA. This entity represents a diagnostic challenge, given the clinical presentation similar to the most common neuropathy of the upper limb—Carpal tunnel syndrome and also by the multiple possible sites of compression of the median nerve at the level of the elbow, which include: between the heads of the pronator teres, in the aponeurotic arch formed by the proximal insertion of the forearm flexor muscles, and in the *lacertus fibrosus*.[5] The possibility of treating heterotopic ossification or osteochondroma must also be part of the differential diagnoses, since this presents differentiating characteristics that pass through the orientation of the bone spike—not pointing towards the joint and continuing with the cortical humerus.[6]

Some clinical cases of neurovascular compression associated with this structure are described in the literature: Aydinlioglu et al.[7] described a case of bilateral compression of the median nerve by the SA; May-Miller et al.[8] reported a very rare case of compression of the cubital nerve, and there are also reports of fracture of this structure.[9]

In the clinical suspicion of neuropathy caused by the SA, imaging exams combined with electromyography are diagnostic, as in the clinical case we describe. The treatment recommended in symptomatic patients is surgical and consists of excision of the SA and of the *Struthers* ligament, when the latter is present, thus allowing confirmation of the decompression of the involved structures. As described in the literature and verified in the clinical case presently described, this treatment option is associated with good functional results in the short and long term.[10]

In conclusion, SA is a rare, but possible and treatable, cause of high median nerve compression.

Conflict of Interests

The authors declare that there is no conflict of interests.

References

1 Kessel L, Rang M. Supracondylar spur of the humerus. J Bone Joint Surg Br 1966;48(04):765–769
2 C S, B S S, G v K, S L. Morphological study of the supracondylar process of the humerus and its clinical implications. J Clin Diagn Res 2014;8(01):1–3 [REMOVED HYPERLINK FIELD]
3 Subasi M, Kesemenli C, Necmioglu S, Kapukaya A, Demirtas M. Supracondylar process of the humerus. Acta Orthop Belg 2002;68 (01):72–75
4 Solieri S. Nervalgia del nervo mediano da processo sopraepitrocleare. Chir Organi Mov 1929;14:171–175
5 Caetano EB, Sabongi JJ, Vieira LA, Caetano MF, de Bona JE, Simonatto TM. Struthers' ligament and supracondylar humeral process: an anatomical study and clinical implications. Acta Ortop Bras 2017;25(04):137–142
6 Fragiadakis EG, Lamb DW. An unusual cause of ulnar nerve compression. Hand 1970;2(01):14–16
7 Aydinlioglu A, Cirak B, Akpinar F, Tosun N, Dogan A. Bilateral median nerve compression at the level of Struthers' ligament. Case report. J Neurosurg 2000;92(04):693–696
8 May-Miller P, Robinson S, Sharma P, Shahane S. The Supracondylar Process: A Rare Case of Ulnar Nerve Entrapment and Literature Review. J Hand Microsurg 2019;11(Suppl 1):S06–S10
9 Newman A. The supracondylar process and its fracture. Am J Roentgenol Radium Ther Nucl Med 1969;105(04):844–849
10 Shon HC, Park JK, Kim DS, Kang SW, Kim KJ, Hong SH. Supracondylar process syndrome: two cases of median nerve neuropathy due to compression by the ligament of Struthers. J Pain Res 2018;11:803–807