Article published online: 2021-03-31

Total Arthroplasty in Complex Elbow Injury

Artroplastia Total na Lesão Complexa do Cotovelo

Ricardo Fernandes Rezende[1] Marcela de Melo Gajo[1] Sérgio Moreira da Costa[1] Rafael Fuchs Lazarini[1] Antonio Enéas Rangel de Carvalho Junior[1] Ildeu Afonso de Almeida Filho[1]

[1] Hospital Felício Rocho, Belo Horizonte, MG, Brazil

Rev Bras Ortop

Address for correspondence Ricardo Fernandes Rezende, MD, Rua Ouro Preto, número 715, apartamento 302, Bairro Barro Preto, Belo Horizonte, MG, 30.170-040, Brazil (e-mail: ricardomed1992@gmail.com).

Abstract

The authors present an atypical case of a left elbow complex fracture with extensive loss of bone and muscle tissue. The patient was submitted to several surgical procedures, which resulted in a total arthroplasty of the left elbow with triceps reconstruction using a semitendinosus muscle tendon graft.

Keywords
- elbow joint
- arthroplasty, replacement
- elbow fractures
- elbow prosthesis

Resumo

Os autores apresentam um caso atípico de fratura complexa do cotovelo esquerdo com perda extensa de tecido ósseo e muscular. O paciente foi submetido a diversos procedimentos cirúrgicos, que resultaram em uma artroplastia total do cotovelo esquerdo associada à reconstrução do tríceps com enxerto do tendão do músculo semitendíneo.

Palavras-chave
- articulação do cotovelo
- artroplastia de substituição
- fraturas do cotovelo
- prótese de cotovelo

Introduction

Elbow complex fractures resulting from high-energy trauma present bone damage in addition to nervous, vascular, and muscular tissue involvement. Thus, their treatment is challenging, with few reports in the literature, and it requires a joint effort from professionals of several specialties. These fractures have a great impact in the quality of life, and limb functionality must be prioritized.[1]

Elbow arthroplasty is a valid therapeutic option in these highly complex cases despite the known need for further revision surgeries. It represents a possibility of limb salvage instead of amputation, which was a frequent option in the past.[2]

Here, we report a case of a complex lesion with loss of the distal humerus, the proximal ulna, and the entire extensor apparatus. The ulnar nerve and collateral ligaments were also involved. The procedure consisted in triceps

received
July 6, 2020
accepted
October 14, 2020

DOI https://doi.org/10.1055/s-0040-1722574.
ISSN 0102-3616.

© 2021. Sociedade Brasileira de Ortopedia e Traumatologia. All rights reserved.
This is an open access article published by Thieme under the terms of the Creative Commons Attribution-NonDerivative-NonCommercial-License, permitting copying and reproduction so long as the original work is given appropriate credit. Contents may not be used for commercial purposes, or adapted, remixed, transformed or built upon. (https://creativecommons.org/licenses/by-nc-nd/4.0/)

Thieme Revinter Publicações Ltda., Rua do Matoso 170, Rio de Janeiro, RJ, CEP 20270-135, Brazil

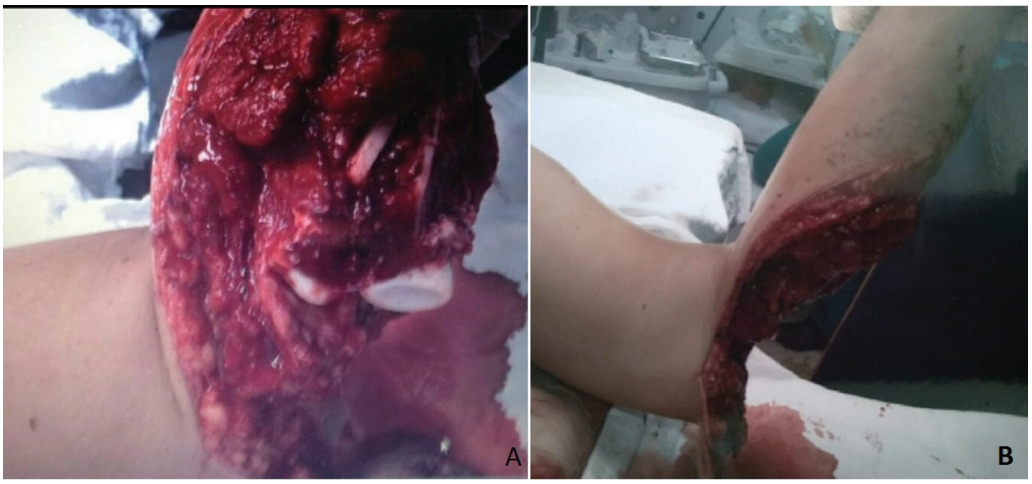

Fig. 1 (A/B) Image of the left elbow on the day of the trauma (before surgery).

reconstruction with a graft from semitendinosus muscle tendon after latissimus dorsi flap rotation. A semi-constricted prosthesis was used, resulting in a functional upper limb.

The patient duly signed the informed consent form, agreeing and authorizing disclosure of the data obtained from medical records, as well as images and photographs shown in the present case report.

Case Report

The patient whose case is presently described is a white, single, 18-year-old male who is a medical student and a motorcyclist.

The patient was involved in a car-motorcycle collision in the city of Natividade, RJ, Brazil, on December 16, 2015. The initial care and fractures immobilization were performed by the fire brigade on the site of the accident, 90 minutes after the collision. Next, he was referred to Hospital São José do Avaí, in Itaperuna, RJ.

During the initial hospital care, open fractures were observed on the left leg and the left elbow, with bone loss at the distal humerus, loss of the olecranon, and extensive skin, muscle, and nerve damage (►**Figure 1**).

The patient had a hemorrhagic shock and hypothermia. Hemodynamic stabilization and transarticular external fixation of the left elbow were performed. Drug treatment was initiated with intravenous administration of cefazolin, 1 g



Fig. 2 (A) Perioperative (B) and postoperative image of the latissimus dorsi flap.

 © 2021. Sociedade Brasileira de Ortopedia e Traumatologia. All rights reserved.

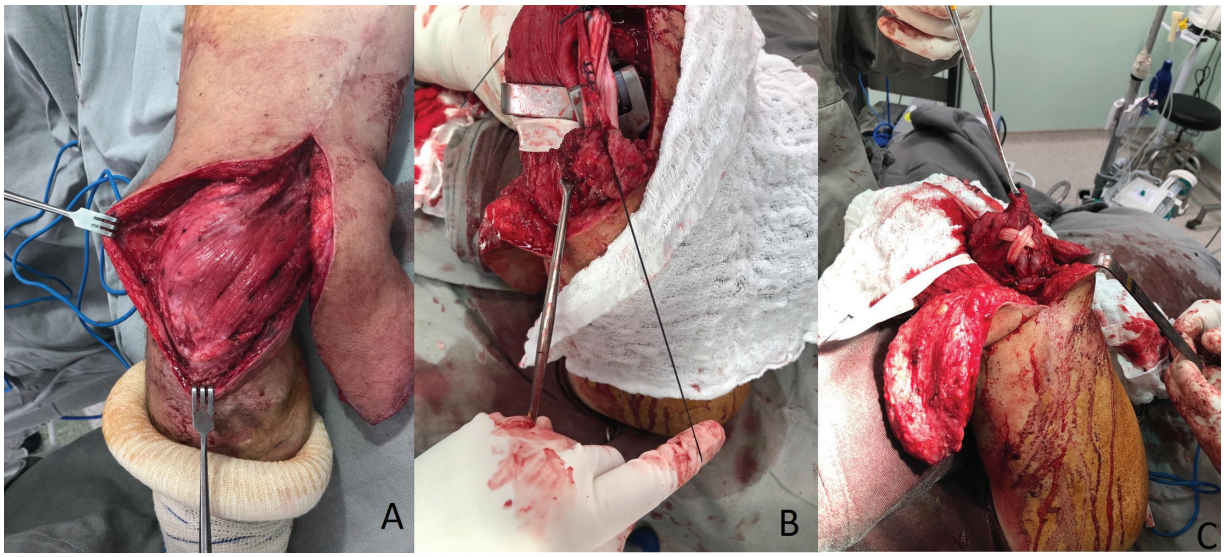

Fig. 3 (A/B/C) Triceps reconstruction with a semitendinosus muscle tendon graft.

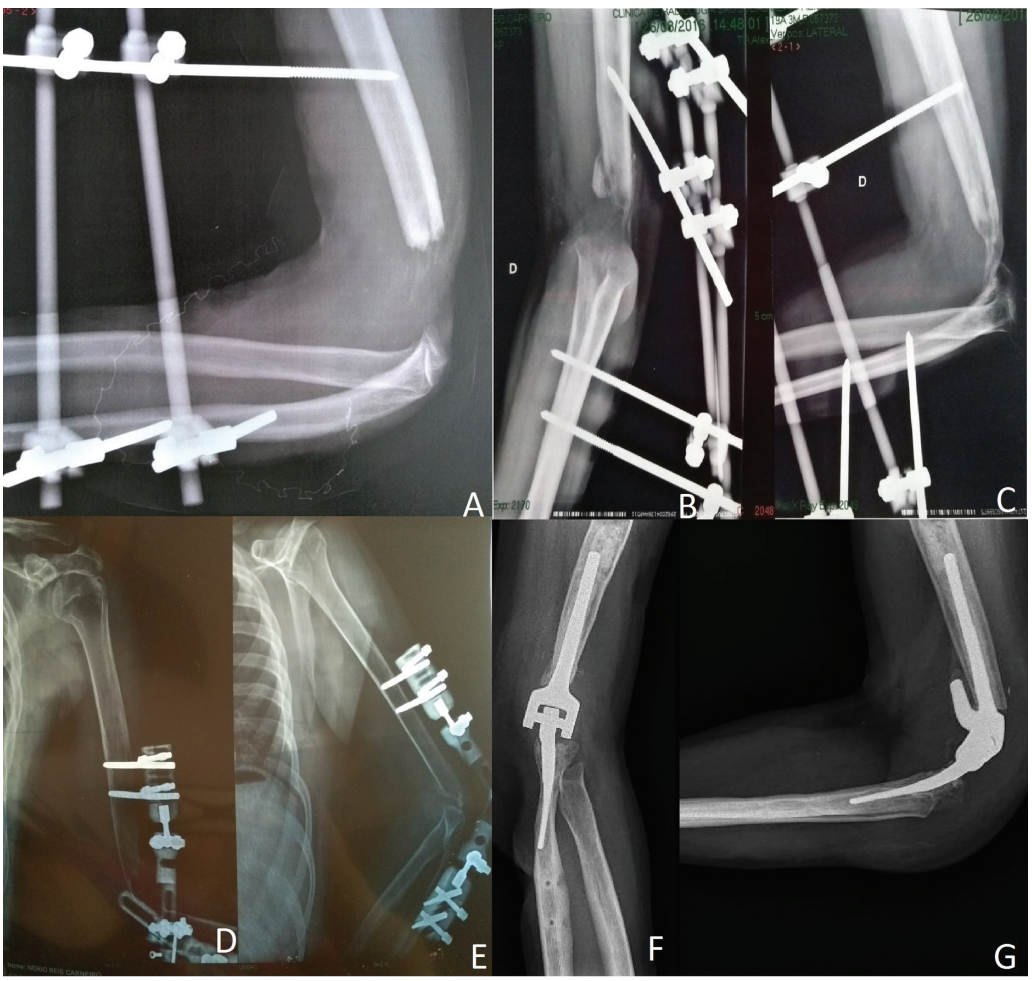

Fig. 4 (A) Lateral radiography showing the first external fixator (transarticular, tube-to-tube) and bone failure at the left elbow level. (B/C) Anteroposterior (AP) and lateral radiographs, respectively, showing bone tissue formation at the left elbow level. (D/E) AP and lateral radiographs showing the external fixator articulated at the left elbow level. (F) AP radiography showing the elbow prosthesis. (G) Lateral radiograph showing the elbow prosthesis.

 © 2021. Sociedade Brasileira de Ortopedia e Traumatologia. All rights reserved.



Fig. 5 (A/B/C/D) Current physical aspect and range of motion of the left elbow.

every 6 hours, and amikacin, 500 mg every 24 hours. Then, the patient was transferred to the intensive care unit (ICU). On December 17, 2015, the patient underwent surgical debridement of the elbow. Cefazolin was terminated and replaced with intravenous ceftriaxone, 1 g every 12 hours, and amikacin, 500 mg every 24 hours; both drugs were administered until December 30, 2015, when the patient developed fever, cutaneous hyperemia, and local heat; thus, vancomycin, 500 mg every 6 hours, was intravenously administered up to January 20, 2016. On January 29, 2016, the patient was discharged from the hospital.

On February 29, 2016, skin grafting was performed on the left elbow, with the left thigh as the donor area. The patient underwent hyperbaric chamber therapy for 6 months. In September 2016, a conventional tube-to-tube external fixator was replaced with an articulated external fixator at Hospital Felício Rocho, allowing minimal joint mobility. After bone tissue formation was detected by radiography, the fixator was removed, and an articulated orthosis was adapted.

On July 24, 2018, a latissimus dorsi muscle flap was rotated by the plastic surgery team (►**Figure 2**). Subsequently, on March 18, 2019, a total elbow arthroplasty was performed with a semiconstrained prosthesis and triceps reconstruction using a semitendinosus muscle tendon graft (►**Figures 3** and **4**)

After an intense rehabilitation program, with several physical therapy, hydrotherapy, and occupational therapy sessions, the limb function was recovered. The patient is currently satisfied, with no complaints. Physical examination shows no inflammatory signs, no pain on palpation of the left elbow, a good-looking scar, and range of motion of -20° in extension, 105° in flexion, 0° in active prone supination, 90° in passive supination and 30° in passive pronation (►**Figure 5**).

Discussion

The mutilating upper limb lesion is characterized by significant damage to soft, vascular, nervous, and bone tissues associated with high-energy trauma and complex fractures.[1] This kind of injury affects mostly young men, and it may lead to partial limb amputation.[2]

In complex traumatic injuries, such as the one reported here, the initial approach largely determines the therapeutic success and potential limb recovery. Early washing, debridement, and antibiotic therapy, within 24 hours, result in lower rates of infection and lower failure rate for soft-tissue coverage. Despite the controversy over the exact time to perform such coverage, early flaps and grafts have a better prognosis, and often accompany primary bone fixation.[1]

The use of a prosthesis has advantages, such as faster rehabilitation, no need for bone consolidation, early range of motion gain, efficient pain control and limb function recovery.[3] Nevertheless, its survival time remains relatively short,

 © 2021. Sociedade Brasileira de Ortopedia e Traumatologia. All rights reserved.

ranging from 5 to 10 years, in an older population with low demand.[2]

Although the prosthesis restricts the load limit of the limb, it also has advantages such as significant pain improvement and function gain.[4] In the case presently described, the prosthesis reestablished the connection between the arm and the forearm, transforming a swinging limb into a functional one.

Total elbow arthroplasty contraindications include active infection, associated neurological lesions, triceps and brachial arteries involvement, a large open wound, and a severe loss of hand functionality.[4] Our patient had a triceps lesion with loss of the elbow extensor's mechanism; however, concurrent with elbow arthroplasty, the triceps was reconstructed with a semitendinosus muscle tendon graft for elbow extensor mechanism restoration.

Despite progress, the rate of surgical revision remains significant. Recent studies, with a follow-up of up to 10 years after arthroplasty, report revision rates or need for additional surgery ranging from 8 to 27% of the elbows addressed, with an implant survival rate of 76 to 92%.[5,6]

The most common complications are implant loosening, joint instability, and infection.[4]

When choosing an elbow arthroplasty for treatment, patients and physicians must be aware of implant limitations, potential complications, and the possibility of needing to seek excellence centers if revision is required. Brazil presents a small number of cases, such as the one presently reported, so elbow arthroplasty revision surgeries are uncommon, and this learning curve is far from over.

Study developed at Hospital Felício Rocho, Belo Horizonte, MG, Brazil.

Conflict of Interests

The authors declare that there is no conflict of interests.

References

1 Miller EA, Iannuzzi NP, Kennedy SA. Management of the Mangled Upper Extremity: A Critical Analysis Review. JBJS Rev 2018;6(04): e11

2 Hall JA. Total Elbow Arthroplasty in the Treatment of Complex Distal Humeral Fractures. In: Biberthaler P, Siebenlist S, Waddell J, eds. Acute Elbow Trauma. Strategies in Fracture Treatments. Cham, Switzerland: Springer; 2019:111–117

3 Harmer LS, Sanchez-Sotelo J. Total Elbow Arthroplasty for Distal Humerus Fractures. Hand Clin 2015;31(04):605–614

4 Levin ES, Plotkin B. Elbow Arthroplasty: From Normal to Failure. Semin Musculoskelet Radiol 2019;23(02):141–150

5 Nestorson J, Rahme H, Adolfsson L. Arthroplasty as primary treatment for distal humeral fractures produces reliable results with regards to revisions and adverse events: a registry-based study. J Shoulder Elbow Surg 2019;28(04):e104–e110

6 Barco R, Streubel PN, Morrey BF, Sanchez-Sotelo J. Total Elbow Arthroplasty for Distal Humeral Fractures: A Ten-Year-Minimum Follow-up Study. J Bone Joint Surg Am 2017;99(18):1524–1531

 © 2021. Sociedade Brasileira de Ortopedia e Traumatologia. All rights reserved.