Article published online: 2021-03-31

Fibroma of the Patellar Tendon Sheath: A New Paradigm

Fibroma da bainha do tendão patelar: Um novo paradigma

João Boavida[1] Rui Sousa Grandão[2] Maria Pia Monjardino[1] Catarina Quintas[1] João Pedro Oliveira[1]

[1] Orthopedics Service, Centro Hospitalar e Universitário de Coimbra EPE, Coimbra, Portugal
[2] Briosa Family Health Unit, Centro de Saúde Norton de Matos, Coimbra, Portugal

Address for correspondence João Boavida, Resident with Specific Training in Orthopedics, Serviço de Ortopedia, Centro Hospitalar e Universitário de Coimbra EPE, Coimbra, Portugal (e-mail: joaoboavida8@gmail.com).

Rev Bras Ortop

Abstract

The authors present a case of fibroma of the tendon sheath with intra-articular location in the knee, more specifically in the infrapatellar fat; with this specific location, this is the fourth case described of an entity that rarely affects large joints. Clinical and epidemiological aspects, but especially the imaging findings on magnetic resonance imaging scans, are essential for the differential and definitive diagnosis, which was nevertheless established only after a histological study of the excised mass by miniarthrotomy.

Keywords

- fibroma
- knee
- tendons
- patella

Resumo

Os autores apresentam um caso de um fibroma da bainha de tendão com localização intra-articular no joelho e origem na gordura infrapatelar. Esta localização específica é extremamente rara, sendo este o quarto caso descrito de uma entidade que raramente afeta grandes articulações. Para o seu diagnóstico aspetos clínicos, epidemiológicos e sobretudo achados imagiológicos da ressonância magnética são fundamentais. Neste caso o diagnóstico definitvo foi apenas estabelecido após estudo histológico da massa excisada por mini-artrotomia.

Palavras-chave

- fibroma
- joelho
- tendães
- patela

Introduction

Fibroma of the tendon sheath (FTS) is a reactive tumor lesion with origin in the synovial membrane of the tendon sheath, benign and rare,[1] first described by Geschickter and Copeland[2] in 1949. It is defined as a slow-growing nodular neoplasm adjacent to the tendon sheath, clinically manifested by a small joint mass or effusion that essentially affects people between 20 and 50 years of age, especially men, and more commonly the joints of the fingers and hand, being relatively rare in large joints.[3,4] In these, the knee is the most common location, but most commonly associated with the cruciate ligament and posterior capsule, with only three cases described in the literature of tendon sheath tumors emerging from the infrapatellar Hoffa sheath.[5] The authors present a case of a fibroma of the patellar tendon sheath at the intra-articular level.

Case Report

A 39-year-old male physician attended the orthopedics consultation for anterior pain in the left knee, mild and

received
August 17, 2020
accepted
September 17, 2020

DOI https://doi.org/10.1055/s-0040-1722594.
ISSN 0102-3616.

© 2021. Sociedade Brasileira de Ortopedia e Traumatologia. All rights reserved.
This is an open access article published by Thieme under the terms of the Creative Commons Attribution-NonDerivative-NonCommercial-License, permitting copying and reproduction so long as the original work is given appropriate credit. Contents may not be used for commercial purposes, or adapted, remixed, transformed or built upon. (https://creativecommons.org/licenses/by-nc-nd/4.0/)

Thieme Revinter Publicações Ltda., Rua do Matoso 170, Rio de Janeiro, RJ, CEP 20270-135, Brazil

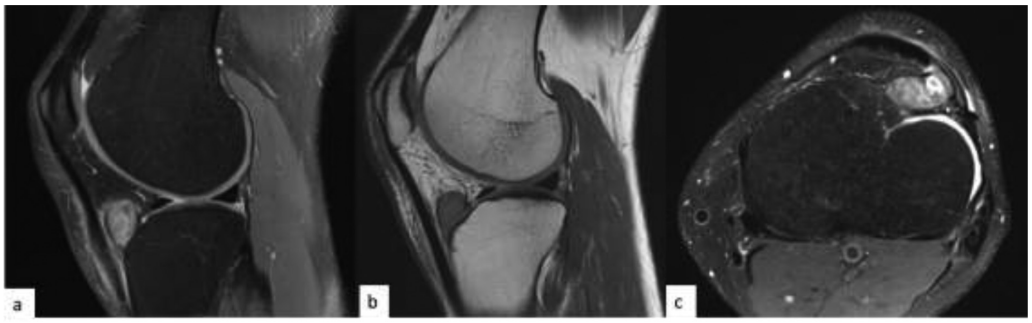

Fig. 1 Images of the relative isointensity in the sagittal plane on T2 (**a**), T1 (**b**) and axial plane on T2 (**c**).

present mainly in the initial phase of symptoms, with an associated soft-tissue mass with about 12 months of evolution and slow growth. He denied any history of previous trauma or previous complaints in this knee. The arc of motion of the knee joint was preserved, with extension up to 0° and flexion up to 130°, with discomfort starting at 90° of flexion. There were no joint effusion of the knee or apparent instabilities. The mass was located in the anterolateral region of the knee, lateral to the patellar tendon, and it was soft, painless on palpation, of hard-elastic consistency, with about 4 cm in its largest axis and 2 cm in width. Analytically, there were no alterations, and, in the sonographic and radiological study of the knee, no alterations were observed as well. A Magnetic resonance imaging (MRI) scan showed a tissue mass attached to the Hoffa pouch in the anterolateral region of the knee anterior to the lateral plate of the tibia and posterolateral to the patellar tendon, with 3.9 cm x 1.9 cm of isointense signal to the muscle on either T1 and T2, with hyperintensity foci and well-defined edges (►**Figure 1**). We raised the diagnostic hypothesis of giant cell tumor (GCT). We chose to perform a marginal resection of the lesion by lateral parapatellar miniarthrotomy, verifying that it was an intracapsular and intra-synovial lesion with a pedicle to the Hoffa pouch, lateral to the anterior tuberosity of the tibia and posterolateral to the patellar tendon. The pedicle was resected, and the lesion was completely excised, and we obtained an oval and irregular fragment measuring 4 cm x 2 cm x 1.5 cm, with a white, bright and lobulated section surface (►**Figure 2**). On the pathological study, we observed that the lesion corresponded mainly to a fibro-hyaline stroma, in which collagen fibers are limited by elongated fibroblasts, monotonous and without atypia, as well as by a neovascular component, occasionally observing a surface coated by synovial epithelium (►**Figure 3**). Thus, the diagnosis of fibroma of the patellar tendon sheath of the knee was established. With ten months of evolution, the patient denies pain or any associated functional limitation, with no signs of local recurrence.

Discussion

Fibromas of the tendon sheath mainly involve the joints of the fingers, hand and wrist, and 75% to 82% are found in these locations, most often corresponding to a small, firm,

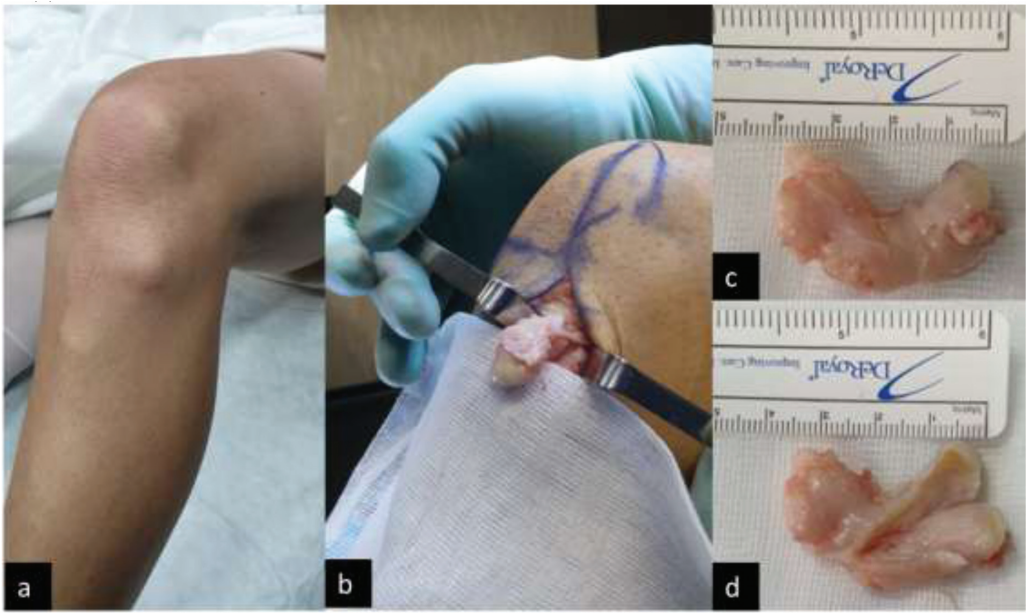

Fig. 2 Intraoperative photographs: (**a**) location and clinical appearance; (**b**) pediculated lesion before complete excision; (**c**) macroscopic appearance and measurement of the largest axis, with approximately 4 cm (**d**) Relatively homogeneous intralesional macroscopic aspect.

 © 2021. Sociedade Brasileira de Ortopedia e Traumatologia. All rights reserved.

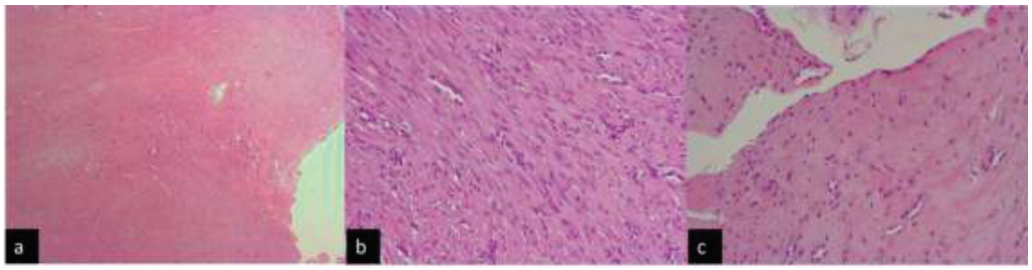

Fig. 3 Photomicrography: (**a**) proliferation of fibrohyaline stroma; (**b**) elongated and monotonous fibroblasts; (**c**) surface coated by synovial epithelium.

painless and slow-growing nodule dependent on the tendon or its sheath, with a peak incidence in the third and fourth decades of life, and 3 to 5 times more common among men.[6] Although the knee is the most frequently-involved large joint, less than 40 cases have been described, most of them originating from the posterior cruciate ligament or posterior capsule, and, in large joints, the most commonly-described symptoms are pain and palpable mass smaller than 7 cm, in this order of frequency.[5] The case herein presented has most of the clinical and epidemiological characteristics described as more common, except for the location, with only three cases described to date that were dependent on the patellar tendon, and 3, on infrapatellar fat.[5]

The imaging studies with x-ray or axial computed tomography in this type of lesion are normal, and erosive bone changes or soft-tissue changes may rarely be observed in larger lesions.[7] The FTS MRI findings are usually constant on T1, generally showing a well-defined lesion of low signal or isointense to the muscle; however, the T2-weighted images show a great variability of patterns, most commonly a low-intensity signal to the muscle, and the following can also be observed: a high-intensity central zone in a low-intensity matrix, high focal intensity signal, or high-intensity image across the mass.[5] The case herein described, when demonstrating an isointense lesion to the muscle on T1 and relatively isointense also on T2, with hyperintensity foci, led the authors to initially consider it to be a GCT, which is characteristically isointense or with low intensity, either on T1 or T2.[8] In addition to GCT, whose presence in the histological examination of multinucleated giant cells and hemosiderin deposits is fundamental for the diagnosis, FTS has as a differential diagnosis nodular fasciitis.[5] The possible variability on T2 on the MRI makes the differential diagnosis of nodular fasciitis uncertain; however, the fact that it rarely presents an intra-articular location, being associated with a rapidly-growing and more commonly painful mass and presenting older tissue, with more prominent myxoid stroma, with red-cell extravasation and without any vascular pattern on the histological examination differentiate nodular fasciitis from FTS, in which a nodular pattern, sometimes with small slit-like vascular canals and coated with synovial epithelium, is typical.[4] The treatment of choice for these lesions is marginal excision, most often through an open approach.[5] Although Chung and Enzinger[9] reported a recurrence rate of 24%, in large joints, such as the knee, there are no cases described in the literature.[5] It should be noted, however, that given the absence of absolute certainty of complete removal of the lesion in the case herein described, attention is important to exclude recurrence.

In conclusion, this case herein reported reinforces the importance of including FTS in the differential diagnosis of soft-tissue masses at the level of the knee.

Free and informed consent

Free and informed consent was obtained from the patient for the publication of the data regarding the case.

Conflict of Interests

The authors have no conflicts of interests to declare.

References

1 Pinar H, Ozkan M, Ozaksoy D, Pabuççuoğlu U, Akseki D, Karaoğlan O. Intraarticular fibroma of the tendon sheath of the knee. Arthroscopy 1995;11(05):608–611
2 Geschickter CF, Copeland MM. Tumors of bone. 3rd ed. Philadelphia: J.B. Lippincott Co; 1949
3 Aynaci O, Kerimoglu S, Ozturk C, Saracoglu M, Yildiz K. Intraarticular fibroma of the tendon sheath arising from the infrapatellar fat pad in the knee joint. Arch Orthop Trauma Surg 2009;129(03):291–294
4 Griesser MJ, Wakely PE, Mayerson J. Intraarticular fibroma of tendon sheath. Indian J Orthop 2011;45(03):276–279
5 Suzuki K, Yasuda T, Suzawa S, Watanabe K, Kanamori M, Kimura T. Fibroma of tendon sheath around large joints: clinical characteristics and literature review. BMC Musculoskelet Disord 2017;18(01):376
6 Hitora T, Yamamoto T, Akisue T, et al. Fibroma of tendon sheath originating from the knee joint capsule. Clin Imaging 2002;26(04):280–283
7 Kundangar R, Pandey V, Acharya KK, Rao PS, Rao L. An intraarticular fibroma of the tendon sheath in the knee joint. Knee Surg Sports Traumatol Arthrosc 2011;19(11):1830–1833
8 Wang CS, Duan Q, Xue YJ, et al. Giant cell tumour of tendon sheath with bone invasion in extremities: analysis of clinical and imaging findings. Radiol Med (Torino) 2015;120(08):745–752
9 Chung EB, Enzinger FM. Fibroma of tendon sheath. Cancer 1979;44(05):1945–1954

 © 2021. Sociedade Brasileira de Ortopedia e Traumatologia. All rights reserved.