Article published online: 2021-04-19

Sensory and Motor Median Nerve Neuropathy Due to a Deep Giant Hand Lipoma. A Case Report

Neuropatia sensorial e motora do nervo mediano por um lipoma gigante na mão. Relato de caso

Ioannis M. Stavrakakis[1] Vasiliki Georgopoulou[1] George E. Magarakis[2] Maria S. Katsafarou[1]

[1] Department of Orthopedics, General Hospital of Agios Nikolaos, Crete, Greece
[2] Department of Orthopedics, Venizeleio General Hospital of Heraklion, Crete, Greece

Address for correspondecnce Ioannis M. Stavrakakis, MD, MSc, FEBOT, General Hospital of Agios Nikolaos, 4 Knossou Street, p.c.: 72100. Agios Nikolaos, Crete, Greece (e-mail: i.m.stavrakakis@gmail.com).

Rev Bras Ortop

Abstract

Lipomas are the most common soft-tissue tumors in the human body, but their location in the hand is rare. Symptomatic hand lipomas, due to nerve compression, are even rarer. We present a case of median nerve neuropathy as a result of a giant palm lipoma, located on the thenar and hypothenar areas of the hand. The patient had typical symptoms of carpal tunnel syndrome, along with compromised thumb motion. Intraoperatively, the recurrent motor branch of the median nerve was sitting on the lipoma under a great tension. This particular location of the motor branch of the median nerve in relation to the lipoma makes this case unique. The tumor was excised protecting the neurovascular structures, and a few weeks later the patient regained full thumb motion, grip strength, and resolution of dysesthesia.

Keywords

- carpal tunnel syndrome
- hand
- lipoma
- soft tissue neoplasms
- median nerve neuropathy

Resumo

Os lipomas são os tumores de partes moles mais comuns no corpo humano, mas sua localização na mão é rara. Os lipomas de mão que causam sintomas por compressão do nervo são ainda mais raros. Apresentamos um caso de neuropatia do nervo mediano decorrente de um lipoma palmar gigante, localizado nas regiões tenar e hipotenar da mão. A paciente apresentava sintomas típicos de síndrome do túnel do carpo, além de comprometimento dos movimentos do polegar. Durante a cirurgia, o ramo motor recorrente do nervo mediano repousava sobre o lipoma sob grande tensão. Esta localização particular do ramo motor do nervo mediano em relação ao lipoma torna este caso único. O tumor foi extirpado, protegendo as estruturas neurovasculares e, poucas semanas depois, a paciente havia recuperado totalmente os movimentos do polegar e força de preensão, além de apresentar resolução da disestesia.

Palavras-chave

- síndrome do túnel do carpo
- lipoma
- mão
- neoplasias de tecido mole
- neuropatia do nervo mediano

received
October 18, 2020
accepted
January 8, 2021

DOI https://doi.org/10.1055/s-0041-1726072.
ISSN 0102-3616.

© 2021. Sociedade Brasileira de Ortopedia e Traumatologia. All rights reserved.
This is an open access article published by Thieme under the terms of the Creative Commons Attribution-NonDerivative-NonCommercial-License, permitting copying and reproduction so long as the original work is given appropriate credit. Contents may not be used for commercial purposes, or adapted, remixed, transformed or built upon. (https://creativecommons.org/licenses/by-nc-nd/4.0/)

Thieme Revinter Publicações Ltda., Rua do Matoso 170, Rio de Janeiro, RJ, CEP 20270-135, Brazil

Introduction

Hand lipomas represent ~ 15% of all soft-tissue tumors in the body.[1] Their occurrence in the hand is rare, accounting to 1 to 3.8% of all benign hand soft-tissue tumors.[2] Their etiology remains unclear, but there is evidence supporting that either genetic, traumatic, or metabolic factors can cause them.[1,3] They are mainly asymptomatic, but neuropathy might develop, due to nerve compression, with subsequent pain and functional disability.[4] The main indications for surgical excision are pain, compromised function, cosmetic reasons, and large size.[5] We present the case of a female patient, who presented with a soft, enlarged mass on her right palm. She also described symptoms compatible with carpal tunnel syndrome, as well as compromised thumb movements. The patient was successfully treated with tumor excision. This case highlights a rare location of the recurrent motor branch of the median nerve in contact to a hand lipoma. Appropriate intraoperative figures are provided as well, to present this rare image adequately. This case presentation was performed in compliance with the world medical association of Helsinki on ethical principles for medical research involving human subjects and was reviewed by the Institutional Review Board.

Case Presentation

A 49-year-old female patient presented to our institution reporting a relatively large mass over her right palm. The patient noticed its presence 6 months prior to the appointment. She mentioned that this mass had gotten progressively larger over the last 3 months. During the same period, she developed tingling on the three radial digits, as well as compromised motion of her thumb and reduced grip strength. The patient had a few lipomas removed from her skull in the past. Her mother also had the same problem.

On examination, a soft, firm, mildly tender mass was located on the mid palm, extending from the thenar to the hypothenar area (►**Fig. 1**). Tumor's percussion reproduced tingling on the radial three digits, indicating a strongly positive Tinel sign. Palmar abduction of the thumb was weak as well. No thenar atrophy was identified, though, probably because patient's symptoms were not present for a long time. Carpal tunnel syndrome associated to median nerve compression caused by a hand lipoma was suspected. The patient underwent electromyography (EMG), which confirmed median nerve neuropathy. Magnetic resonance imaging (MRI) revealed a deep $5{,}7 \times 2{,}4 \times 2$ cm palmar lipoma, and surgical excision was scheduled.

Under general anesthesia and humeral tourniquet application, a midline longitudinal volar incision, extending from the wrist crease all the way distally across the "lifeline," was performed. A large bilobulated yellowish tumor was identified between the palmar aponeurosis and underlying flexor tendons, occupying the thenar and hypothenar areas. It originated from the distal part of the carpal tunnel in close proximity to the median nerve. The recurrent motor branch of the median nerve was found to be under great tension, on the lipoma, and it was literally splitting the tumor into two lobes (►**Figs. 2**, **3**). We believe that this intraoperative image is unique. The lipoma had to be dissected for it to be removed safely, without damaging the nerve (►**Fig. 4**). The carpal tunnel was also released to achieve an adequate decompression of the median nerve (►**Fig. 5**).

The wound healed uneventfully and 3 months later, the patient reported complete resolution of dysesthesia and improved thumb motion. It is though noticed mild stiffness of the fingers, probably due to some form of algodystrophy, which is currently managed with physiotherapy.

Discussion

Lipomas, although common benign tumors, rarely present in the hand. They are predominantly superficial and asymptomatic. Hand lipomas located in the deep palmar space are more infrequent.[6] Their etiology is multifactorial. Traumatic, genetic, and metabolic factors have been considered as potential causes. Genetic mutations in the chromosomal region 12q13–15 have been incriminated.[1,6] Our patient reported the excision of multiple lipomas' from her skull in the past, as well as a genetic predisposition, indicating a probable familial multiple lipomatosis. Blunt trauma may lead to a lipoma formation through preadipocyte tissue differentiation, stimulated by inflammatory mediators' release and hematoma creation. Metabolic disorders, such as diabetes, hyperlipidemia, and endocrinopathies have also been related to lipomas.[3]



Fig. 1 Clinical Image of the patient's right palm. A soft-tissue mass of the thenar and hypothenar area is visible.

 © 2021. Sociedade Brasileira de Ortopedia e Traumatologia. All rights reserved.

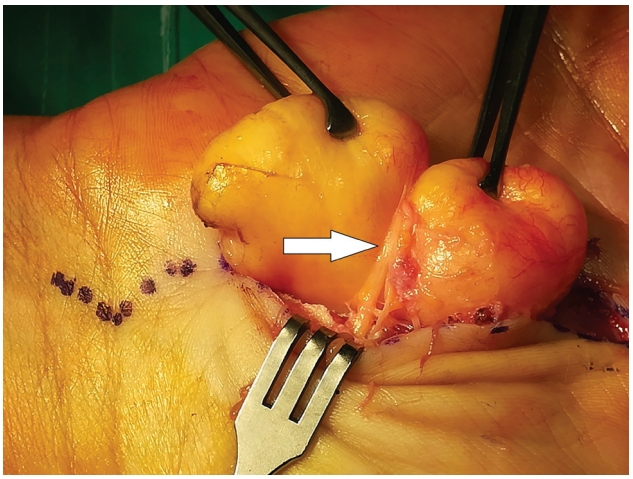

Fig. 2 Intraoperative view showing the recurrent motor branch of the median nerve (white arrow), sitting between the lipoma's two lobes. The nerve is obviously under tension.

It is widely accepted that tumors larger than 5 cm are considered giant lipomas,[1,2,4] and they present a higher possibility of malignancy.[7] Hand lipomas can be either superficial or deep. Deep lipomas are categorized as endovaginal, if they are located inside the tendon sheath, or epivaginal, if they are located outside of it.[6,8] Depending on their location, hand lipomas can be either asymptomatic or they can produce pain, tingling or motor deficits via compressing adjacent structures, such as nerves or tendons. The former symptoms along with tumor size and cosmetic concerns, are indications for surgery.[3,9]

Several cases of median nerve compression have been reported in the literature, mimicking a carpal tunnel syndrome,[1,2,5,6] but very few cases are reported having a compromised thumb motion due to compression of the median nerve's motor branch.[9] Our case involved dysfunction of the thenar muscles, confirmed by EMG studies, in addition to fingers' tingling due to median nerve neuropathy, which was caused by compression of the lipoma. Most lipomas are superficial, and they might compress palmar



Fig. 4 Excised lipoma. It had to be dissected into two parts, to avoid damaging the motor branch of the median nerve. The two pieces are approximated in this photo.

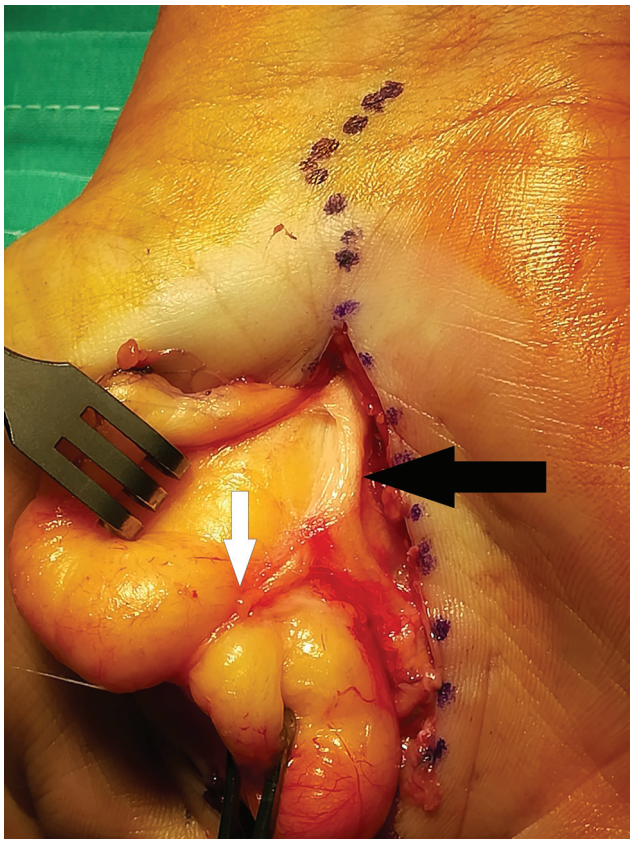

Fig. 3 Intraoperative view after releasing the distal part of the carpal tunnel. The median nerve (black arrow) and its motor branch (white arrow) are lying onto the tumor.



Fig. 5 View of the palm after lipoma excision. White arrow is pointing at the recurrent motor branch of the median nerve.

 © 2021. Sociedade Brasileira de Ortopedia e Traumatologia. All rights reserved.

structures from above, whereas deep lipomas can blend with nerves or tendons in various ways. One can find them passing either above[10] or even through the tumor.[9] Our case represents a very rare image of the recurrent motor branch of the median nerve, which was passing above the tumor, between its two lobes, making the nerve vulnerable during excision.

Surgical excision, when indicated, is the treatment of choice for hand lipomas. Few complications are possible, such as hematoma, and paresis or dysesthesia due to iatrogenic nerve injury. Recurrence is very rare and concerns mainly incompletely resected deep lipomas.[3] Malignant transformation is also extremely rare.[9]

Conclusion

We report a rare case of sensory and motor median nerve neuropathy caused by a deep palmar giant lipoma. The close relation of the recurrent motor branch of the median nerve to the lipoma, which is described in our case, highlights the attention required from the surgeon during surgery to avoid a devastating iatrogenic injury.

Conflict of Interests

The authors declare that there is no conflict of interests.

References

1 Grivas TB, Psarakis SA, Kaspiris A, Liapi G. Giant lipoma of the thenar–case study and contemporary approach to its aetiopathogenicity. Hand (N Y) 2009;4(02):173–176

2 Fazilleau F, Williams T, Richou J, Sauleau V, Le Nen D. Median nerve compression in carpal tunnel caused by a giant lipoma. Case Rep Orthop 2014;2014:654934

3 Nadar MM, Bartoli CR, Kasdan ML. Lipomas of the hand: a review and 13 patient case series. Eplasty 2010;10:e66

4 Lisenda L, van Deventer S, Pikor T, Lukhele M. Case report: Giant lipoma of the hand. SA Orthop J 2013;12(03):46–48

5 Ribeiro G, Salgueiro M, Andrade M, Fernandes VS. Giant palmar lipoma - an unusual cause of carpal tunnel syndrome. Rev Bras Ortop 2017;52(05):612–615

6 Babins DM, Lubahn JD. Palmar lipomas associated with compression of the median nerve. J Bone Joint Surg Am 1994;76(09): 1360–1362

7 Singh V, Kumar V, Singh AK. Case report: A rare presentation of Giant palmar lipoma. Int J Surg Case Rep 2016; 26:21–23

8 Pagonis T, Givissis P, Christodoulou A. Complications arising from a misdiagnosed giant lipoma of the hand and palm: a case report. J Med Case Reports 2011;5:552

9 Dae-Geun Kim. Sung-Il Hwang. Deep-Seated Giant Lipoma on the Hand Inducing Carpal Tunnel Syndrome. Soonchunhyang Med Sci 2020;26(01):19–21

10 Kim KS, Lee H, Lim DS, Hwang JH, Lee SY. Giant lipoma in the hand: A case report. Medicine (Baltimore) 2019;98(52):e18434

 © 2021. Sociedade Brasileira de Ortopedia e Traumatologia. All rights reserved.