Article published online: 2021-04-19



# Epiphysiolysis in a 22-Year-Old Patient with Congenital Hypogonadotropic Hypogonadism: Case Report*

## *Epifisiólise em paciente de 22 anos de idade com hipogonadismo hipogonadotrópico congênito: Relato de caso*

Alexandre Pedro Nicolini[1] Claudio Takashi Kuga[2]

[1] Sports Traumatology Center, Escola Paulista de Medicina, Universidade Federal de São Paulo, São Paulo, SP, Brazil
[2] Department of Orthopedics and Traumatology, Hospital Geral de Pedreira, São Paulo, SP, Brazil

**Address for correspondence** Alexandre Pedro Nicolini, M.D., Centro de Traumatologia do Esporte - Universidade Federal de São Paulo/Escola Paulista de Medicina, Rua Estado de Israel, 636, São Paulo, SP, Brazil (e-mail: apnicolini@uol.com.br).

Rev Bras Ortop

**Abstract**

Epiphysiolysis is a relatively common disease in the adolescent population (9–16 years); however, it is rare in the adult population. It is characterized by non-traumatic proximal femur slipping. When it occurs in this population it is associated with some disease that slows sexual development and physis closure, such as endocrine diseases or brain tumors. The aim of the present study is to report a case of epiphysiolysis in a 22-year-old patient with hypogonadotropic hypogonadism. There are only 63 cases reported in the world literature on epiphysiolysis in the adult population.

**Keywords**
- epiphyses, slipped
- Kallmann syndrome
- femur head
- epiphysiolysis

**Resumo**

A epifisiólise é uma doença relativamente comum na população adolescente (de 9–16 anos), entretanto rara na população adulta. Se caracteriza pelo escorregamento metáfiso-epifisário do fêmur proximal não-traumático. Quando ocorre nessa população está associada a alguma doença que retarda o desenvolvimento sexual e fechamento fisário, como doenças endocrinológicas ou tumores cerebrais. O objetivo do estudo é relatar um caso de epifisiólise numa paciente com 22 anos de idade e hipogonadismo hipogonadotrófico. Existem apenas 63 casos relatados na literatura mundial sobre epifisiólise na população adulta.

**Palavras-chave**
- epífise deslocada
- síndrome de Kallmann
- cabeça do fêmur
- epifisiólise

* *Study developed at the Sports Traumatology Center - Universidade Federal de São Paulo, Escola Paulista de Medicina, São Paulo, SP, Brazil.*

**received**
August 30, 2020
**accepted**
December 1, 2020

**DOI** https://doi.org/10.1055/s-0041-1726071.
**ISSN** 0102-3616.

© 2021. Sociedade Brasileira de Ortopedia e Traumatologia. All rights reserved.
This is an open access article published by Thieme under the terms of the Creative Commons Attribution-NonDerivative-NonCommercial-License, permitting copying and reproduction so long as the original work is given appropriate credit. Contents may not be used for commercial purposes, or adapted, remixed, transformed or built upon. (https://creativecommons.org/licenses/by-nc-nd/4.0/)

Thieme Revinter Publicações Ltda., Rua do Matoso 170, Rio de Janeiro, RJ, CEP 20270-135, Brazil

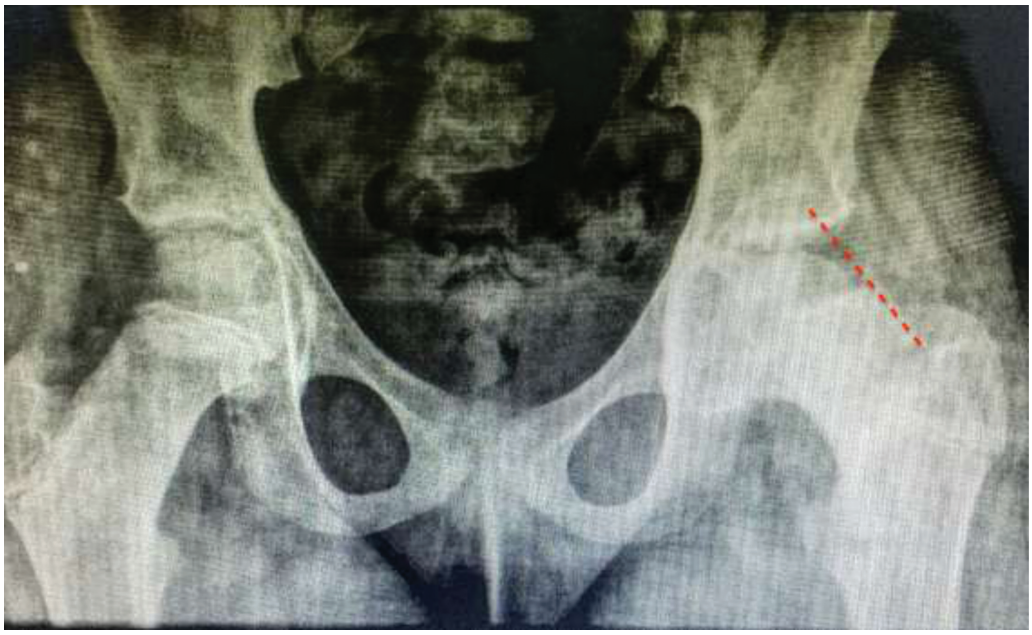

**Fig. 1** Frontal radiography demonstrating slipping of side E and Trethowan sign.

## Introduction

Epiphysiolysis is one of the main diseases that affect the adolescent's hip and is characterized by femoral metaphysary slipping, non-traumatic, anterolaterally in relation to the epiphysis, which remains centered on the acetabulum.[1] It mainly affects the age group between 9 and 16 years (mean of 12).[1–4] It occurs when a fragile physis (histological, vascular, and endocrine factors) is submitted to mechanical overload.[4,5]

It has a very varied incidence in the literature, from 0.03/10,000 to 5/10,000 depending on the work, gender, region, and ethnicity.[1–4,6,7] Epiphysiolysis has a higher incidence in males (2:1.4) compared to female patients, and it is more incident in African American and Hispanics.[4,7]

Simultaneous bilateral occurrence is 7%[7] and can reach 21% asynchronously. Approximately 90% of contralateral slips occur within 18 months,[4] and they are more incident when associated with endocrine diseases. In these cases, contralateral fixation is indicated, even when the patient is asymptomatic.[2,4,5]

Clinically, the patient presents with complaint of hip or knee pain and difficulty walking, commonly insidious and rarely acute. Often, the diagnosis is late or neglected by the confounding and uncharacteristic clinical picture, causing a late treatment and worse prognosis.[4,8] On physical examination, there is limitation of flexion and internal rotation, and Drehmann sign (abduction and external rotation during passive flexion)[4] is characteristic.

On radiography (front and Lauenstein), slipping is observed in the more advanced cases, and, in the initial cases, there are indicative signs such as enlargement and physis irregularity. Two radiographic methods are described for the diagnosis and measurement of slipping: The Trethowan sign —when the line on the upper surface of the femoral neck (Klein line) does not intersect with the physis (►**Figure 1**), and measurement of the Southwick angle (between head and diaphysis in the profile) (►**Figure 2**).[4,8] Magnetic resonance imaging is recommended for initial cases or diagnostic doubt.

Epiphysiolysis can be classified in 3 ways: in terms of duration, it can be acute $< 3$ weeks or chronic $> 3$ weeks; symptom-based (Loder classification): stable—patient can walk, or unstable—patient cannot walk even with the aid of crutches,[2,4] and the radiographic classification is done by degree of slippage.[2,4]

Of multifactorial etiology, numerous diseases or characteristics are associated with this condition: obesity, renal osteoarthritis, hypothyroidism, hypogonadism, hyperparathyroidism,[2–4] increase in femoral retroversion,[1,4] acetabular retroversion,[4] increase in fissary obliqueness,[4] and socioeconomic deprivation.[9]

The recommended treatment is in situ fixation, causing epiphysis. When slipping reduction occurs, there is an increased occurrence of avascular necrosis of the femoral head (ANFH) and condrolysis,[4,6] with these being the most common complications of the disease. After in situ fixation, the rate of ANFH reported in the literature is 1.5%.[4,6] A total of 10% of the patients will present with severe osteoarthrosis after 20 years of age.[4,6]

The occurrence is rare in adults, with only a few reports in the literature. When it happens, there is always an association with some disease that delays sexual maturation and, consequently, fissure closure.[10] The most commonly described diseases associated with epiphysiolysis in adults are hypopituitarism, hypothyroidism, and hypogonadism.[10]

The aim of the present study is to report a case of epiphysiolysis in a 22-year-old patient with sexual developmental delay and with a diagnosis of congenital hypogonadotropic hypogonadism. Epiphysiolysis is a rare disease

 © 2021. Sociedade Brasileira de Ortopedia e Traumatologia. All rights reserved.

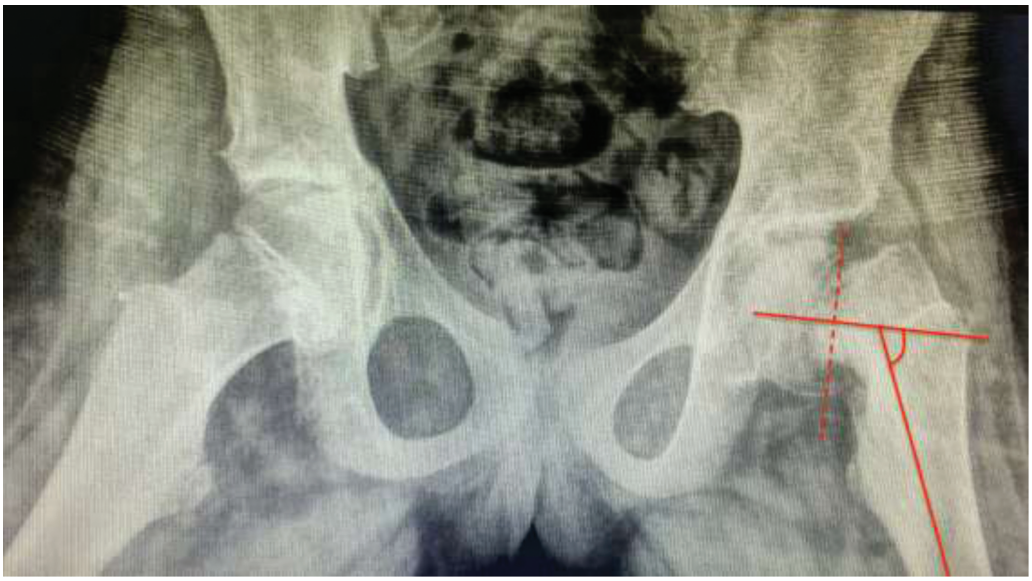

**Fig. 2** Pelvic radiography—Lauenstein incidence with measurement of the Southwick angle on the affected side.

characterized by the absence of pubertal development, due to problems in the production or secretion of gonadotrophy-releasing hormone (GnRH). Lab tests show low concentrations of sex steroids (testosterone/estradiol) and reduced or normal values of pituitary gonadotropins (LH and FSH). The other hypothalamic hormones and hypothalamic-pituitary magnetic resonance imaging are normal. When associated with anosmia, it is called Kallmann syndrome.

## Case Report

A 22-year-old female patient sought orthopedic care complaining of insidious hip pain for 3 months, denying trauma. She reported having looked for care twice before, when she was treated with medication, without tests. She denied pain in the other hip.

As personal history, she reported that she did not have menarche and that she was undergoing outpatient follow-up with a gynecologist because she presented "infant uterus". The patient also presented undeveloped sexual secondary characters.

She presented the left lower limb rotated externally and pain in passive mobilization of the hip with positive Drehmann maneuver.

Pelvic radiography (►**Figures 1** and **2**) showed the proximal femoral physis still open and slipping of the left side.

Surgical treatment with percutaneous fixation with canulate screw (►**Figure 3**) was chosen. With the risk of contralateral occurrence, fixation was suggested; however, the patient refused it.

During follow-up, the patient presented previous test results, with a diagnosis of congenital hypogonadotropic hypogonadism. The pelvic ultrasound showed a uterus with very small dimensions $2.3 \times 0.9 \times 1.5$ cm (volume of 2 $cm^2$)—infant dimensions. The laboratory tests showed prolactin, TSH, free T4 and GH—within normal values. Total testosterone below 10 ng/dL, LH $<$ 0.07 mUI/mL, FSH $<$ 0.30mUI/mL and estradiol $<$ 11.80 pg/mL—all values well below normal.



**Fig. 3** Postoperative radiography – frontal incidence, fixation with canulate screw.

 © 2021. Sociedade Brasileira de Ortopedia e Traumatologia. All rights reserved.

After 3 months, she presented physeal closure of the operated side and up to 6 months of follow-up, there were no complaints of pain in the contralateral side.

## Discussion

Epiphysiolysis is extremely rare in adults, and, when it occurs, it is associated with some disease that slows sexual development and physeal closure.

Because it is a rare diagnosis, and exclusion is often neglected, its treatment is delayed, causing the real prevalence in the adult population to be unknown/underestimated. It is believed that many cases of hip osteoarthrosis in young patients are sequelae of undiagnosed cases.[5]

A review of the literature was performed with the terms: *epiphysiolysis*, *slipped femoral capital epiphysis*, *delayed femoral capital epiphysis*, *slipped femoral capital epiphysis in adults*. In the world literature, there are 63 case reports in the adult population, and none in the Brazilian literature.

The diseases most commonly associated with the occurrence of epiphysiolysis in the adult population described in the case reports are: hypothesia/craniopharyngioma diseases, hypothyroidism, hypogonadism, meeting other previous reviews.

Two previous reviews of the literature were performed. Macía-Villa et al.[5] reported a case in a 47-year-old woman with chronic corticosteroid use and conducted a literature review finding 60 cases; 17 with hypoesthetic disorders, 7 with unspecified endocrine causes, 5 with hypothyroidism, and 4 cases of hypogonadism.

Speirs et al.[10] also surveyed the literature and found associations similar to those of the previous review.

This case report presents a rare disease in the adult population associated with congenital hypogonadotropic hypogonadism.

The possibility of this diagnosis must be considered in adults with hip pain, mainly chronic, with a history of endocrine diseases or alteration of secondary sexual characteristics.

Authors' contribution

**A. P. N.** was responsible for the design and design, writing of the article and final approval of the version submitted.

**C. T. K.** was responsible for the design and design, writing of the article and final approval of the version submitted.

Conflict of Interests

The authors declare that there is no conflict of interests.

## References

1 Mathew SE, Larson AN. Natural History of Slipped Capital Femoral Epiphysis. J Pediatr Orthop 2019;39(6, Supplement 1 Suppl 1): S23–S27
2 Otani T, Kawaguchi Y, Marumo K. Diagnosis and treatment of slipped capital femoral epiphysis: Recent trends to note. J Orthop Sci 2018;23(02):220–228
3 Huang YF, Wang LS, Zhang S, Gao YH, Liu JG, Qi X. Slipped capital femoral epiphysis in an adult with congenital hypopituitarism: A case report. Medicine (Baltimore) 2019;98(03):e13997
4 Georgiadis AG, Zaltz I. Slipped capital femoral epiphysis: how to evaluate with a review and update of treatment. Pediatr Clin North Am 2014;61(06):1119–1135
5 Macía-Villa CC, Sanchez-Lite I, Medina-Luezas J. Slipped capital femoral epiphysis in adults: case report and review of literature. Reumatismo 2016;68(01):40–47
6 Naseem H, Chatterji S, Tsang K, Hakimi M, Chytas A, Alshryda S. Treatment of stable slipped capital femoral epiphysis: systematic review and
7 Herngren B, Stenmarker M, Vavruch L, Hagglund G. Slipped capital femoral epiphysis: a population-based study. BMC Musculoskelet Disord 2017;18(01):304
8 Schur MD, Andras LM, Broom AM, et al. Continuing Delay in the Diagnosis of Slipped Capital Femoral Epiphysis. J Pediatr 2016; 177:250–254
9 Perry DC, Metcalfe D, Costa ML, Van Staa T. A nationwide cohort study of slipped capital femoral epiphysis. Arch Dis Child 2017; 102(12):1132–1136
10 Speirs JN, Morris SC, Morrison MJ III. Slipped Capital Femoral Epiphysis in an Adult Patient With Kabuki Syndrome. J Am Acad Orthop Surg Glob Res Rev 2019;3(10):e19.00084

 © 2021. Sociedade Brasileira de Ortopedia e Traumatologia. All rights reserved.