Article published online: 2021-04-19

THIEME OPEN ACCESS

Case Report

Recurrent Anterior Shoulder Dislocation After Trauma with Coracoid Apophysis Fracture - A Rare Association*

Luxação anterior recorrente do ombro após traumatismo com fratura apófise Coracoide – Uma associação rara

Filomena Ferreira[1] Ricardo Branco[1] Rómulo Silva[1] Margarida Areias[1] Carolina Oliveira[1] Norberto Silva[1]

[1] Department of Orthopedics and Traumatology, Unidade Local de Saúde Alto Minho, Viana do Castelo, Portugal

Address for correspondence Filomena Ferreira, MD, Internal Orthotics and Traumatology, Unidade Local de Saúde Alto Minho, Viana do Castelo, Portugal (e-mail: afilomenaf@gmail.com).

Rev Bras Ortop

Abstract

Anterior dislocations represent about 96% of total shoulder dislocations, with recurrence/instability being more common in young patients. Injury of other shoulder structures is frequent, namely bony Bankart lesion. However, the association with coracoid apophysis fracture is very rare.

The present article describes the clinical case of a 67-year-old man who presented to the emergency department with complaints of persistent omalgia, with acute episodes, beginning after a fall from his own height. The patient also presented history of shoulder trauma 3 months earlier, which was evaluated at another hospital. Shoulder anterior dislocation was observed radiographically, and the computed tomography (CT) confirmed bone erosion of the anteroinferior part of the glenoid (bone loss of about 50% of the anteroposterior diameter in the lower region of the glenoid), with almost complete resorption of the bony Bankart lesion (apparent in later analysis of the radiography of the initial traumatic episode). Connectedly, a transverse fracture of the coracoid apophysis (type II in the Ogawa classification) was diagnosed. The patient was submitted to surgical treatment, with anterior bone stop confection using the remnant of the fractured fragment of the coracoid supplemented by tricortical autologous iliac graft, fixed with cannulated screws (according to the Bristow-Latarjet and Eden-Hybinett techniques).

In the postoperative follow-up, a good functional result was observed, with no new episodes of dislocation and no significant pain complaints.

Keywords

- shoulder dislocation
- shoulder fractures
- coracoid process

* *Work developed in the Department of Orthopedics and Traumatology of Unidade Local de Saude Alto Minho, Viana do Castelo, Portugal.*

received
May 27, 2020
accepted after revision
December 1, 2020

DOI https://doi.org/10.1055/s-0041-1724088.
ISSN 0102-3616.

© 2021. Sociedade Brasileira de Ortopedia e Traumatologia. All rights reserved.
This is an open access article published by Thieme under the terms of the Creative Commons Attribution-NonDerivative-NonCommercial-License, permitting copying and reproduction so long as the original work is given appropriate credit. Contents may not be used for commercial purposes, or adapted, remixed, transformed or built upon. (https://creativecommons.org/licenses/by-nc-nd/4.0/)

Thieme Revinter Publicações Ltda., Rua do Matoso 170, Rio de Janeiro, RJ, CEP 20270-135, Brazil

A rare association of shoulder lesions is described, and the challenge of their treatment is highlighted, given the late diagnosis, as in the case presented.

Resumo

As luxações anteriores representam cerca de 96% do total de luxações do ombro, sendo a recidiva/instabilidade mais comum em pacientes jovens. A lesão de outras estruturas do ombro é frequente, nomeadamente a lesão óssea de Bankart. Contudo, a associação com a fratura da apófise coracoide é muito rara.

Este artigo descreve o caso clínico de um homem de 67 anos que recorreu ao serviço de urgência com queixas de omalgia persistente, com episódios de agudização, iniciados após queda da própria altura. O paciente apresentava ainda histórico de trauma do ombro 3 meses antes, avaliado em outro hospital. A luxação anterior do ombro foi constatada radiograficamente, e a tomografia computorizada (TC) do ombro confirmou erosão óssea da vertente anteroinferior da glenoide (perda óssea de cerca de 50% do diâmetro anteroposterior na região inferior da glenoide), com reabsorção quase completa de lesão óssea de Bankart (aparente em análise a posteriori da radiografia do episódio traumático inicial). Associadamente, foi diagnosticada uma fratura transversa da apófise coracoide (tipo II da classificação de Ogawa). O paciente foi submetido ao tratamento cirúrgico, com confecção do batente ósseo anterior utilizando remanescente do fragmento fraturado do coracoide suplementado por enxerto autólogo tricortical do ilíaco, fixados com parafusos canulados (de acordo com as técnicas de Bristow-Latarjet e Eden-Hybinett).

No seguimento pós-operatório, foi observado um bom resultado funcional, sem novos episódios de luxação e sem queixas álgicas significativas.

Descreve-se uma associação rara de lesões do ombro, e salienta-se o desafio do tratamento das mesmas dado o seu diagnóstico tardio, como no caso apresentado.

Palavras-chave

- luxação do ombro
- fraturas do ombro
- processo coracoide

Introduction

Anterior dislocations represent about 96% of total shoulder dislocations. Dislocation recurrence is very common in young patients and may occur in up to 80% of cases.[1] However, in patients over 40 years of age, recurrence occurs in only about 10% of patinets.[2] In cases of recurrent dislocation, injury of the stabilizing structures of the glenohumeral joint (static and/or dynamic) occurs, and the lesion of the anteroinferior *labrum* of the glenoid with bone component (Bony Bankart lesion) is a well-known association.[3] Surgical treatment of this type of lesion varies from Bankart reinsertion to the creation of anterior bone increases using coracoid apophysis, autologous or heterologous graft.[4]

Coracoid apophysis fractures are uncommon and difficult to diagnose, constituting about 3 to 13% of shoulder blade fractures, which, in turn, represent less than 1% of total fractures.[5]

Most of the described coracoid fractures occur following seizures, and their association with episodes of anterior shoulder dislocation is extremely rare; as such, there are very few reports about the treatment performed.

The present study describes the case of a patient with recurrent dislocation/shoulder instability resulting from a Bony Bankart lesion and coracoid apophysis fracture, diagnosed late, and its implications on the treatment performed.

Clinical Case

The case describes a 67-year-old male patient with no relevant pathological history, namely epilepsy.

The patient was evaluated by the authors in the emergency department (ED) for acute persistent right shoulder pain, with multiple similar previous episodes of pain worsening. The onset of shoulder pain was 2 months before presentation to the authors, following fall from his own height with trauma of the upper limb in abduction and extension; at that time, the patient was evaluated at another institution. No other traumatic episodes followed.

He presented with the upper limb suspended in an antalgic position in slight external rotation. With positive hanger sign.

Anterior shoulder dislocation was verified radiologically on the date of the evaluation by the authors (►**Figure 1**), and reduction maneuver was performed.

Objectively with great shoulder instability, anterior apprehension test and load and shift test positive. No neurological deficits.

The computed tomography (CT) of the shoulder showed significant bone erosion of the anteroinferior part of the glenoid, with bone loss of about 50% of the anteroposterior diameter in the lower region of the glenoid (►**Figure 2**) and infracentimetric focal depression in the posteroexternal aspect of the humeral head (Hill-Sachs lesion).

 © 2021. Sociedade Brasileira de Ortopedia e Traumatologia. All rights reserved.

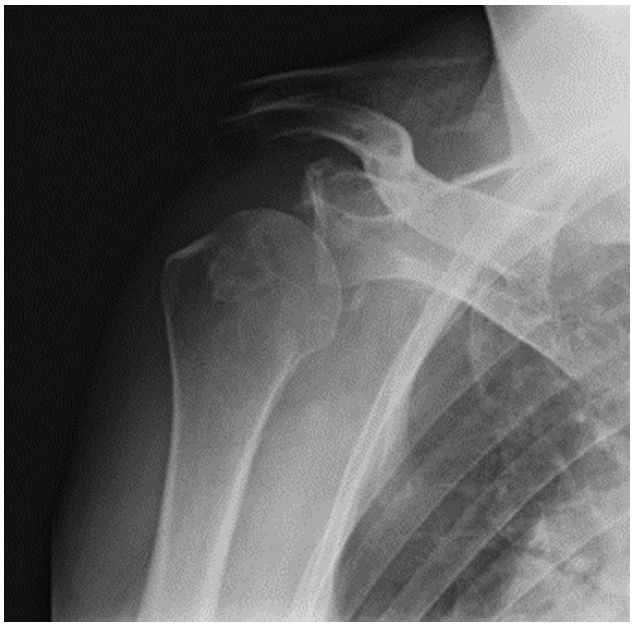

Fig. 1 Anterior shoulder dislocation (radiography of the ER episode used in the evaluation by the authors).



Fig. 3 Intraoperative image of the coracoid fragment fixation and iliac tricortical graft to the anteroinferior part of the glenoid.

In a later analysis of the radiography of the initial traumatic episode (previously evaluated at another institution), a fragment of bony Bankart lesion was observed; however, without anterior dislocation of the shoulder (by probable spontaneous reduction). In the CT performed by the authors, almost complete bone resorption of the bony Bankart fragment could be observed (►**Figure 2**).

Connectedly, a transverse fracture of the coracoid apophysis (type II in the Ogawa classification) was diagnosed, with partial resorption of the fragment.

Given the instability with recurrent episodes of dislocation and severe pain, surgical treatment was proposed. A deltopectoral approach was performed to explore the glenohumeral joint, removal of loose bodies and confirmed a small coracoid fragment attached to the conjoint tendon.

An anterior bone block was made using coracoid fragment (fixed with cannulated screw on the anteroinferior edge of the glenoid – at 5 o'clock), supplemented by osteosynthesis of tricortical graft harvested from ipsilateral iliac (with 2.5cm x 3cm) with 2 screws in the inferior 2/3 of the glenoid (►**Figures 3** and **4**).

No complications were reported in the postoperative period. The patient completed 4 weeks of immobilization and subsequent physiatric treatment.

In the postoperative follow-up, a good functional result was observed, with no new episodes of dislocation and no significant pain complaints. The Disabilities of the Arm, Shoulder and Hand (DASH) score before the surgery was 51.6 and 1 year after surgery it was 18.3.

One year after surgery, range of motion with limitation of 2 vertebrae of internal rotation, capable of 20° of external rotation and active anterior elevation of 100°. The anterior and posterior apprehension, load and shift and groove tests were negative.

Radiographically, we could verify bone block consolidation in the glenoid, maintaining adequate positioning of the

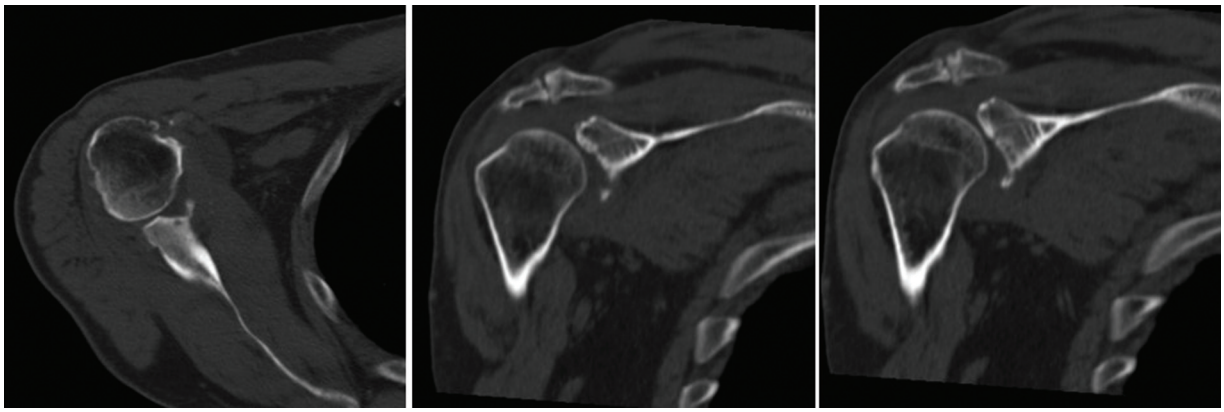

Fig. 2 Computed tomography images - Bony Bankart lesion of about 50% of the anteroinferior part of the glenoid with bone fragmentation.

 © 2021. Sociedade Brasileira de Ortopedia e Traumatologia. All rights reserved.



Fig. 4 Shoulder radiography after surgery.

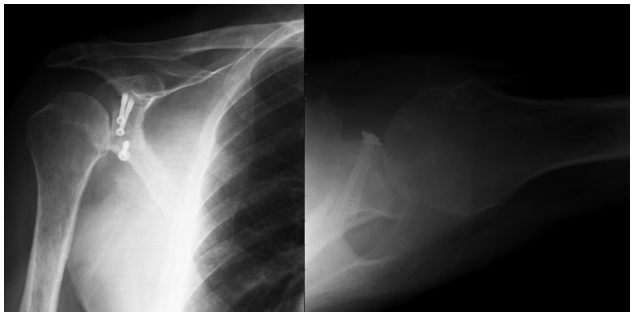

Fig. 5 Shoulder radiography 1 year after surgery.

canulate screws. There were slight degenerative changes of the glenohumeral joint, especially in the lower part (Grade I of the Samilson and Prieto classification) (►**Figure 5**).

Discussion

In the case herein described, there are several factors that hinder the creation of shoulder stability:

1. Extensive bone destruction of the glenoid (about 50% of the anteroposterior diameter in the lower part of the glenoid) by bony Bankart lesion and progression of erosion by repeated episodes of dislocation are well documented as factors of increased instability and difficulty in treatment.[6]
2. The Bankart bone fragment was unfit for osteosynthesis, due to its resorption and fragmentation from the initial traumatic episode to diagnosis.
3. The coracoid fracture, with resorption of a substantial part of the bone fragment, made the creation of bone block with the coracoid insufficient to create stability in the shoulder of this patient.

In this context, the authors chose to combine the techniques of Bristow-Latarjet and Eden-Hybinett, already described. Thus, glenohumeral stability was obtained by the association of the bone block effect and increased glenoid joint surface created by the iliac tricortical graft fragment,[7] with the mechanical stabilizing effect of the coracoid apophysis and also an important dynamic stabilizer of the conjoint tendon.[8]

Osseocartilaginous lesions resulting from previous recurrent dislocations and not perfectly anatomical congruence of the glenoid after surgery lead to progressive degenerative changes, especially in the humeral head. This complication is more common in Eden-Hybinett procedures compared to Bristow-Latarjet technique alone.[9] In this case, the degree of osteoarthrosis 1 year after surgery is coincident with that described in the literature, grades I and II in the Samilson and Prieto classification, however with variable follow-up periods, making comparison difficult.[6]

The stability achieved in the patient described is corroborated by the low recurrence rate of dislocation after surgical treatment with anterior bone augmentation. The reported incidence is up to about 4.9% (4 out of 102 patients, all associated with traumatic episodes or seizures, after Latarjet surgery).[6,10] No description was found in the literature of the recurrence rate with the association of the procedures described.

This case report presents an unusual association of fractures, emphasizing the importance of a high rate of initial clinical suspicion and detailed radiological observation for the diagnosis of all lesions present.

In addition, there is an association of surgical techniques, whose therapeutic success, although well documented when used isolated, deserves further study when used together to corroborate the good results obtained in this case and may be a procedure to be considered in similar future cases.

Conflict of Interests

The authors declare that there is no conflict of interests.

References

1 Colbenson K, Henry PDG, Kuhn JE. The True Recurrence Rate and Factors Predicting Recurrent Instability After Nonsurgical Management of Traumatic Primary Anterior Shoulder Dislocation: A Systematic Review. Arthrosc J Arthrosc Relat Surg 2018;32(12): 2616–2625
2 Owens BD, Duffey ML, Nelson BJ, DeBerardino TM, Taylor DC, Mountcastle SB. The incidence and characteristics of shoulder instability at the United States Military Academy. Am J Sports Med 2007;35(07):1168–1173
3 Patel RM, Amin NH, Lynch TSMA, Miniaci A. Management of bone loss in glenohumeral instability. Orthop Clin North Am 2014;45 (04):523–539
4 Lavery KP, Mchale KJ, Rossy WH, Sanchez G, Provencher MT. Bony Augmentation for Anterior and Posterior Glenohumeral Instability in the Contact Athlete. Oper Tech Sports Med 2018;24(04): 300–309
5 McGinnis M, Denton JR. Fractures of the scapula: a retrospective study of 40 fractured scapulae. J Trauma 1989;29(11): 1488–1493

 © 2021. Sociedade Brasileira de Ortopedia e Traumatologia. All rights reserved.

6 Beran MC, Donaldson CT, Bishop JY. Treatment of chronic glenoid defects in the setting of recurrent anterior shoulder instability: a systematic review. J Shoulder Elbow Surg 2010;19(05):769–780
7 Montgomery WH Jr, Wahl M, Hettrich C, Itoi E, Lippitt SB, Matsen FA III. Anteroinferior bone-grafting can restore stability in osseous glenoid defects. J Bone Joint Surg Am 2005;87(09):1972–1977
8 Yamamoto N, Muraki T, An KN, et al. The stabilizing mechanism of the Latarjet procedure: a cadaveric study. J Bone Joint Surg Am 2013;95(15):1390–1397
9 Longo UG, Loppini M, Rizzello G, Ciuffreda M, Maffulli N, Denaro V. Latarjet, Bristow, and Eden-Hybinette procedures for anterior shoulder dislocation: systematic review and quantitative synthesis of the literature. Arthroscopy 2014;30(09):1184–1211
10 Burkhart SS, De Beer JF, Barth JR, Cresswell T, Roberts C, Richards DP. Results of modified Latarjet reconstruction in patients with anteroinferior instability and significant bone loss. Arthroscopy 2007;23(10):1033–1041

 © 2021. Sociedade Brasileira de Ortopedia e Traumatologia. All rights reserved.