Article published online: 2021-04-19

Aggressive Diffuse Intraosseous Hemangioma: Case Report

Hemangioma intraósseo difuso agressivo: Relato de caso

Monique Alves[1] Marcus Sofia Ziegler[1] Fernando Augusto Dannebrock[1] Erasmo de Abreu Zardo[1] Carlos Marcelo Donazar Severo[1]

[1] Orthopedics and Traumatology Service, Hospital São Lucas, Pontifícia Universidade Católica do Rio Grande do Sul, Porto Alegre, RS, Brazil

Rev Bras Ortop

Address for correspondence Monique Alves, Orthopedics and Traumatology Service, Pontifícia Universidade Católica do Rio Grande do Sul, Av. Ipiranga, 6690, Jardim Botânico, Porto Alegre, RS, 90610-000, Brazil (e-mail: ma.moniquealves@gmail.com).

Abstract

Vertebral hemangioma is a benign vascular tumor that is usually asymptomatic and is discovered incidentally on imaging. When symptomatic, the most frequent presentation occurs in the form of vague back pain of insidious onset and, in rare cases, may be associated with root or spinal compression, causing sensory and motor deficits. The authors report the case of a 33-year-old man, previously healthy, with a diagnosis of thoracic spine hemangioma at multiple levels, in the sternum, in the scapula and in the costal arches; all lesions were symptomatic, and surgical intervention was required; one of the lesions at the thoracic spine level evolved with spinal compression and acute neurological deficit, requiring urgent surgical intervention. Intraosseous hemangiomas represent $< 1\%$ of all bone tumors, having few reports of multifocal presentation in the axial and appendicular skeleton. In the literature review, no other case of aggressive multifocal intraosseous hemangioma with this presentation was found, including associated neurological symptoms in the same case.

Keywords

- bone diseases
- drug therapy
- hemangioma
- spinal diseases

Resumo

O hemangioma vertebral, um tumor vascular benigno, geralmente é assintomático e descoberto incidentalmente em exames de imagem. Quando sintomático, a apresentação mais frequente ocorre sob a forma de dorsalgia vaga de início insidioso e, em raros casos, pode estar associado a compressão radicular ou medular, causando déficit sensitivo e motor. Os autores relatam o caso de um homem de 33 anos, previamente hígido, com diagnósticos de hemangioma na coluna torácica em múltiplos níveis, no esterno, na escápula e nos arcos costais; todas as lesões eram sintomáticas e houve necessidade de intervenção cirúrgica, sendo que uma das lesões ao nível da coluna torácica evoluiu com compressão medular e déficit neurológico agudo, com necessidade de intervenção cirúrgica de urgência. Os hemangiomas intraósseos representam $< 1\%$ de todos os tumores ósseos, e a apresentação multifocal no esqueleto axial e apendicular apresenta poucos relatos. Na revisão bibliográfica, não foi encontrado outro caso de hemangioma intraósseo multifocal agressivo com tal apresentação, inclusive com sintomas neurológicos associados em um mesmo caso.

Palavras-chave

- doenças ósseas
- tratamento farmacológico
- hemangioma
- doenças da coluna vertebral

received
August 15, 2020
accepted
October 2, 2020

DOI https://doi.org/10.1055/s-0040-1722585.
ISSN 0102-3616.

© 2021. Sociedade Brasileira de Ortopedia e Traumatologia. All rights reserved.
This is an open access article published by Thieme under the terms of the Creative Commons Attribution-NonDerivative-NonCommercial-License, permitting copying and reproduction so long as the original work is given appropriate credit. Contents may not be used for commercial purposes, or adapted, remixed, transformed or built upon. (https://creativecommons.org/licenses/by-nc-nd/4.0/)

Thieme Revinter Publicações Ltda., Rua do Matoso 170, Rio de Janeiro, RJ, CEP 20270-135, Brazil

Introduction

Hemangioma is a benign lesion in the group of vascular lesions, consisting of neoformed blood vessels. Some of these lesions are malformations, while others, due to the growth with neoplasia characteristics, are considered true benign tumors.[1] The most common locations of hemangiomas are the skull, where they can produce the classical image in "sun rays", and the axial skeleton, usually without any clinical symptomatology.[1] Most often, hemangiomas do not require treatment, but rather periodic follow-up.

The mean age of the patients is 40 years old, being more frequent in women, in the proportion of 3:2.[1,2] In plain radiography, hemangiomas are characterized by parallel vertical trabeculates in vertebral bodies. Computed tomography (CT) reveals the presence of thick trabeculae and radiotransparent areas, and magnetic resonance imaging (MRI) is highly sensitive and specific, presenting hyperintense signs on T1 and T2.[1]

We describe a rare case of aggressive hemangiomatosis in a young patient in order to demonstrate its clinical presentation, imaging, as well as the evolution of the patient with the treatment performed. Finally, we alert to the diagnosis of hemangioma as a differential diagnosis in multiple and also aggressive bone lesions.

Case Report

Male patient, 33 years old, metallurgical, previously healthy, with a history of chronic back pain without irradiation, previous thoracic spine MRI with a finding suggestive of hemangioma in T2, T3, T4, T9 and L1 (►**Figure 1**). It evolved with worsening of back pain and bilateral irradiation to the lower limbs. The patient underwent a new MRI after worsening of symptoms, about 1 year after the first examination, and an increase in the previous injury in T3 was visualized with invasion of the medullary canal, causing spinal cord compression (►**Figure 2**); the patient was then forwarded to our service.

On examination, the patient presented paresthesia of the lower limbs, clonus and ataxic gait. Due to the aggressiveness of the lesion and to the acute neurological symptoms, hospitalization and surgical intervention were indicated. Spinal decompression associated with T2-T5 segment arthrodesis was performed. Hemangioma of the vertebral body was found by pathological examination. Twenty sessions of radiotherapy were performed after the surgery and a semiannual follow-up was maintained, with good evolution.

The other hemangiomas of the vertebral bodies described remained with conservative treatment, follow-up with imaging, since they showed no growth or symptoms (►**Figure 3**).

Two years later, the patient complained of significant pain in the right costal arches, with radiography without special characteristics. Bone scintigraphy was requested, which showed uptake in the 4th and 6th costal arches on the right. Complement with MRI and CT and resection of 4th and 6th costal arches on the right was performed and confirmed by anatomopatology (►**Figure 4A**).



Fig. 1 Sagittal section column magnetic resonance imaging demonstrating hemangiomas at the T2,T3, T4, T9 and L1 levels.

During the follow-up, 3 years after the intervention at the costal arches level, the patient presented with pain in the right shoulder, with investigation diagnosing a lesion in the right scapula (►**Figure 5**); resection was indicated, and the pathological report resulted in another hemangioma.

In the same year, the patient complained of anterior chest pain, including seeking an emergency department due to the intensity of the symptoms. An MRI was performed, which presented a lesion on the sternum (►**Figure 4B**). Resection was indicated, and the material was sent to pathological examination and confirmed a new hemangioma.

Discussion

The diffuse presentation of intrabone hemangioma is uncommon. When reported, it usually presents in a region, such as several vertebral bodies, but it is not usually distributed in different places of the body.[1,4]

The most common locations of hemangiomas are the skull and axial skeleton. In the spine, thoracic localization is more common in the middle and lower regions, followed by the lumbar region, occurring more rarely in the cervical region.[1,2]

Treatment of intraosseous hemangioma depends on the symptoms in each affected region.[4]

Most vertebral hemangiomas are latent and do not require specific treatment; few cases evolve with symptoms and, when those present, they are usually limited to the presence

 © 2021. Sociedade Brasileira de Ortopedia e Traumatologia. All rights reserved.

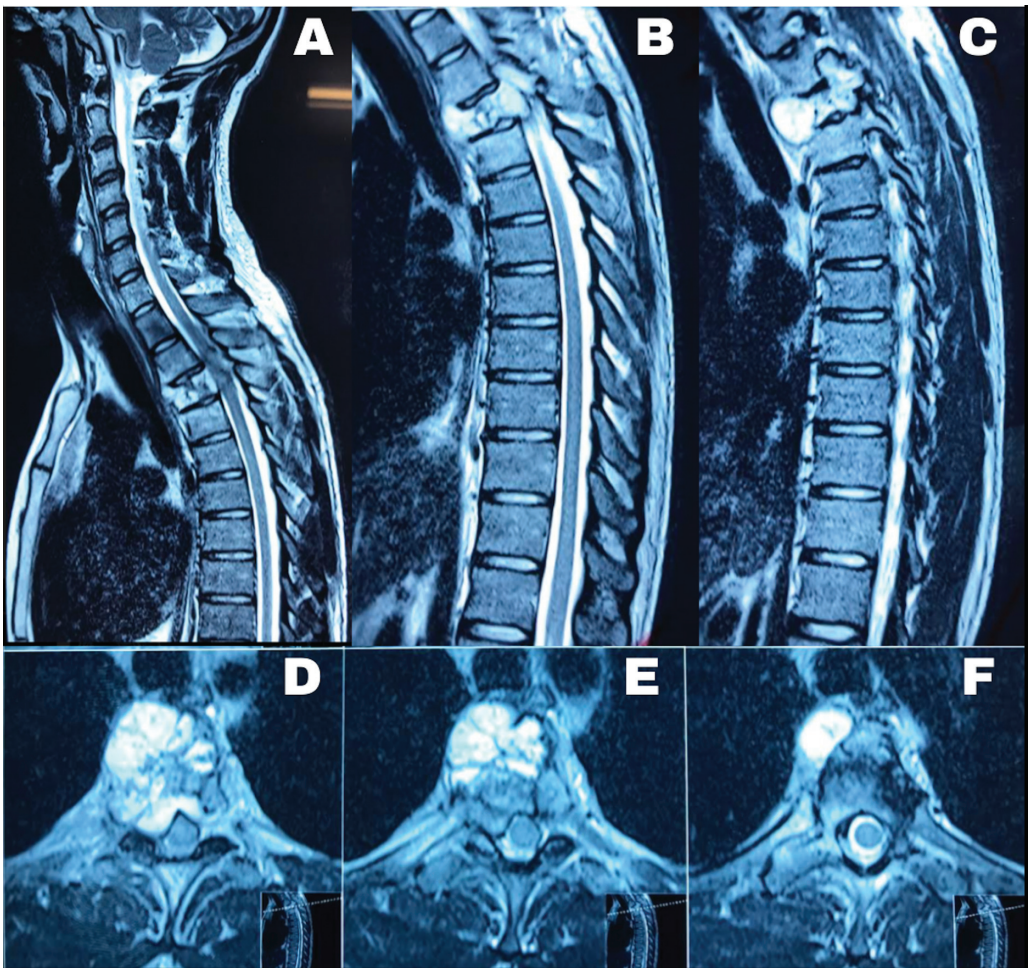

Fig. 2 Magnetic resonance imaging, sagittal section (A,B and C) demonstrating an increase in the dimensions of the lesion at the T3 level with invasion of the medullary canal; axial section (D,E and F) at the level of the lesion evidencing medullary dysmorphism and compression of the medullary canal.

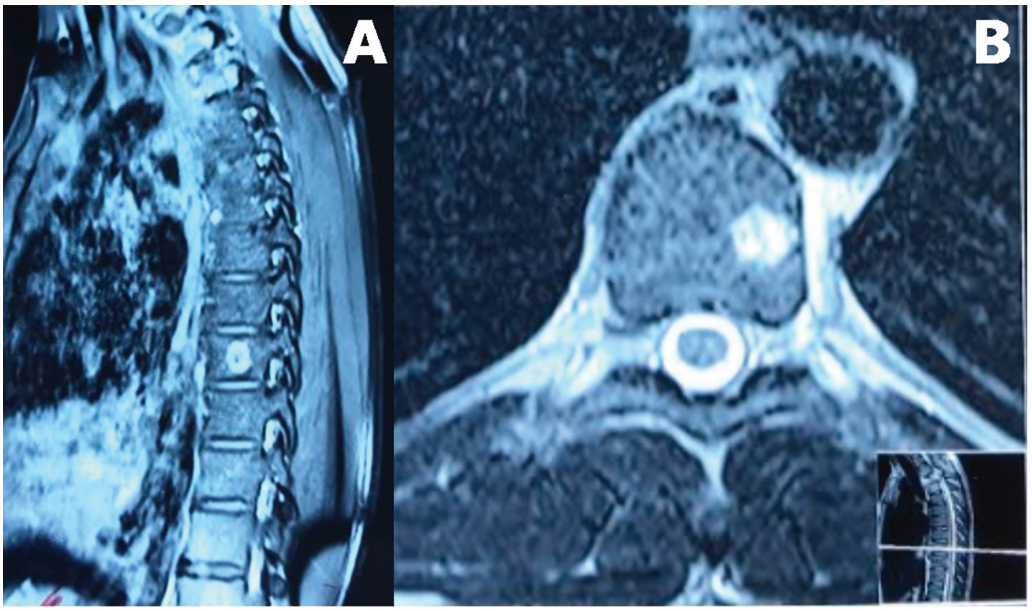

Fig. 3 Sagittal (A) and axial (B) magnetic resonance imaging cutting demonstrating nodular hemangioma at the T9 level.

 © 2021. Sociedade Brasileira de Ortopedia e Traumatologia. All rights reserved.

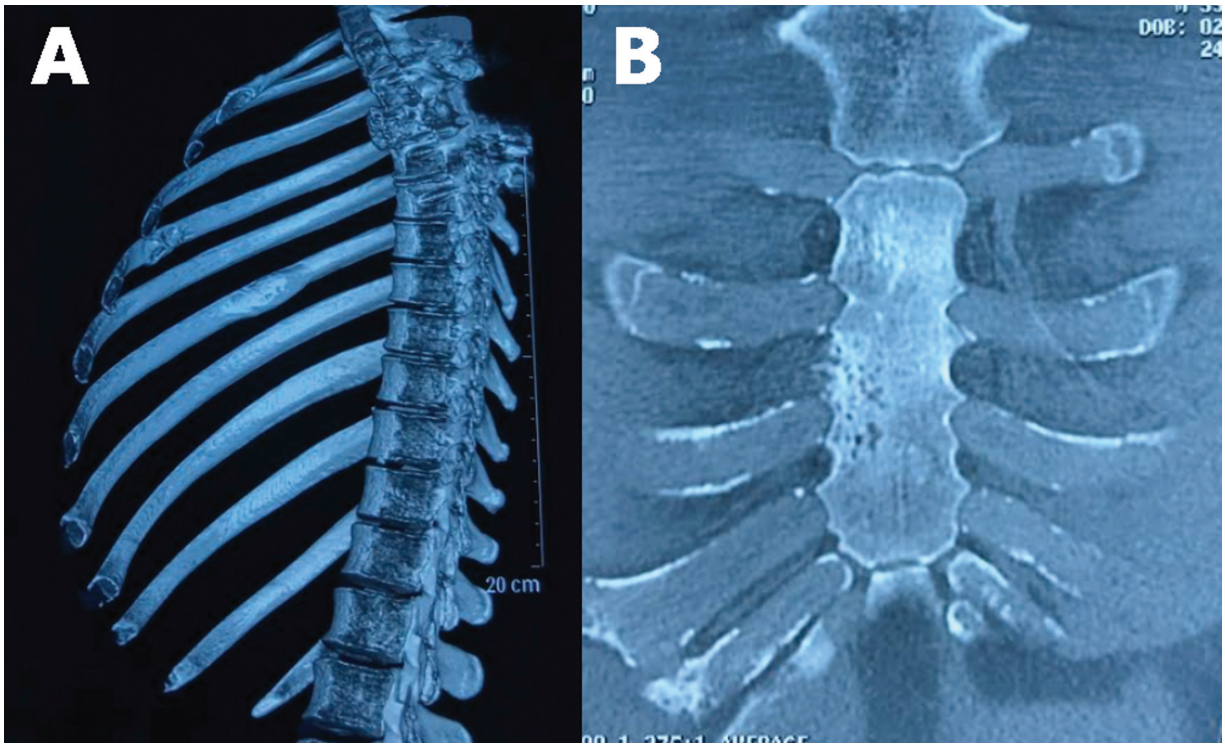

Fig. 4 Computed tomography reconstruction (A) with hemangioma in the 4th and 6th costal arches; computed tomography of the sternum (B) demonstrating the initial injury.

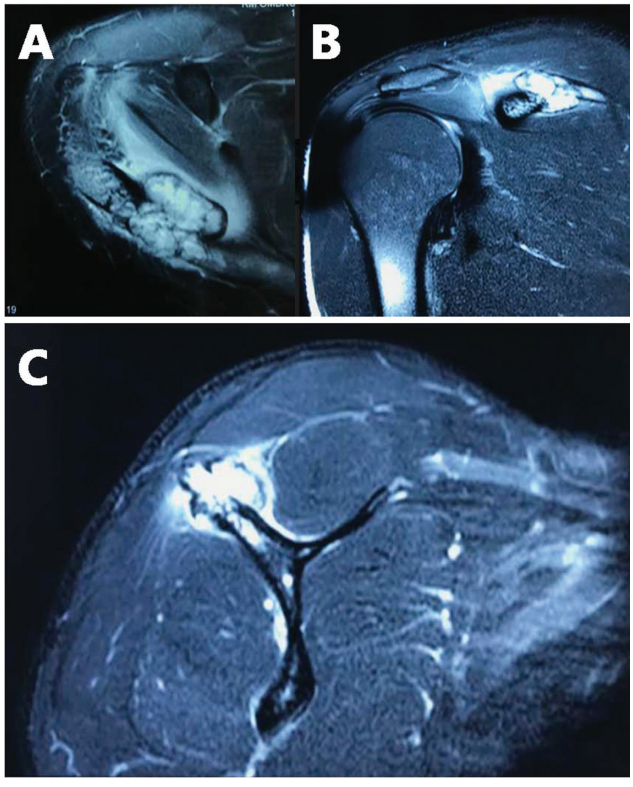

Fig. 5 Axial (A), coronal (B) and sagittal (C) cuts in magnetic resonance imaging of the scapula with an expansive lesion.

of pain. However, in rare cases, they may be aggressive, with neurological deficit due to spinal cord compression.[1,2,5–8]

The evolutionary form of the present case demonstrates aggressive and nonconcomitant diffuse lesions in a symptomatic male patient, with the appearance of new hemangiomas during follow-up, which were not subject to conservative treatment.

The therapeutic modalities are broad: radiation therapy, arterial embolization, ligation of nutrient vessels, decompressive surgery for spine and tumor resection.[8,9] In cases of spinal cord compression, decompressive surgery followed or not by radiotherapy has been the treatment of choice.[3,10] Treatment options can be used alone or associated,[9] varying according to the symptoms, on the evolution of the case, and depending on the experience of the attending physician.[1]

Vertebroplasty is also described as a therapeutic modality in cases without neurological deficit to improve pain symptoms, but with less long-term benefit in pain relief.[10]

Radiotherapy can be used to treat vertebral hemangiomas exclusively or associated with surgery.[5]

Conditions associated with back pain and without neurological deficits can be conducted through periodic observation and clinical treatment. In refractory cases, exclusive radiotherapy may be an option for pain control through vascular necrosis and/or an anti-inflammatory effect.[5]

Note

Work developed at the Hospital São Lucas, Orthopedics and Traumatology Service, Pontifícia Universidade Católica do Rio Grande do Sul, Porto Alegre, RS, Brazil.

Conflict of Interests

The authors have no conflict of interests to declare.

 © 2021. Sociedade Brasileira de Ortopedia e Traumatologia. All rights reserved.

References

1 Oliveira RP, Rodrigues NR, France AF, et al. Report of four cases of spinal hemangioma with atypical evolution. Rev Bras Ortop 1996; 31(02):119–124

2 Sari H, Uludag M, Akarirmak U, Ornek NI, Gun K, Gulsen F. Aggressive vertebral hemangioma as a rare cause of myelopathy. J Back Musculoskeletal Rehabil 2014;27(02):125–129

3 Castro DG, Lima RP, Maia MAC, et al. Symptomatic vertebral hemangioma treated with exclusive radiotherapy: case report and literature review. Radiol Bras 2002;35(03):179–181

4 Yao K, Tang F, Min L, Zhou Y, Tu C. Multifocal intraosseous hemangioma: A case report. Medicine (Baltimore) 2019;98(02):E14001

5 Jiang L, Liu XG, Yuan HS, et al. Diagnosis and treatment of vertebral hemangiomas with neurologic deficit: a report of 29 cases and literature review. Spine J 2014;14(06):944–954

6 Chen HI, Heuer GG, Zaghloul K, Simon SL, Weigele JB, Grady MS. Lumbar vertebral hemangioma presenting with the acute onset of neurological symptoms. Case report. J Neurosurg Spine 2007;7 (01):80–85

7 Dickerman RD, Bennett MT. Acute spinal cord compression caused by vertebral hemangioma. Spine J 2005;5(05):582–584, author reply 584

8 Hu W, Kan SL, Xu HB, Cao ZG, Zhang XL, Zhu RS. Thoracic aggressive vertebral hemangioma with neurologic deficit: A retrospective cohort study. Medicine (Baltimore) 2018;97(41): e12775

9 Delabar V, Bruneau M, Beuriat PA, et al. [The efficacy of multimodal treatment for symptomatic vertebral hemangiomas: A report of 27 cases and a review of the literature]. Neurochirurgie 2017;63(06):458–467

10 Acosta FL Jr, Dowd CF, Chin C, Tihan T, Ames CP, Weinstein PR. Current treatment strategies and outcomes in the management of symptomatic vertebral hemangiomas. Neurosurgery 2006;58 (02):287–295, discussion 287–295

 © 2021. Sociedade Brasileira de Ortopedia e Traumatologia. All rights reserved.