Article published online: 2021-09-11

THIEME OPEN ACCESS

Technical Note

Ultrasound-Guided WALANT Technique in Carpal Tunnel Decompression Surgery*

Técnica WALANT guiada por ultrassom na cirurgia de descompressão do túnel do carpo

Sandro B. Moreira[1,2] Danilo C. Chagas[3] Caetano T. Yamashita[3]

[1] Faculdade de Medicina, Universidade de Araraquara/UNIARA, Araraquara, São Paulo, Brazil
[2] Universidade de Araraquara/UNIARA, Araraquara, São Paulo, Brazil
[3] Faculdade de Medicina, Universidade de Araraquara/UNIARA, Araraquara, São Paulo, Brazil

Address for correspondence Sandro Baraldi Moreira, Avenida Osvaldo Gonçalves de Jesus, 387, Araraquara, São Paulo, 14805-396, Brazil (e-mail: sandromoreira50@hotmail.com).

Rev Bras Ortop

Abstract

Carpal tunnel syndrome (CTS) is the most common compressive neuropathy in the human body. Its symptoms result from compression of the median nerve in the carpus. The treatment can be conservative, with medications and/or infiltrations that alleviate the symptoms, or surgical, which is more effective, with decompression of the median nerve by surgical section of the flexor retinaculum of the carpus. The anesthetic technique varies according to the anesthesia method: sedation, venous locoregional anesthesia and, more recently, wide-awake local anesthesia no tourniquet (WALANT), which can be performed by the surgeons themselves. The WALANT technique uses local anesthesia with a vasoconstrictor, and does not require the use of a tourniquet on the upper limb nor sedation. The median nerve block in ultrasound-guided WALANT provides better accuracy to the technique, with greater patient safety; in the present article, its use in the performance of carpal tunnel decompression is described, and the literature is reviewed.

Keywords

- carpal tunnel syndrome
- ultrasonography, interventional
- anesthesia, local

Resumo

A síndrome do túnel do carpo (STC) é a neuropatia compressiva mais comum do corpo humano. Seus sintomas decorrem da compressão do nervo mediano no carpo. O tratamento pode ser incruento, com medicações e/ou infiltrações que amenizam os sintomas, ou cruento, mais eficaz, com a descompressão do nervo mediano pela seção cirúrgica do retináculo dos flexores do carpo. A técnica anestésica varia de acordo com o serviço de anestesia: sedação, anestesia locorregional venosa e, mais recentemente, a anestesia local com o paciente acordado e

* *Study developed at the School of Medicine, Universidade de Araraquara/UNIARA, Araraquara, São Paulo, Brazil.*

received
January 18, 2021
accepted after revision
May 18, 2021

DOI https://doi.org/10.1055/s-0041-1735172.
ISSN 0102-3616.

© 2021. Sociedade Brasileira de Ortopedia e Traumatologia. All rights reserved.
This is an open access article published by Thieme under the terms of the Creative Commons Attribution-NonDerivative-NonCommercial-License, permitting copying and reproduction so long as the original work is given appropriate credit. Contents may not be used for commercial purposes, or adapted, remixed, transformed or built upon. (https://creativecommons.org/licenses/by-nc-nd/4.0/)

Thieme Revinter Publicações Ltda., Rua do Matoso 170, Rio de Janeiro, RJ, CEP 20270-135, Brazil

Palavras-chave
- síndrome do túnel carpal
- ultrassonografia de intervenção
- anestesia local

sem torniquete (*wide-awake local anesthesia no tourniquet*, WALANT), que pode ser realizada pelo próprio cirurgião. Por utilizar anestesia local com vasoconstritor, essa técnica dispensa o uso de torniquete no membro superior e a necessidade de sedação. O bloqueio do nervo mediano na WALANT guiada por ultrassonografia confere melhor precisão à técnica, e mais segurança ao paciente, e, neste artigo seu uso na realização da descompressão do túnel do carpo é descrito, e a literatura, revisada.

Introduction

Carpal tunnel syndrome (CTS) is the most frequent compression syndrome in the human body, and it is defined as compression of the median nerve in the carpus. Its estimated prevalence is of 5% of the population, with a predominance among women between the fourth and sixth decades of life.[1]

The median nerve and nine flexor tendons superficially delimited by the flexor retinaculum (FR) are contained in the osteofibrous tunnel.[1] The sensory territory of the median nerve in the hand corresponds to the volar skin of the thumb, second, third and radial half of the fourth finger, which explains the symptoms of paresthesia in the more radial territory of the palm.[1]

The conservative treatment of CTS consists of the administration of analgesic medications, anti-inflammatory drugs and neuropathic pain modulators, corticoid infiltration, and the use of wrist orthosis to improve the symptoms of the patient.[2] The surgical treatment consists of the surgical section of the FR. Retinaculotomy improves the symptom of paresthesia by decompressing and decreasing the intratunnel pressure of the median nerve in the carpus.[2] The technique can be open, mini-open or endoscopic.[2,3]

Anesthesia can be general, locoregional or local. Local anesthesia consists of blocking the median nerve at the wrist and at the surgical incision site, and the association of adrenaline and lidocaine can be used to reduce intraoperative bleeding, and to eliminate the use of the tourniquet in the arm and the need for patient sedation.

This last technique is known as wide-awake local anesthesia no tourniquet (WALANT), which is a surgery with the patient awake, under local anesthesia, and without tourniquet.[2,4,5] The administration of epinephrine proves to be advantageous, as tourniquets and sedation for the patient are not required. It enables a faster onset of action and longer-lasting anesthetic effect, a surgical field with minimal bleeding, a lower dose of anesthetic to be administered to achieve pain control, lower cost, shorter preoperative time, and lower chances of complications, especially in elderly patients.[4,6] The technique was introduced by Lalonde and Martin (apud Kang et al.[6]), who demonstrated that it is a safe method in patients of any age, and capable of preventing bleeding in the surgical field without using a tourniquet. Recently, the surgical indications of this type of anesthesia have expanded beyond the treatment of CTS, and it is used in wrist surgeries, hand tenoplasty and neurolysis, for example.[5]

The introduction of the local anesthetic can be even more accurate when the introduction of the needle is guided by musculoskeletal ultrasound (US), which enables the identification, evaluation and diagnosis of lesions, in addition to the visualization of the needle and of the site of infiltration in real time. It provides effectiveness and accuracy to the procedure, and safety, agility and comfort to the patient.[7,8]

Local anesthesia with a vasoconstrictor in US-guided CTS surgery consists of the injection of perineural anesthetic with circumferential distribution, which provides a higher rate of sensory block,[7] and the volar subdermal injection of the carpus, corresponding to the surgical incision, in order to avoid bleeding.[5,7–9] The real-time guidance provided by US improves the accuracy of the injection site, makes nerve block a faster process, and enables the administration a lower dose of anesthetic, with a lower risk of developing systemic toxicity. The surgical treatment of CTS proves to be an ideal modality for therapeutic injections guided by US.[9]

Materials and Methods

A volunteer patient underwent carpal tunnel decompression surgery after failure of the conservative treatment. This patient was operated on by the specialist orthopedic surgeon who is one of the authors of the present article. Prior to the surgical procedure, the patient was properly informed about the US-guided local anesthesia procedures and the surgery itself. Participation as a volunteer was confirmed after the patient signed the free and informed consent form. The present study was approved by the institutional Ethics in Research Committee under opinion number 4.304.166.

Technique Description

The US-guided WALANT technique for carpal tunnel decompression consists of two steps. The first step is the circumferential anesthetic block of the median nerve proximally to the carpal tunnel, and the second step is the infusion of the same solution in the subdermal region in the projection of the volar surgical incision in the carpus. A portable wireless ultrasound device with a linear probe and 7.5 MHz to 10 MHz of frequency (Mobissom, São Paulo, SP, Brazil), was used, which is suitable for visualizing musculoskeletal anatomical structures in the wrist and hand, which, in turn, are necessary for the preoperative block. The images are transmitted via bluetooth to an iPad (Apple, Cupertino, CA, US).

 © 2021. Sociedade Brasileira de Ortopedia e Traumatologia. All rights reserved.

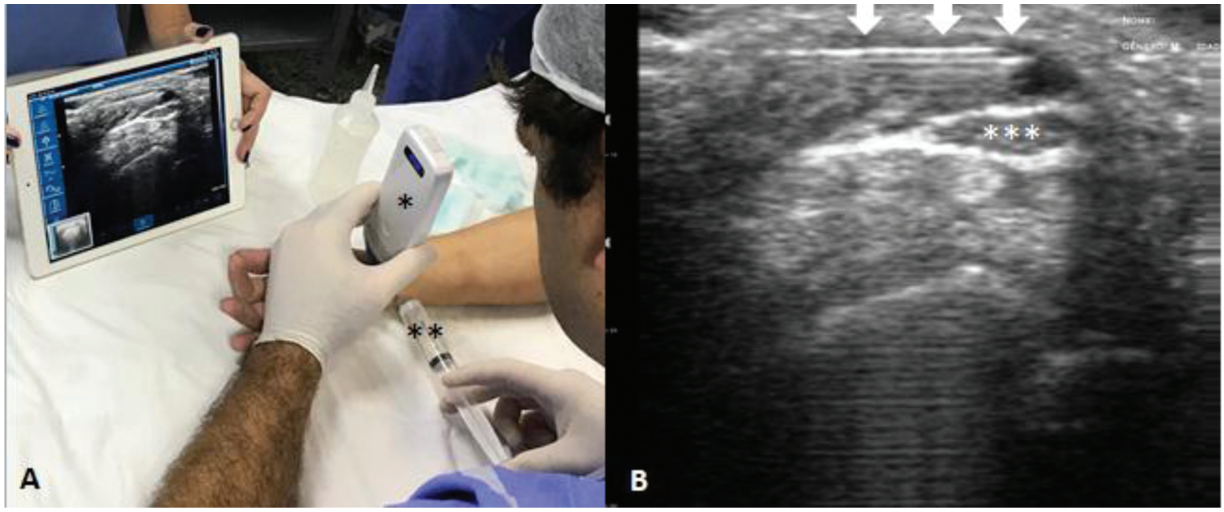

Fig. 1 (A) Right upper limb of the patient in supine on the hand table. A portable ultrasound with a linear probe* (Mobissom) is positioned across the wrist, with real-time identification of the median nerve*** in the image transmitted to an iPad (Apple). A gray disposable hypodermic needle, measuring 25 mm x 0.70 mm and attached to a 20-ml syringe containing xylocaine solution at 1% with vasoconstrictor** is introduced in the ulnoradial direction to the perineurium of the median nerve, according to white arrows (**B**). Circumferentially, ~ 6 ml to 10 ml are infused around the median nerve.

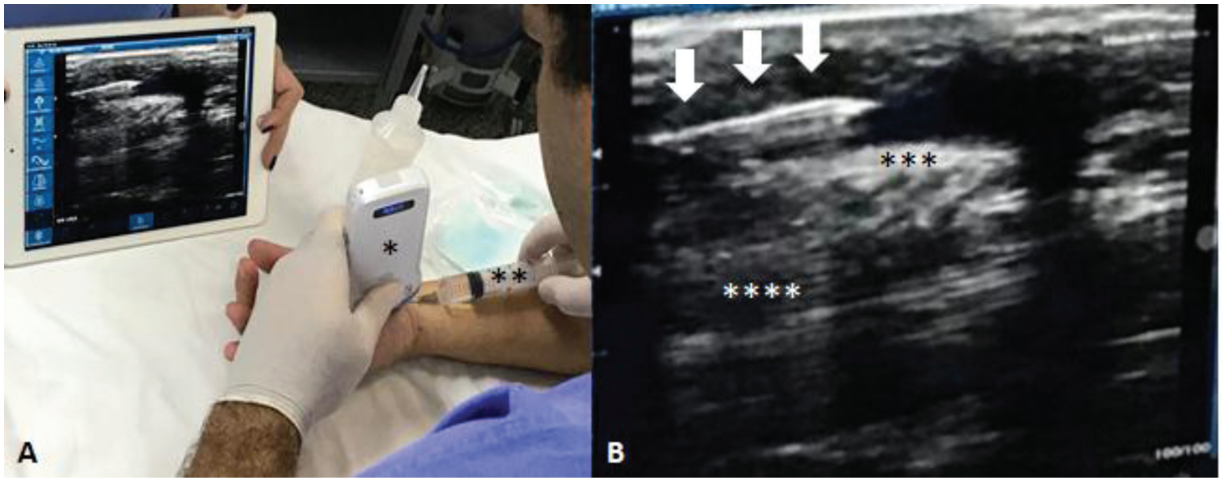

Fig. 2 (A) Right upper limb of the patient in supine position on the hand table. A portable ultrasound with a linear probre* (Mobissom) is positioned volarly and longitudinally on the carpus, in the projection of the surgical incision. A gray hypodermic needle,measuring 25 mm x 0.70 mm and attached to a 20-ml syringe,** is introduced through the wrist crease and distally directed between the dermis and the flexor retinaculum (FR). With the ultrasound image transmitted to an iPad (Apple) (**B**), the needle (white arrows) is positioned between the dermis and the FR,*** and a volume of ~ 10 ml of xylocaine solution at 1% with vasoconstrictor is injected. In image B, the deep median nerve to the FR is also observed, longitudinally.****

With the patient in dorsal decubitus position and the upper limb on a hand table, after degermation and antisepsis, the US linear transducer is placed transversely on the wrist, and the median nerve is identified. A total of 10 ml of 2% xylocaine with vasoconstrictor is diluted with 10 ml of 0.9% saline, obtaining a volume of 20 ml of 1% xylocaine. From the anesthetic solution obtained, 6 ml to 10 ml are used in the first step, and the remainder is used in the subdermal region of the surgical incision, through a gray hypodermic needle measuring 25 mm x 0.70 mm, which can be visualized on US, as shown in ►**Figures 1B** and **2B**.

In the first stage, the median nerve is blocked circumferentially proximally to the carpal tunnel after insertion of the radial needle to the plane shown with a transverse linear probe in the wrist, as shown in ►**Figure 1A**. As the tip of the needle is positioned adjacent to the nerve, content aspiration is recommended to certify that the region's vessels are not injured, and then the anesthetic is injected above and below the nerve.

In the second stage of the block, as shown in ►**Figure 2**, the US transducer is placed longitudinally on the carpus, in the projection of the surgical access. The space between the subcutaneous tissue and the FR is identified. With an entry point in the volar crease of the wrist, in a distal and longitudinal direction, the needle is introduced into the visualized space, and ~ 10 ml of the anesthetic solution are injected. This volume is sufficient to promote vasoconstriction and provide a surgical field without bleeding. After

 © 2021. Sociedade Brasileira de Ortopedia e Traumatologia. All rights reserved.

5 to 10 minutes, the time needed to prepare the surgical fields and to put on the medical garments, the surgical procedure itself can be performed.

Discussion

Traditionally, surgery to decompress the median nerve in patients with CTS is performed using a tourniquet. Due to the need for sedation of the patient, it has disadvantages such as a longer surgical time, higher costs, and the possible complications of sedation, especially in elderly patients with comorbidities. The WALANT technique, through the association of xylocaine and adrenaline, enables a safe surgery, without the need of tourniquet placement and patient sedation. The use of US enables the refinement of the technique.

Kang et al.[6], in a study aiming at comparing pain relief and the effectiveness of the WALANT technique in 20 patients undergoing CTS surgery, detected a significantly lower result on the visual analogue scale (VAS) for pain when compared to traditional locoregional anesthesia techniques within the first 24 hours of the postoperative period. They also found lower opioid consumption due to less postoperative pain.

In a study by Liebmann et al.[8] aiming at identifying the feasibility of US-guided radial, ulnar and median nerve block in the forearm of patients admitted to the hospital emergency department, a mean reduction of 5.0 in the VAS was evidenced 15 minutes after the procedure. During the study, the time needed for a complete nerve block was also measured, starting with the initiation of US and ending with the total nerve block, resulting in an average time of three minutes.

In another study, de Freitas Novais Junior et al,[4] observed 41 patients who underwent hand surgery under the technique of local anesthesia with an association of lidocaine and adrenaline at a concentration of 1:100,000. The bleeding observed during surgery was minimal in 32 patients, moderate in 6, and classified as severe in 3, 2 of whom were being treated for chronic kidney disease. In none of the cases it was necessary to stop the surgery due to bleeding. There were no cases of necrosis, hematoma, or any postoperative complications.[4]

In a study by Barros et al.,[10] the authors concluded that the WALANT technique in the surgical treatment of CTS is effective and safe. The study demonstrated a significant improvement in postoperative pain, and 75% of patients reported that the procedure is equivalent to or better than venipuncture, showing satisfaction with the technique and its effectiveness. Sardenberg et al.[11] concluded that wrist, hand and finger surgeries can be safely performed with the WALANT technique, after an evaluation of 488 operated patients, without any adverse outcome.

As for the surgical costs of CTS surgery performed in traditional surgical centers in hospitals in Canada, Leblanc et al.[12] concluded that it is four times more expensive and less efficient (less than half) compared to WALANT surgery performed in a small procedure room. The update article by Pires Neto et al.[5] corroborates the conclusion.

As in hand surgery, in which the use of an anesthetic with a vasoconstrictor is no longer a myth that causes ischemia, musculoskeletal US has changed some dogmas in orthopedics, with an increasing number of interventional and therapeutic possibilities. The use of US in the WALANT technique for the surgical treatment of CTS is an example of this evolution, which provides accuracy and effectiveness to the technique, and safety and comfort to the patient.

Final considerations

In carpal tunnel decompression surgery, US to perform the WALANT technique enables the refinement of the anesthetic technique, with greater accuracy, effectiveness, and patient safety.

Financial Support

There was no financial support from public, commercial, or non-profit sources.

Conflict of interests

The authors have no conflict of interests to declare.

References

1 Chammas M, Boretto J, Burmann LM, Ramos RM, Santos Neto FC, Silva JB. Síndrome do túnel do carpo - Parte I (anatomia, fisiologia, etiologia e diagnóstico). Rev Bras Ortop 2014;49(05):429–436
2 Chammas M, Boretto J, Burmann LM, Ramos RM, Santos Neto FC, Silva JB. Síndrome do túnel do carpo – Parte II (tratamento). Rev Bras Ortop 2014;49(05):437–445
3 van den Broeke LR, Theuvenet WJ, van Wingerden JJ. Effectiveness of mini-open carpal tunnel release: An outcome study. Arch Plast Surg 2019;46(04):350–358
4 de Freitas Novais Junior RA, Bacelar Costa JR, de Morais Carmo JM. Use of adrenalin with lidocaine in hand surgery. Rev Bras Ortop 2014;49(05):452–460
5 Pires Neto PJ, Moreira LA, Las Casas PP. É seguro o uso de anestésico local com adrenalina na cirurgia da mão? Técnica WALANT. Rev Bras Ortop 2017;52(04):383–389
6 Kang SW, Park HM, Park JK, et al. Open cubital and carpal tunnel release using wide-awake technique: reduction of postoperative pain. J Pain Res 2019;12:2725–2731
7 Brennan A, Jones M, Gordon J. Ultrasound-guided local anaesthetic blocks of the forearm. Anaesthesia tutorial of the week [Internet]. 2011 Jan 10 [cited 2020 Jan 8];(208):1-6. Disponível em: https://www.frca.co.uk/Documents/208/US/guidedlocalanaestheticforearmblocks.pdf
8 Liebmann O, Price D, Mills C, et al. Feasibility of forearm ultrasonography-guided nerve blocks of the radial, ulnar, and median nerves for hand procedures in the emergency department. Ann Emerg Med 2006;48(05):558–562
9 Nwawka OK, Miller TT, Jawetz ST, Saboeiro GR. Ultrasound-guided perineural injection for nerve blockade: Does a single-sided injection produce circumferential nerve coverage? J Clin Ultrasound 2016;44(08):465–469
10 Barros MF, da Rocha Luz Júnior A, Roncaglio B, Queiróz Júnior CP, Tribst MF. Avaliação do tratamento cirúrgico da síndrome do túnel do carpo com anestesia local. Rev Bras Ortop 2015;51(01): 36–39
11 Sardenberg T, Ribak S, Colenci R, Campos RB, Varanda D, Cortopassi AC. 488 cirurgias da mão com anestesia local com epinefrina, sem torniquete, sem sedação e sem anestesista. Rev Bras Ortop 2018;53(03):281–286
12 Leblanc MR, Lalonde J, Lalonde DH. A detailed cost and efficiency analysis of performing carpal tunnel surgery in the main operating room versus the ambulatory setting in Canada. Hand (N Y) 2007;2(04):173–178

 © 2021. Sociedade Brasileira de Ortopedia e Traumatologia. All rights reserved.