Article published online: 2021-11-11

Unusual Arteriovenous Malformation in Total Hip Arthroplasty: Case Report of a Complicated Perioperative Course

Malformação arteriovenosa incomum em artroplastia total do quadril: Relato de caso de um perioperatório de curso complicado

Nicholas Dahlgren[1] Roshan Jacob[1] Colin Cantrell[1] Mackenzie Sowers[1] Ashish B. Shah[1] Sameer Mahadeorao Naranje[1]

[1] University of Alabama at Birmingham, Birmingham, Alabama, United States

Rev Bras Ortop

Address for correspondence Sameer Mahadeorao Naranje, MD, University of Alabama at Birmingham, 1313 13th Street South, Birmingham, AL, United States (e-mail: snaranje@uabmc.edu).

Abstract

It is not common to encounter arteriovenous malformations (AVMs) during total hip arthroplasty (THA). We report the present case to draw attention to the possibility of an AVM during the direct anterior approach (DAA) for THA, which, if not borne in mind, may lead to the myriad of complications related to excessive bleeding. An 81-year-old female presented to the emergency department with a left femoral neck fracture. She elected to undergo a THA via the DAA. Abnormal appearing blood vessels were present near the ascending circumflex branches, which provided difficulty in achieving hemostasis. Excessive blood loss was noted, and the patient received one unit of packed red blood cells during the operation. Hemoglobin and hematocrit dropped in the days following surgery, requiring several additional transfusions of blood products. When the patient complained of progressive left leg swelling on postoperative day 3, a computed tomography revealed large hematomas within the left adductors and the left iliopsoas muscle. Active extravasation was identified arising from a branch of the left profunda femoral artery, as well as an arteriovenous fistula (AVF) in this area. Bleeding was controlled by selective endovascular coil embolization. As of current knowledge, this is the first reported intraoperative discovery of congenital arteriovenous malformation (AVM) with subsequent development of postoperative arteriovenous fistula and associated symptomatic hematomas in the setting of THA using the DAA. Early recognition and intervention of vascular malformations is essential in preventing potential limb- or life-threatening surgical complication.

Keywords

- arteriovenous malformations
- arthroplasty, replacement, hip
- vascular malformations

received
July 8, 2020
accepted
October 2, 2020

DOI https://doi.org/10.1055/s-0040-1722586.
ISSN 0102-3616.

© 2021. Sociedade Brasileira de Ortopedia e Traumatologia. All rights reserved.
This is an open access article published by Thieme under the terms of the Creative Commons Attribution-NonDerivative-NonCommercial-License, permitting copying and reproduction so long as the original work is given appropriate credit. Contents may not be used for commercial purposes, or adapted, remixed, transformed or built upon. (https://creativecommons.org/licenses/by-nc-nd/4.0/)

Thieme Revinter Publicações Ltda., Rua do Matoso 170, Rio de Janeiro, RJ, CEP 20270-135, Brazil

Resumo

Não é comum encontrar malformações arteriovenosas (MAV) durante a artroplastia total do quadril (ATQ). Relatamos o presente caso para chamar a atenção para a possibilidade de uma MAV durante a abordagem anterior direta (AAD) para ATQ, que se não for considerada, pode levar a uma miríade de complicações relacionadas ao sangramento excessivo. Uma mulher de 81 anos foi apresentada ao pronto-socorro com fratura no pescoço do fêmur esquerdo. Ela optou por se submeter a uma artroplastia total do quadril (ATQ) através da AAD. Vasos sanguíneos aparentemente anormais estavam presentes perto dos ramos circunflexos ascendentes, proporcionando dificuldade em alcançar hemostasia. A perda excessiva de sangue foi notada e a paciente recebeu uma unidade de glóbulos vermelhos embalados durante a operação. Hemoglobina e hematócrito caíram nos dias seguintes à cirurgia, exigindo várias transfusões adicionais de produtos sanguíneos. Quando a paciente reclamou de inchaço progressivo na perna esquerda no terceiro dia pós-operatório, a tomografia computadorizada revelou hematomas grandes dentro dos adutores esquerdos e do músculo iliopsoas esquerdo. A extravasão ativa foi identificada a partir de um ramo da artéria femoral esquerda, bem como de uma fístula arteriovenosa (FAV) nesta área. O sangramento foi controlado por embolização seletiva da bobina endovascular. A partir do conhecimento atual, esta é a primeira descoberta intraoperatória relatada de MAC congênita com desenvolvimento subsequente de FAV pós-operatória e hematomas sintomáticos associados no cenário de ATQ utilizando a AAD. O reconhecimento precoce e a intervenção de malformações vasculares são essenciais para prevenir possíveis complicações cirúrgicas de membros ou de risco de vida.

Palavras-chave

- malformações arteriovenosas
- artroplastia de quadril
- malformações vasculares

Introduction

Total hip arthroplasty (THA) is one of the most common and successful orthopedic procedures performed annually.[1] While in most cases bleeding is easily controlled, vascular abnormalities such as arteriovenous malformations (AVM) and arteriovenous fistulas (AVF) may lead to difficulty in achieving hemostasis.[2] Although rare, surgeons should be aware of these vascular malformations, as early recognition and intervention is critical in preventing limb-threatening ischemia or life-threatening hemorrhage.[3,4] According to current knowledge, this is the first reported case of primary THA in an elderly female using a direct anterior approach (DAA) with intraoperative discovery of a congenital AVM and subsequent development of a postoperative AVF with associated symptomatic hematomas. The case was successfully managed by selective endovascular coil embolization and blood transfusions.

Case Report

An 81-year-old female presented to the emergency department with severe pain in the left hip following a fall. Radiographs showed femoral neck fracture, and the patient elected to undergo total hip arthroplasty (►**Fig. 1**). Of note, there was no evidence of vascular abnormalities or compromise in the left lower extremity. Pulses were present and equal throughout, and pallor was normal.

A classical anterior approach to the hip was made. After elevating the rectus muscle, ascending circumflex branches were identified and coagulated. Abnormal appearing blood vessels were also present in this area. These vessels provided difficulty in achieving hemostasis, initially resulting in ~ 300 to 400 mL of blood loss during this process. Hemostasis was eventually achieved, and the remainder of the THA was performed uneventfully (►**Fig. 2**). During the procedure,



Fig. 1 Radiograph of the left hip at presentation showing femoral neck fracture.

 © 2021. Sociedade Brasileira de Ortopedia e Traumatologia. All rights reserved.



Fig. 2 Postoperative radiograph showing successful placement of left total hip arthroplasty.

the patient received one unit blood. The patient was stable immediately postoperatively.

Postoperative hemoglobin and hematocrit (H/H) was 8.8 and 26, down from 12.0 and 36 preoperatively. The patient received a unit of blood on both postoperative day (POD) 2 and POD 3, as H/H continued to drop to a low of 6.5/19. The patient then began to complain of increasing leg swelling from her left lower leg to the proximal part of her thigh. A computed tomography (CT) revealed a large 10 cm hematoma within the left adductor musculature and another 7.3 cm hematoma within the left iliopsoas muscle. Ultrasound (US) of the left lower extremity did not identify a gross thrombus, limited due to the large amount of swelling. A CT angiography revealed active extravasation with a large associated left thigh hematoma predominantly localized in the adductor compartment.

Following these results, interventional radiology (IR) determined that the active extravasation was arising from a branch of the left profunda femoral artery. An AVF in this area was also identified (►**Fig. 3**). The bleeding was resolved with successful selective coil embolization (►**Fig. 4**). The H/H declined for 2 more days, requiring 3 additional transfusions. Following this, the H/H steadily increased until the patient was able to maintain hemostasis.

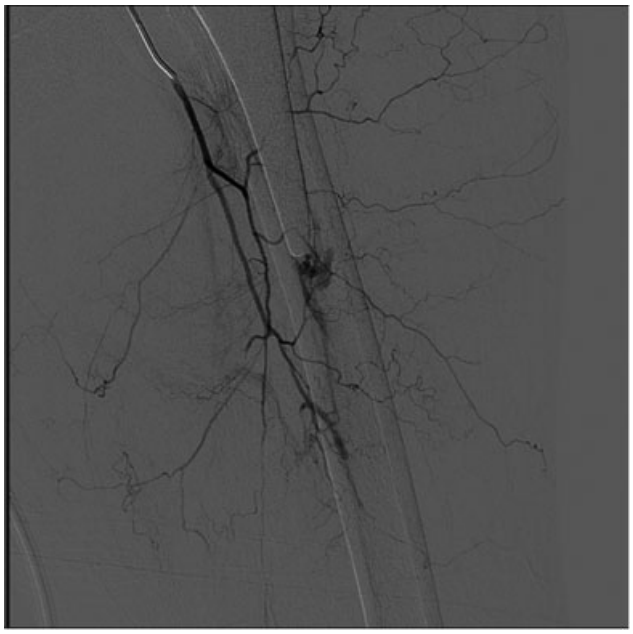

Fig. 3 Angiography showing active extravasation and arteriovenous fistula of the left profunda femoral artery.

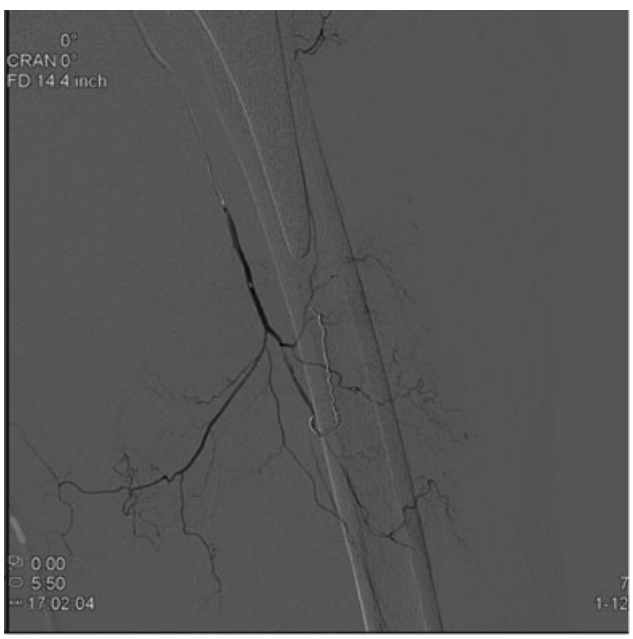

Fig. 4 Post-coil embolization showing resolution of extravasation and fistula.

On the 4th day following coil embolization, the patient reported reduced pain and swelling and continued to improve until discharge on POD 8.

Discussion

Total hip arthroplasty is widely accepted as a safe and effective treatment option for improving pain and functionality in many patients.[1,2] Occurring in $< 1\%$ of THA procedures, the infrequency of arterial injuries makes it

 © 2021. Sociedade Brasileira de Ortopedia e Traumatologia. All rights reserved.

challenging for surgeons to recognize and properly diagnose it during the perioperative course.[2,5,6]

Vascular injuries associated with THA occur due to the close proximity of the operating field with major blood vessels of the pelvis and of the lower extremity,[3,4] while being exposed to excessive force by retractors, acetabular reaming preparations, and hammering.[6] This is especially amplified in a population with higher rates of atherosclerosis and other peripheral vascular diseases.[7]

Arteriovenous malformation is a vascular anomaly described as a congenital network of direct communications between arterial and venous vessels, while AVF refers to a similar but acquired lesion, almost exclusively associated with penetrating trauma such as surgery.[3,8] Such vessels carry high vascular flow rates that can result in excessive hemorrhage if ruptured.[8] These abnormal connections can easily rupture in the acute phase, presenting with hemorrhage and hematoma formation postoperatively.[3,8]

In the present case, the discovery of unusual appearing blood vessels in the anteromedial leg combined with the excessive blood loss and difficulty in achieving hemostasis were all diagnostic of an underlying AVM. Similar cases of malignant AVM and AVF around the hip have been described, but all were discovered years after the primary hip surgery.[3,8,9] This is the first reported case of a previously undiagnosed congenital AVM encountered during primary THA with associated development of symptomatic AVF in the immediate postoperative period.

While the prevalence of vascular malformations around the hip joint is poorly documented in the literature, it has been reported that over half of soft-tissue AVMs affect the femoral or iliac vessels.[9] Interestingly, the present case and the other cases referenced in the literature review all involved lesions of the profunda femoral artery.[3,8–10] Although further evidence-based studies are needed to quantify the true predisposition of vascular complications in specific vessels, understanding which vessels are at greater risk for malformation can aid surgeons in establishing a superior surgical approach with a reduced risk of bleeding complications.

Regardless of the vessels involved, it is important for physicians to recognize the clinical presentation of bleeding in the perioperative arena. Symptoms of active bleeding include localized pain, pulsatile swelling, and development of hemodynamic instability.[2,4] Although hemostasis may be achieved intraoperatively, a postoperative IR consultation is recommended for all suspected AVM encounters to ensure a thorough resolution of the lesion.

While open surgical intervention can allow direct visualization, it may result in further damage to the vascular lesion.[7] More recently, there has been a growing trend toward endovascular management of similar cases via transcatheter embolization.[4,7] These minimally invasive procedures are highly effective for treating THA arterial complications, and they have been shown to produce equivalent outcomes without exposing patients to the additional risks of surgery.[2,5]

Although rare, vascular anomalies such as AVM or AVF can cause serious complications during the perioperative course of THA. This is the first reported case of primary THA using a DAA with intraoperative discovery of a congenital AVM and subsequent development of an AVF with associated hematomas in the immediate postoperative period, successfully managed endovascularly by selective coil embolization. Awareness of these vascular malformations and current treatment strategies are critical in preventing severe hemorrhage.

Financial Support
There was no financial support from public, commercial, or non-profit sources.

Conflict of Interests
The authors have no conflict of interests to declare.

References

1 Talia AJ, Coetzee C, Tirosh O, Tran P. Comparison of outcome measures and complication rates following three different approaches for primary total hip arthroplasty: a pragmatic randomised controlled trial. Trials 2018;19(01):13
2 Erschbamer M, Den Hollander J, Sauter D, Erhardt J, Hechelhammer L, Külling F. Endovascular embolisation is a successful and safe treatment for post-operative arterial complications after total hip arthroplasty and revision surgery. Int Orthop 2016;40 (08):1577–1582
3 Chun HJ, Osuga K, Sugihara E, Tsukaguchi I, Ohsawa S, Tsuda K. Transarterial embolization of large complex arteriovenous fistula associated with hip joint surgery. Jpn J Radiol 2010;28(06): 489–492
4 Cheng H, Shin JH, Yoon HK, et al. Retrospective 12-year study of the safety and efficacy of transcatheter arterial embolization for managing bleeding complications following hip surgery. Cardiovasc Intervent Radiol 2014;37(06):1464–1468
5 Troutman DA, Dougherty MJ, Spivack AI, Calligaro KD. Updated strategies to treat acute arterial complications associated with total knee and hip arthroplasty. J Vasc Surg 2013;58(04): 1037–1042
6 Calligaro KD, Dougherty MJ, Ryan S, Booth RE. Acute arterial complications associated with total hip and knee arthroplasty. J Vasc Surg 2003;38(06):1170–1177
7 Kickuth R, Anderson S, Kocovic L, Ludwig K, Siebenrock K, Triller J. Endovascular treatment of arterial injury as an uncommon complication after orthopedic surgery. J Vasc Interv Radiol 2006;17 (05):791–799
8 Lee HJ, Kwon BS, Kwon JH, et al. Arteriovenous malformation incidentally found by ultrasonography in a thigh hematoma after contusion. Ann Rehabil Med 2012;36(02):287–290
9 Winemaker MJ, Boucher MA, de V deBeer J, Colterjohn N, Petruccelli D. Arteriovenous malformation mimicking femoral osteolysis after total hip arthroplasty. J Arthroplasty 2001;16 (03):394–399
10 Lee YO, Hong SW. Treatment of large arteriovenous malformation in right lower limb. Korean J Thorac Cardiovasc Surg 2014;47(01): 66–70

 © 2021. Sociedade Brasileira de Ortopedia e Traumatologia. All rights reserved.