Article published online: 2021-12-20

Peroneus Longus Tendon Graft to Reconstruct the Posterolateral Corner of the Knee*

Enxerto do tendão fibular longo na reconstrução do canto posterolateral do joelho

Diego Escudeiro de Oliveira[1] Melanie Mayumi Horita[1] Victor Eduardo Roman Salas[1] Fabricio Roberto Severino[1] Luiz Gabriel Betoni Guglielmetti[1] Pedro Baches Jorge[1]

[1] Sports Trauma Group, Department of Orthopedics and Traumatology, Irmandade da Santa Casa de Misericórdia de São Paulo, São Paulo, SP, Brazil

Rev Bras Ortop

Address for correspondence Melanie Mayumi Horita, MD, Sports Trauma Group, Department of Orthopedics and Traumatology, Irmandade da Santa Casa de Misericórdia de São Paulo, R. Dr. Cesário Mota Júnior, 112 - Vila Buarque, São Paulo, SP, 01221-020, Brazil (e-mail: melmayumi.horita@gmail.com; dot@santacasasp.org.br).

Abstract

The posterolateral corner is critical to knee stability. Neglected injuries have a direct impact on the prognosis due to residual instability, chronic pain, deformities, and failure to repair other structures. Several techniques are used to reconstruct the posterolateral corner, often with autologous ischiotibial grafts or homologous grafts. An option little used for knee ligament reconstructions is the peroneus longus tendon graft. Although reported as a good alternative for anterior cruciate ligament reconstruction, we found no case using a peroneus longus tendon graft for posterolateral corner reconstruction. Here, we describe the case of a patient who underwent a non-anatomical reconstruction of the posterolateral corner using a peroneus longus tendon graft.

The patient underwent surgical procedures for ligament reconstruction and correction of the deformity caused by a failed graft, but his knee remained unstable. During the preoperative planning, it was decided to reconstruct the posterolateral corner with an ipsilateral peroneus longus tendon graft.

Studies have shown that the peroneus longus tendon graft does not increase ankle morbidity, and that its length and diameter favor ligament reconstruction. Thus, the present article highlights the importance of the proper diagnosis of ligament injuries in the acute phase, and describes a new technique for posterolateral corner reconstruction that must be included in the surgeon's body of knowledge, increasing the amount of technical options.

Keywords

- autograft
- joint instability
- anterior cruciate ligament injuries
- anterior cruciate ligament reconstruction

* *Study developed at Faculdade de Ciências Médicas, Irmandade da Santa Casa de Misericórdia de São Paulo, São Paulo, SP, Brazil.*

received
September 9, 2020
accepted
November 3, 2020

DOI https://doi.org/10.1055/s-0041-1724085.
ISSN 0102-3616.

© 2021. Sociedade Brasileira de Ortopedia e Traumatologia. All rights reserved.
This is an open access article published by Thieme under the terms of the Creative Commons Attribution-NonDerivative-NonCommercial-License, permitting copying and reproduction so long as the original work is given appropriate credit. Contents may not be used for commercial purposes, or adapted, remixed, transformed or built upon. (https://creativecommons.org/licenses/by-nc-nd/4.0/)

Thieme Revinter Publicações Ltda., Rua do Matoso 170, Rio de Janeiro, RJ, CEP 20270-135, Brazil

Resumo

O canto posterolateral tem grande importância na estabilidade do joelho. Sua lesão pode ser negligenciada, o que tem um impacto direto no prognóstico e resulta em instabilidade residual, dor crônica, deformidades e falha do reparo de outras estruturas. Existem diversas técnicas de reconstrução do canto posterolateral, e o uso de enxertos autólogos dos isquiotibiais ou homólogos são as mais comuns. Uma opção pouco utilizada para reconstruções ligamentares no joelho é o enxerto do tendão fibular longo. Apesar de descrito como boa opção na reconstrução do ligamento cruzado anterior, não foi encontrado nenhum caso de uso do enxerto do tendão fibular longo na reconstrução do canto posterolateral. Neste artigo, descrevemos o caso de um paciente submetido a reconstrução não anatômica do canto posterolateral com uso do enxerto do tendão fibular longo.

O paciente foi submetido a procedimentos cirúrgicos para reconstrução ligamentar e correção de deformidade ocasionada pela falha do enxerto, mas manteve instabilidade ligamentar. No planejamento pré-operatório, optou-se pela reconstrução do canto posterolateral com enxerto do tendão fibular longo ipsilateral.

Estudos evidenciaram que o enxerto do tendão fibular longo não rpovoca aumento de morbidade em relação ao tornozelo abordado, bem como se apresenta com comprimento e diâmetro favoráveis à reconstrução ligamentar. Dessa forma, este artigo aponta para a importância do diagnóstico correto das lesões ligamentares na fase aguda e para uma nova técnica na reconstrução do canto posterolateral que deve fazer parte do arsenal de conhecimentos do cirurgião, pois aumenta as opções de técnicas.

Palavras-chave

- autoenxerto
- instabilidade articular
- lesões do ligamento cruzado anterior
- reconstrução do ligamento cruzado anterior

Introduction

The posterolateral corner (PLC) consists of three primary structures: the peroneal collateral ligament, the popliteal tendon, and the popliteofibular ligament. It limits external rotation, varus movement, and posterior translation. A neglected PLC injury directly impacts the prognosis because it leads to residual instability, chronic pain, deformities, and failure to repair other structures.[1] Several techniques are used for PLC reconstruction, including autologous ischiotibial grafts (ITGs) or homologous grafts.[2] A little-used option for knee ligament reconstructions is the peroneus longus tendon graft (PLTG). Its use for the reconstruction of the anterior cruciate ligament (ACL) is reported by some studies, including the one published in 2008 by Kerimoğlu et al.[3] analyzing outcomes from 29 patients. Although this graft has been used for some years, we found no case of PLC reconstruction with it in the literature. Here, we describe the case of a patient who underwent a non-anatomical PLC reconstruction using PLTG and his postoperative follow-up.

Case Report

A 33-year-old male patient with pain and instability in the left knee. An ACL reconstruction was performed using an ipsilateral ITG. Due to graft failure and the development of varus deformity after one year, an ACL reconstruction review with a contralateral ITG and tibial valgus osteotomy was performed. Ten weeks later, the patient still reported pain and instability. A physical examination revealed a varus deformity in the left knee (►**Figure 1**), positive varus stress



Fig. 1 Panoramic clinical image of the lower limbs during the preoperative evaluation.

 © 2021. Sociedade Brasileira de Ortopedia e Traumatologia. All rights reserved.

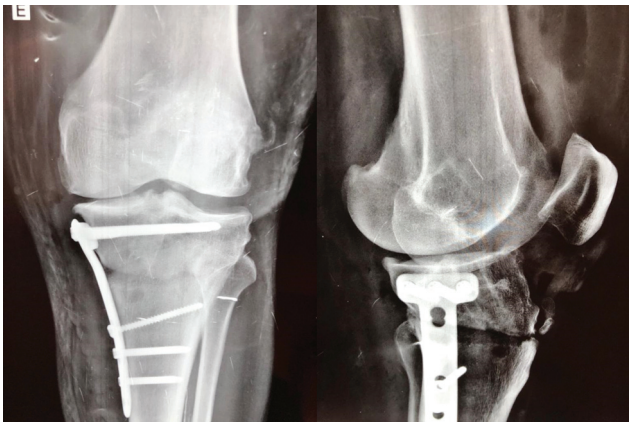

Fig. 2 Preoperative anteroposterior and lateral radiographs of the left knee.

with the knee at 30° and 0° of flexion, positive dial test at 30°, positive anterior drawer test in internal rotation, and positive reverse pivot shift. Recent imaging scans demonstrated previous manipulation of the left proximal tibia with a medial opening wedge, plate, and screws, with signs of bone healing (►**Figure 2**). Magnetic resonance imaging showed signs of a neglected injury in the PLC. During the preoperative planning, a PLTG was chosen for PLC reconstruction using a non-anatomical technique.

With the patient in supine position, a 2-cm incision posterior to the lateral malleolus was made ipsilaterally to the ligament injury. The peroneus brevis and longus tendons were dissected, identified, and isolated (►**Figure 3**). Both tendons were sutured, and the peroneus longus tendon was repaired and sectioned proximally to the suture. The tendon was then removed using a tenotome (►**Figure 4**). A non-anatomical PLC reconstruction was performed under direct visualization using a lateral approach (►**Figure 5**). Following reconstruction, knee stability was satisfactory. At the

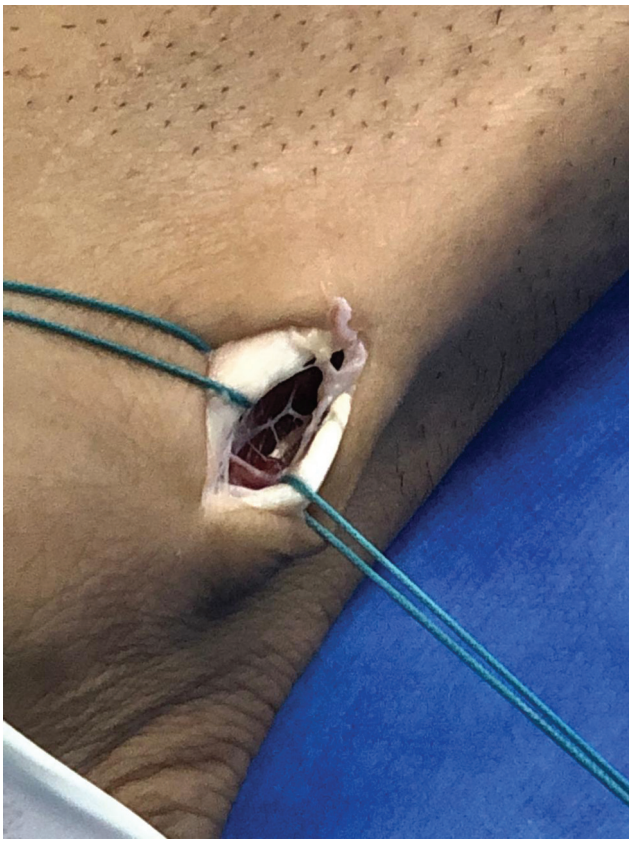

Fig. 3 Intraoperative image. A 2-cm incision posterior to the lateral malleolus, ipsilateral to the ligament injury. Identification and isolation of the peroneus longus and brevis tendons.



Fig. 4 Intraoperative image. Graft harvest from the peroneus longus tendon.

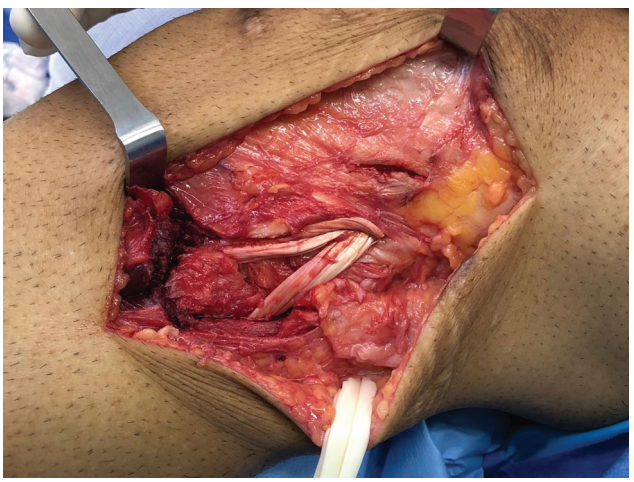

Fig. 5 Non-anatomical posterolateral corner reconstruction under direct visualization in a lateral approach.

 © 2021. Sociedade Brasileira de Ortopedia e Traumatologia. All rights reserved.

postoperative follow-up, the patient did not report pain in the left ankle, with preserved range of motion.

Discussion

Ischiotibial tendons are usually the first choice for the reconstruction of knee ligaments. In multiligament lesions, this graft may not be enough to provide proper knee stability, since these techniques require a large volume of graft for anatomical recovery. Thus, other grafts are used to add length and diameter. Some of them are well established, such as autologous grafts from the quadriceps and patellar tendons, or even homologous grafts available in tissue banks. However, in the clinical practice, we observed that grafts from the extensor mechanism are not suitable for some techniques and can result in drawbacks, including pain at the harvest site and limitations in daily activities, especially in patients who need to perform activities while kneeling down. Another option would be a homologous graft, which presents greater flexibility in terms of shape and configuration for the performance of different techniques. However, their use is limited due to the high cost and unavailability in some services; in addition, these grafts are prone to immunological rejection and disease transmission.

In this context, the peroneus longus tendon emerged as an alternative graft for ACL reconstruction. Patients reportedly present anterior knee pain and hypotrophy of the thigh muscles after ACL reconstructions with grafts from the extensor mechanism.[4] The peroneus longus muscle tendon is in a superficial anatomical position that facilitates surgical access; in addition, since it has a good length, it is versatile, and can be used in various ligament reconstruction techniques. However, the lack of the peroneus longus tendon has potential consequences to the ankle, including its stability and biomechanics. Studies[4–7] indicate that patients undergoing peroneus longus graft harvest do not present significant changes in muscle strength, range of motion, loading and gait compared to the non-operated side, with no pain complaints or diminished physical activities. Thus, the literature[3–5,7] describes that the use of autologous grafts from the peroneus longus ipsilateral to the ligament injury is safe, with a low morbidity rate, one of the reasons why it was chosen for our patient. Despite being widely reported as a good option for ACL reconstruction, we found no case in the literature using the same graft for PLC reconstruction. In a patient with a neglected PLC injury, who had already undergone bilateral ischiotibial graft harvest and with no available graft in tissue banks, the choice for a graft with minimal complications and a simplified surgical access, avoiding excessive surgical manipulation, was deemed the most appropriate.

The use of a peroneus longus tendon graft for knee ligament reconstruction is a good option, and it must be included at the surgeon's body of knowledge, increasing the amount of technical options. A proper physical examination of all knee structures is critical to avoid missing ligament injuries, such as those to the PLC, which potentially lead to treatment failures.

Financial Support
There was no financial support from public, commercial, or non-profit sources.

Conflict of Interests
The authors have no conflict of interests to declare.

References

1 Welsh P, DeGraauw C, Whitty D. Delayed diagnosis of an isolated posterolateral corner injury: a case report. J Can Chiropr Assoc 2016;60(04):299–304
2 Crespo B, James EW, Metsavaht L, LaPrade RF. Lesões do canto posterolateral do joelho: uma revisão completa da anatomia ao tratamento cirúrgico. Rev Bras Ortop 2015;50(04): 363–370
3 Kerimoğlu S, Aynaci O, Saraçoğlu M, Aydin H, Turhan AU. [Anterior cruciate ligament reconstruction with the peroneus longus tendon]. Acta Orthop Traumatol Turc 2008;42(01):38–43
4 Rhatomy S, Asikin AIZ, Wardani AE, Rukmoyo T, Lumban-Gaol I, Budhiparama NC. Peroneus longus autograft can be recommended as a superior graft to hamstring tendon in single-bundle ACL reconstruction. Knee Surg Sports Traumatol Arthrosc 2019; 27(11):3552–3559
5 Shi FD, Hess DE, Zuo JZ, et al. Peroneus Longus Tendon Autograft is a Safe and Effective Alternative for Anterior Cruciate Ligament Reconstruction. J Knee Surg 2019;32(08):804–811
6 Bi M, Zhao C, Zhang S, Yao B, Hong Z, Bi Q. All-Inside Single-Bundle Reconstruction of the Anterior Cruciate Ligament with the Anterior Half of the Peroneus Longus Tendon Compared to the Semitendinosus Tendon: A Two-Year Follow-Up Study. J Knee Surg 2018; 31(10):1022–1030
7 Nazem K, Barzegar M, Hosseini A, Karimi M. Can we use peroneus longus in addition to hamstring tendons for anterior cruciate ligament reconstruction? Adv Biomed Res 2014;3:115

 © 2021. Sociedade Brasileira de Ortopedia e Traumatologia. All rights reserved.