Article published online: 2021-12-20

THIEME OPEN ACCESS

The Efficacy of Topical Tranexamic Acid in Femoral Neck Fractured Patients Undergoing Cemented Bipolar Hemiarthroplasty: A Randomized Double Blinded Controlled Trial

A eficácia do ácido tranexâmico tópico em pacientes com fraturas no pescoço femoral submetidos a hemiartroplastia bipolar cimentada: Um ensaio controlado duplo-cego randomizado

Theerawit Hongnaparak[1] Fatin Binlateh[1] Khanin Iamthanaporn[1] Pramot Tanutit[2] Varah Yuenyongviwat[1]

[1] Department of Orthopedics, Faculty of Medicine, Prince of Songkla University, Songkhla, Thailand
[2] Department of Radiology, Faculty of Medicine, Prince of Songkla University, Songkhla, Thailand

Address for correspondence Varah Yuenyongviwat, MD, Department of Orthopedics, Faculty of Medicine, Prince of Songkla University, Hat Yai, Songkhla 90110, Thailand (e-mail: varahortho@gmail.com).

Rev Bras Ortop

Abstract

Objective Tranexamic acid (TXA) is an antifibrinolytic that is widely used for decreasing blood loss and blood transfusion rates in total hip arthroplasty. However, there is limited evidence of topical TXA usage in hip hemiarthroplasty for femoral neck fractures. The present study aimed to evaluate the effects of topical TXA on blood loss and on blood transfusions in femoral neck fracture patients who underwent cemented bipolar hemiarthroplasty.

Methods Twenty-six patients with femoral neck fractures who were scheduled for bipolar cemented arthroplasty were randomized into two groups. The first group of 12 patients received topical TXA during their operation, whereas 14 patients in the second group received a placebo. Hematocrit was measured at 6 and 24 hours postoperatively. Blood transfusions and postoperative complications were also recorded.

Results Total blood loss was not different between the TXA group and the control group (TXA group: 459.48 ± 456.32 ml, and control group: 732.98 ± 474.02 ml;

Keywords
- tranexamic acid
- femoral neck fractures
- hemiarthroplasty
- arthroplasty, replacement, hip

Work developed in the Faculty of Medicine, Prince of Songkla University, Songkhla, Thailand.

received
June 25, 2021
accepted after revision
August 31, 2021

DOI https://doi.org/10.1055/s-0041-1740292.
ISSN 0102-3616.

© 2021. Sociedade Brasileira de Ortopedia e Traumatologia. All rights reserved.
This is an open access article published by Thieme under the terms of the Creative Commons Attribution-NonDerivative-NonCommercial-License, permitting copying and reproduction so long as the original work is given appropriate credit. Contents may not be used for commercial purposes, or adapted, remixed, transformed or built upon. (https://creativecommons.org/licenses/by-nc-nd/4.0/)

Thieme Revinter Publicações Ltda., Rua do Matoso 170, Rio de Janeiro, RJ, CEP 20270-135, Brazil

$p = 0.14$). However, there were no patients within the TXA group who required a blood transfusion, while there were 4 patients in the control group who received allogenic blood transfusions ($p = 0.044$). There were no postoperative complications, such as wound complication, venous thromboembolism, or cardiovascular complications within either group.

Conclusion Topical TXA could not decrease total blood loss but was able to reduce transfusion rates in patients who underwent cemented bipolar hip hemiarthroplasty in femoral neck fractures. Further studies in doses of topical TXA in a larger sample size would be beneficial.

Level of Evidence II.

Resumo

Objetivo O ácido tranexâmico (TXA) é um antifibrinolítico amplamente utilizado para diminuir as taxas de perda de sangue e de transfusão de sangue na artroplastia total do quadril. No entanto, há evidências limitadas de uso tópico de TXA na hemiartroplastia do quadril para fraturas no pescoço femoral. O presente estudo teve como objetivo avaliar os efeitos do TXA tópico na perda de sangue e transfusões de sangue em pacientes com fratura femoral que foram submetidos a hemiartroplastia bipolar cimentada.

Métodos Vinte e seis pacientes com fraturas no pescoço femoral e programados para artroplastia cimentada bipolar foram randomizados em dois grupos. O primeiro grupo de 12 pacientes recebeu TXA tópico durante a operação; no segundo grupo, 14 pacientes receberam placebo. O hematócrito foi medido às 6 e 24 horas no pós-operatório. Também foram registradas transfusões de sangue e complicações pós-operatórias.

Resultados A perda total de sangue não foi diferente entre o grupo TXA e o grupo controle (grupo TXA: 459,48 ± 456,32 ml; e grupo controle: 732,98 ± 474,02 ml; $p = 0,14$). No entanto, não houve pacientes dentro do grupo TXA que necessitaram de transfusão de sangue, enquanto 4 pacientes no grupo controle fizeram transfusões de sangue halogênicas ($p = 0,044$). Não houve complicações pós-operatórias, tais como complicação da ferida, tromboembolismo venoso ou complicações cardiovasculares dentro de qualquer grupo.

Conclusão O TXA tópico não conseguiu diminuir a perda total de sangue, mas foi capaz de reduzir as taxas de transfusão, em pacientes submetidos a hemiartroplastia de quadril bipolar cimentada em fraturas no pescoço femoral. Outros estudos com doses de TXA tópico em um tamanho amostral maior seriam benéficos.

Nível de Evidência II.

Palavras-chave
- ácido tranexâmico
- fraturas do colo femoral
- hemiartroplastia
- artroplastia de quadril

Introduction

Tranexamic acid (TXA) is an antifibrinolytic that is widely used for decreasing blood loss and blood transfusion rates in total joint arthroplasty.[1,2] There are many routes for the administration of TXA, such as oral, intravenous, topical, and combined usage.[3,4] In a meta-analysis comparing topical, intravenous, and oral TXA formulation, it was found that any form of TXA could reduce blood loss and the risk of transfusion compared with a placebo. Furthermore, there was not clearly superior blood-sparing properties of each one above any other.[5] However, there was one meta-analysis that found that topical TXA presented the lowest relative risk ratio compared with other routes. Additionally, the study suggested using topical TXA alone in patients with higher risks of thrombosis for the best safety profile.[6] Topical TXA administration was conducted via applying TXA into the surgical site, placed during the operation, as well as by being injected into the drain tube after wound closure. This method could produce high, therapeutic concentrations at the site of bleeding, with minimal systemic absorption.[7]

Even though there is substantial evidence supporting the use of topical TXA in total hip arthroplasty,[8] there are limited evidences of topical TXA usage in hip hemiarthroplasty; which is different from total hip replacement regarding blood loss and operative time.[9] In addition, there is only a limited number of studies that focus on TXA usage in hip replacement for

 © 2021. Sociedade Brasileira de Ortopedia e Traumatologia. All rights reserved.

femoral neck fractures, which also have different characteristics compared with elective hip arthroplasty from other causes.[10] There is a retrospective study that shows that patients who received topical TXA in cementless hip hemiarthroplasty had a reduction of estimated blood loss, of vacuum tube drainage, and of total transfusion volume, when comparing with patients who did not receive TXA.[11]

Hence, our study aimed to evaluate the effect of topical TXA on blood loss and blood transfusions in patients with hip fracture undergoing cemented bipolar hemiarthroplasty. We hypothesize that topical TXA could reduce total blood loss compared with a placebo.

Material and Methods

The present study was a prospective randomized control trial in parallel-group, two-arm clinical trial, with an allocation ratio of 1:1. The present study was conducted at a tertiary care hospital from June 1, 2017, to December 31, 2019. The procedures in the present study were performed in compliance with the Declaration of Helsinki guidelines regarding ethical principles for medical research involving human subjects.[12] The present study was approved by the local ethics committee and institutional review board. All individual participants included in the study signed an informed consent form.

Twenty-nine patients >60 years old with femoral neck fractures who were scheduled for bipolar cemented arthroplasty were approached for possible inclusion in the present study. The exclusion criteria were: patients who had previous hip surgery, pathological fractures, patients who were allergic to TXA, history of venous thromboembolism, history of coagulation disorder, and history of hip infection. Three patients were excluded from the study because one patient had pathological fractures and two patients declined to participate in the study. Finally, 26 patients were enrolled in the study (►**Fig. 1**).

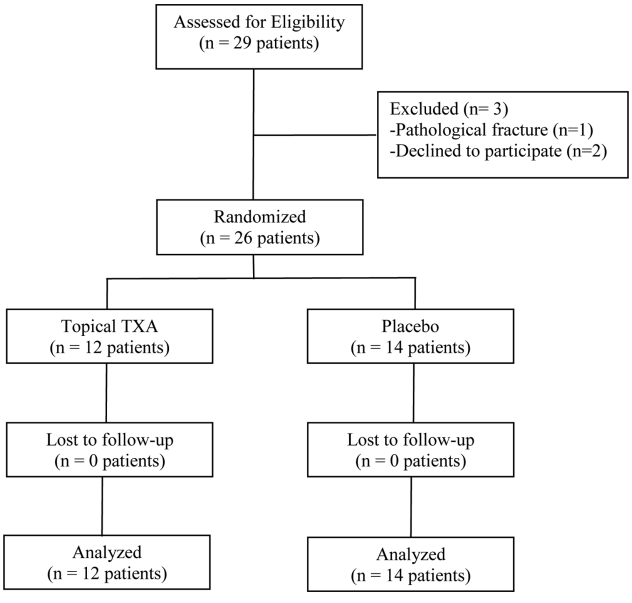

Fig. 1 Flow study diagram.

All patients were randomized into two groups: the TXA group or the placebo group. All patients underwent cemented bipolar hip hemiarthroplasty within the appropriate time frame for their medical condition (mean 3.17 ± 2.61 days after hospitalization), with the same surgical techniques and instruments being used in both groups; the operations were performed via the posterior approach. The cement plug was placed in the intramedullary canal at a position 1 cm distal to the femoral stem and, afterwards, TXA was applied. In the TXA group, 1 g of TXA solution (20 ml) was applied into the femoral canal and the surgical field, then all of the TXA solution was sucked out after 5 minutes, upon which the femoral stem and head were then placed. Following wound closure, 1 g of TXA solution (20 ml) was injected though the surgical field via the vacuum drain tube. The vacuum drain tube was then clamped for 30 minutes before being released. In the control group, the same volume of 0.9% normal saline was applied, instead of TXA, with the same steps being performed as those in the patients in the TXA group. All patients were submitted to the same postoperative care protocol. Aspirin (300 mg tablets) was prescribed the day after surgery for venous thromboembolism prophylaxis. The patients were allowed to ambulate with a supportive device on the day after surgery. Hematocrit were recorded at 6 and 24 hours postoperatively. The patients received blood transfusions if their hematocrit was $< 25\%$. Total blood loss was calculated according to the method described by Camarasa et al., with hematocrit measured before the operation and 24 hours postoperatively.

Block-of-four randomization was performed by computer-generated random numbers, to randomize the patients into the two groups. Sealed, opaque envelopes were used to allocate the patients and were opened in the morning of the operative day by a pharmacist in the inpatient hospital pharmacy, who also prepared the solution for application in the operative field. All 26 patients were allocated into 2 groups, with 12 patients in the TXA group and 14 patients in the control group. Both patients and surgeons were blinded from the group of patients and from the containers both of TXA and placebos, which were identical in appearance.

Statistical Analysis

Patient demographic data including age, weight, height, body mass index (BMI), prothrombin time, preoperative hematocrit, intraoperative blood loss, operative time, and total blood loss were evaluated with a *t*-test. The Pearson chi-squared test was used to compare genders and the incidence of blood transfusion. R version 3.1.0 software (R Foundation for statistical computing, Vienna, Austria) was used to analyze the data. Statistical significance was assumed when $p < 0.05$.

Results

Baseline demographic data were not different between groups in terms of age, gender, weight, height, body mass index (BMI), prothrombin time, preoperative hematocrit, intraoperative blood loss, and operative time (►**Table 1**).

 © 2021. Sociedade Brasileira de Ortopedia e Traumatologia. All rights reserved.

Table 1 Demographic data

Characteristic	TXA group $n = 12$	Control group $n = 14$	*p-value*
Age (years old)	$81.67 \pm 5.76^*$	$80.57 \pm 8.23^*$	0.703
Gender (male: female)	3:9	6:8	0.34
Weight (kg)	$54.08 \pm 8.63^*$	$57.64 \pm 10.57^*$	0.361
Height (cm)	$158.08 \pm 7.68^*$	$161.5 \pm 5.42^*$	0.197
BMI (kg/m^2)	$21.55 \pm 2.45^*$	$22.02 \pm 3.5^*$	0.706
Prothrombin time (sec)	11.89 ± 1.1	12.34 ± 0.54	0.186
Preoperative hematocrit (%)	33.67 ± 3.97	35.11 ± 4	0.367
Intraoperative blood loss (ml)	243.33 ± 110.32	242.86 ± 110.69	0.991
Operative time (min)	160 ± 18.34	161.07 ± 28.8	0.913

Abbreviation: BMI, body mass index.
*Mean values with standard deviations.

Total blood loss was not different between the TXA group and the control group. (TXA group: 459.48 ± 456.32 ml, and control group: 732.98 ± 474.02 ml; $p = 0.14$). There were no patients in the TXA group who required blood transfusions, while there were 4 patients in the control group who received allogenic blood transfusions ($p = 0.044$). There was no difference in the postoperative hospital stay between the two groups (TXA group: 4.25 ± 1.29 days, and control group: 4.71 ± 1.27 days; $p = 0.364$). Within both groups, there were no postoperative complications such as wound complication, venous thromboembolism, or cardiovascular complications.

Discussion

Tranexamic acid is safe and effective for reducing blood loss and blood transfusions in hip arthroplasty.[14–16] There was a report that administration of intravenous TXA could reduce the mean incidence of transfusions and had a tendency to decrease transfusion rates, compared with a placebo, in patients undergoing hip arthroplasty for acute femoral neck fractures.[10] However, there is limited evidence of topical TXA usage in bipolar hip hemiarthroplasty in femoral neck fractures. Therefore, the authors conducted the present study to evaluate the effect of topical TXA in femoral neck fracture patients who underwent cemented bipolar hip hemiarthroplasty. We found that topical TXA did not reduce total blood loss or hospital stay. However, we found that topical TXA could reduce the blood transfusion rate.

The present study had several limitations. First, although there was only a small number of participants, the findings of the present study will be useful in organizing a future study with adequate power to validate our findings. Second, the present study evaluated only 24 hours postoperatively, a period that might be too short compared with that of other studies. However, the authors believe that most postoperative bleeding occurred within 24 hours, postoperatively. Thus, further studies with more participants and with a longer duration for data collection would be beneficial.

Our results demonstrated that total blood loss was not different between groups. This contradicted the results of previous studies. Yue et al.[17] reported a randomized double-blind controlled trial evaluating the effects of a high dose of 3 g topical TXA in total hip arthroplasty, comparing this with a placebo. This study found that topical TXA significantly reduced total blood loss when comparing with the control group. In addition, Kwak et al.[11] performed a case-control study in patients undergoing cementless bipolar hemiarthroplasty for femoral neck fractures who received topical TXA compared with patients who did not receive topical TXA. This study also demonstrated that patients in the TXA group had lower blood loss.

In our study, the transfusion rate was lower in the TXA group compared with the control group. Similarly, a randomized study by Tavares Sánchez-Monge et al.,[18] comparing topical TXA and a placebo in 119 patients with total hip arthroplasty, reported lower percentages of transfused patients (35.9 versus 19.3%). There was also a randomized double-blind controlled trial that found that topical application of TXA in primary total hip arthroplasty reduced transfusions from 22.4 to 5.7% compared with a placebo.[17] Moreover, a case-control study also found that patients undergoing hemiarthroplasty for femoral neck fractures who received topical TXA had lower transfusion rates coupled with a lower, total blood transfusion volume than that of the control group.

The present study found that topical TXA did not increase postoperative complications, nor did it reduce hospital stay. Previous studies on topical TXA in total hip arthroplasty and hip hemiarthroplasty had the same results.[11,17,19] Liu et al.[19] reported a retrospective study in femoral neck fracture patients undergoing hemi hip replacement receiving intraarticular TXA compared with a control group, and their results showed no deep venous thrombosis or pulmonary embolism in either group; additionally, the hospital stay was not different between groups. Another study, by Kang et al.,[20] also demonstrated that 80 patients who had undergone primary, total hip arthroplasty, or bipolar hip hemiarthroplasty and received

 © 2021. Sociedade Brasileira de Ortopedia e Traumatologia. All rights reserved.

topical TXA had no complications such as infection, deep vein thrombosis, or cardiovascular diseases.

Conclusions

Topical TXA could not reduce total blood loss nor hospital stay but was able to decrease the transfusion rate without increasing wound and thromboembolic complications in patients undergoing cemented bipolar hip hemiarthroplasty for femoral neck fractures. Further studies on doses of topical TXA or on the efficacy of topical TXA, comparing other TXA routes in a larger sample size, would be beneficial.

Ethics Approval and Consent

The present study was approved by the Ethics Committee and Institutional Review Board of the Faculty of Medicine, Prince of Songkla University (EC 0.59–390–11–1). Written informed consent was obtained from all individual participants included in the present study.

Public Trials Registry

Thai Clinical Trials Registry (http://www.clinicaltrials.in.th): TCTR20201224005

Financing Source

Funding for the present research was provided by the Faculty of Medicine, Prince of Songkla University, Songkhla, Thailand (grant number 59–390–11–1). The funders had no role in the study design, data collection and analysis, decision to publish, nor in the preparation of the manuscript.

Contributions of the Authors

Hongnaparak T. designed the study, performed data collection, and performed the analysis and prepared the manuscript; Binlateh F. and Tanutit P. designed the study and performed data collection; Iamthanaporn K. designed the study and prepared the manuscript; Yuenyongviwat Y. designed the study, performed the analysis, and prepared the manuscript. All authors have read and approved the final manuscript.

Availability of Data and Materials

The datasets generated during the present study are available from the corresponding author upon reasonable request.

Conflict of Interests

The authors have no conflict of interests to declare.

Acknowledgments

The authors wish to thank Andrew Jonathan Tait, from the International Affairs Department, for his assistance in proofreading the English version of the present report.

References

1 Sun Q, Li J, Chen J, Zheng C, Liu C, Jia Y. Comparison of intravenous, topical or combined routes of tranexamic acid administration in patients undergoing total knee and hip arthroplasty: a meta-analysis of randomised controlled trials. BMJ Open 2019;9(01):e024350
2 Xiong H, Liu Y, Zeng Y, Wu Y, Shen B. The efficacy and safety of combined administration of intravenous and topical tranexamic acid in primary total knee arthroplasty: a meta-analysis of randomized controlled trials. BMC Musculoskelet Disord 2018;19(01):321
3 Luo ZY, Wang D, Meng WK, et al. Oral tranexamic acid is equivalent to topical tranexamic acid without drainage in primary total hip arthroplasty: A double-blind randomized clinical trial. Thromb Res 2018;167:1–5
4 Zhang P, Liang Y, Chen P, Fang Y, He J, Wang J. Intravenous versus topical tranexamic acid in primary total hip replacement: A meta-analysis. Medicine (Baltimore) 2016;95(50):e5573
5 Fillingham YA, Ramkumar DB, Jevsevar DS, et al. The Efficacy of Tranexamic Acid in Total Hip Arthroplasty: A Network Meta-analysis. J Arthroplasty 2018;33(10):3083–3089.e4
6 Xu S, Chen JY, Zheng Q, et al. The safest and most efficacious route of tranexamic acid administration in total joint arthroplasty: A systematic review and network meta-analysis. Thromb Res 2019;176:61–66
7 Alshryda S, Sukeik M, Sarda P, Blenkinsopp J, Haddad FS, Mason JM. A systematic review and meta-analysis of the topical administration of tranexamic acid in total hip and knee replacement. Bone Joint J 2014;96-B(08):1005–1015
8 Rizzo M, Russo AP, Guarino A, Izzo A, Mariconda M. A comparative study of combined intravenous and topical administration of tranexamic acid with topical tranexamic acid alone for blood loss reduction after primary uncemented total hip arthroplasty. J Biol Regul Homeost Agents 2020;34(3, Suppl. 2)105–110, 2019
9 van den Bekerom MP, Hilverdink EF, Sierevelt IN, et al. A comparison of hemiarthroplasty with total hip replacement for displaced intracapsular fracture of the femoral neck: a randomised controlled multicentre trial in patients aged 70 years and over. J Bone Joint Surg Br 2010;92(10):1422–1428
10 Watts CD, Houdek MT, Sems SA, Cross WW, Pagnano MW. Tranexamic Acid Safely Reduced Blood Loss in Hemi- and Total Hip Arthroplasty for Acute Femoral Neck Fracture: A Randomized Clinical Trial. J Orthop Trauma 2017;31(07):345–351
11 Kwak DK, Jang CY, Kim DH, Rhyu SH, Hwang JH, Yoo JH. Topical tranexamic acid in elderly patients with femoral neck fractures treated with hemiarthroplasty: efficacy and safety? - a case-control study. BMC Musculoskelet Disord 2019;20(01):228
12 Goodyear MD, Krleza-Jeric K, Lemmens T. The Declaration of Helsinki. BMJ 2007;335(7621):624–625
13 Camarasa MA, Ollé G, Serra-Prat M, et al. Efficacy of aminocaproic, tranexamic acids in the control of bleeding during total knee replacement: a randomized clinical trial. Br J Anaesth 2006;96(05):576–582
14 Chen S, Wu K, Kong G, Feng W, Deng Z, Wang H. The efficacy of topical tranexamic acid in total hip arthroplasty: a meta-analysis. BMC Musculoskelet Disord 2016;17:81
15 Fernández-Cortiñas AB, Quintáns-Vázquez JM, Gómez-Suárez F, Murillo OS, Sánchez-López BR, Pena-García JM. Effect of tranexamic acid administration on bleeding in primary total hip arthroplasty. Efecto de dosis única intravenosa de ácido tranexámico sobre el sangrado en artroplastia total de cadera. Estudio prospectivo, controlado y aleatorizado. Rev Esp Cir Ortop Traumatol. 2017;61(5):289-295
16 Xie J, Hu Q, Huang Q, Ma J, Lei Y, Pei F. Comparison of intravenous versus topical tranexamic acid in primary total hip and knee arthroplasty: An updated meta-analysis. Thromb Res 2017;153:28–36
17 Yue C, Kang P, Yang P, Xie J, Pei F. Topical application of tranexamic acid in primary total hip arthroplasty: a randomized double-blind controlled trial. J Arthroplasty 2014;29(12):2452–2456
18 Tavares Sánchez-Monge FJ, Aguado Maestro I, Bañuelos Díaz A, Martín Ferrero MÁ, García Alonso MF. Efficacy and safety of the topical application of tranexamic acid in primary cementless hip arthroplasty: prospective, randomised, double-blind and controlled study. Eficacia y seguridad de la aplicación del ácido

 © 2021. Sociedade Brasileira de Ortopedia e Traumatologia. All rights reserved.

tranexámico tópico en la artroplastia primaria no cementada de cadera: estudio prospectivo, aleatorizado, doble ciego y controlado. Rev Esp Cir Ortop Traumatol (Engl Ed). 2018;62(1):47-54
19 Liu W, Hui H, Zhang Y, Lin W, Fan Y. Intra-Articular Tranexamic Acid Injection During the Hip Hemi-Arthroplasty in Elderly Patients: A Retrospective Study. Geriatr Orthop Surg Rehabil 2018;9:2151459318803851
20 Kang JS, Moon KH, Kim BS, Yang SJ. Topical administration of tranexamic acid in hip arthroplasty. Int Orthop 2017;41(02): 259–263

 © 2021. Sociedade Brasileira de Ortopedia e Traumatologia. All rights reserved.