Article published online: 2022-02-09

THIEME OPEN ACCESS

Technical Note

# A Comparison Between Preoperative and Intraoperative Measurement and Classification of the Size of Rotator Cuff Tears*

## *Uma comparação entre a medição e a classificação da ruptura do manguito rotador no pré-operatório e no intraoperatório*

Karl Peter Gill[1,2] Marcus Bateman[3] Bruno Mazuquin[2] Chris Littlewood[2]

[1] Department of Physiotherapy, Northern Care Alliance NHS Group, Fairfield General Hospital, Bury, United Kingdom
[2] Department of Health Professions, Faculty of Health, Psychology and Social Care, Manchester Metropolitan University, Manchester, Greater Manchester, United Kingdom
[3] Derby Shoulder Unit, University Hospitals Derby and Burton NHS Foundation Trust, Derby, United Kingdom

**Address for correspondence** Karl Peter Gill, PhD, Department of Health Professions, Manchester Metropolitan University, Manchester, M15 6GX, United Kingdom (e-mail: P.Gill@mmu.ac.uk).

Rev Bras Ortop

**Abstract**

**Purpose** To evaluate the agreement in tear size obtained through preoperative imaging and intraoperative measurement, and to determine the accuracy of preoperative imaging in the classification of tear size and identification of tears in each rotator cuff tendon.

**Methods** Data from 44 patients recruited to a randomized controlled trial were reviewed retrospectively. Size and location of the rotator cuff tears were confirmed by either ultrasound or magnetic resonance imaging scans preoperatively and evaluated during surgery. A *t*-test and Bland and Altman plot were used to determine the agreement between the preoperative and intraoperative measurements. Sensitivity, specificity, positive predictive value (PPV) and negative predictive value (NPV) were calculated for tear size and involvement of the rotator cuff tendon.

**Results** There was good agreement in terms of the measurements (91%) and classification (89%) of the tear size preoperatively and during surgery. When classifying tear size, the sensitivity and PPV were high for medium-sized tears (100%) and lower for

**Keywords**
- rotator cuff tears
- shoulder
- magnetic resonance imaging
- ultrasonography

* *Study carried out by the Department of Health Professions, Manchester Metropolitan University, Manchester, UK.*

**received**
May 18, 2021
**accepted after revision**
September 20, 2021

**DOI** https://doi.org/10.1055/s-0041-1741445.
**ISSN** 0102-3616.

© 2022. Sociedade Brasileira de Ortopedia e Traumatologia. All rights reserved.
This is an open access article published by Thieme under the terms of the Creative Commons Attribution-NonDerivative-NonCommercial-License, permitting copying and reproduction so long as the original work is given appropriate credit. Contents may not be used for commercial purposes, or adapted, remixed, transformed or built upon. (https://creativecommons.org/licenses/by-nc-nd/4.0/)

Thieme Revinter Publicações Ltda., Rua do Matoso 170, Rio de Janeiro, RJ, CEP 20270-135, Brazil

large tears (75%), reflecting that all medium-sized tears but not all large tears were identified preoperatively. For the preoperative identification of the tears, the sensitivity and PPV were highest for the supraspinatus (84%), with progressively lower sensitivities and PPV for the infraspinatus (57%), subscapularis (17%) and teres minor (0%).

**Conclusions** Through preoperative imaging, the measurement or classification of the tear size can be accurately performed. Where there is disagreement, it is unclear whether the tear size is either underestimated on the scan or overestimated during surgery. The high sensitivity demonstrates that a supraspinatus tear is usually detected by scan. The lower sensitivities for the infraspinatus and subscapularis indicate that the identification of tears in these tendons is less accurate.

## Resumo

**Objetivo** Avaliar a concordância no tamanho de ruptura obtido por imagem pré-operatória e por medição intraoperatória, e determinar a precisão da imagem pré-operatória na classificação do tamanho da ruptura e na identificação de rupturas em cada tendão do manguito rotador.

**Métodos** Os dados de 44 pacientes recrutados para um ensaio controlado randomizado foram revisados retrospectivamente. O tamanho e a localização do manguito rotador foram confirmados por ultrassom ou ressonância magnética préoperatórios, e avaliados durante a cirurgia. Um teste *t* e o gráfico de Bland e Altman foram usados para determinar a concordância entre as medições pré-operatória e intraoperatória. Sensibilidade, especificidade, valor preditivo positivo (VPP) e valor preditivo negativo (VPN) foram calculados para o tamanho do rompimento e o envolvimento do tendão do manguito rotador.

**Resultados** Houve boa concordância para medidas de tamanho da ruptura (91%) e classificação (89%) pré-operatória e durante a cirurgia. Ao classificar o tamanho da ruptura, a sensibilidade e o VPP foram elevados para rupturas de tamanho médio (100%), e menor para rupturas grandes (75%), o que indica que todas as rupturas de tamanho médio, mas nem todas as grandes, foram identificadas pré-operatoriamente. Para a identificação de rupturas, a sensibilidade pré-operatória e o VPP foram maiores para o supraespinal (84%), com sensibilidade e VPP progressivamente menores para o infraespinal (57%), o subescapular (17%), e o redondo menor (0%).

**Conclusões** Por meio da imagem pré-operatória, pode-se medir ou classificar com precisão o tamanho da ruptura. Quando há discordância, não está claro se o tamanho da ruptura é subestimado no exame ou superestimado durante a cirurgia. A alta sensibilidade demonstra que uma ruptura do supraespinal é geralmente detectada por escaneamento. As sensibilidades mais baixas para o infraespinal e o subescapular indicam que a identificação de rupturas nestes tendões é menos precisa.

**Palavras-chave**
- lesões do manguito rotador
- ombro
- imagem por ressonância magnética
- ultrassonografia

## Introduction

Rotator cuff tears are a common cause of shoulder pain, and they are diagnosed through a combination of patient history, clinical examination, and diagnostic imaging. Whether through ultrasound (US) or magnetic resonance (MRI), imaging is used to determine the size and location of the tear.[1] It also enables tear classification as either small, medium, large, or massive.[2] Understanding the size and location of a rotator cuff tear is important for the purpose of surgical planning. If a tear is larger than previously expected based on imaging findings, for example, surgery may take longer, and other additional techniques may be needed.[3]

Both US and MRI have comparable high sensitivities and specificities for the diagnoses of rotator cuff tears. A Cochrane systematic review[4] reported that there were no differences in sensitivity and specificity between MRI and US for detecting full- or partial-thickness rotator cuff tears. The most common reference test is diagnostic arthroscopy, which enables a more accurate assessment of the tear characteristics and confirms the planned intervention.[4]

Given that both imaging modalities are used in the clinical practice and the findings are important for the purpose of surgical planning, the main aim of the present paper was to evaluate the agreement in tear size between

 © 2022. Sociedade Brasileira de Ortopedia e Traumatologia. All rights reserved.

preoperative imaging scans (US or MRI) and the intraoperative measurement as used pragmatically when screening patients for inclusion in a clinical trial, and to determine the sensitivity, specificity, positive predictive value (PPV) and negative predictive value (NPV) of preoperative imaging techniques in the classification of tear size. A further aim was to determine the sensitivity, specificity, PPV and NPV in the identification of tears in each rotator cuff tendon.

## Methods

The present is a retrospective study using data from a multicenter randomized controlled trial[5] (RCT) investigating different rehabilitation strategies following rotator cuff repair surgery. A favourable ethical review was granted by the Wales Research Ethics Committee 5 Bangor on July 31st, 2018 (18/WA/0242).

## Participants

Patients for the RCT were recruited from 5 National Health Service (NHS) hospitals between November 2018 and November 2019 according to the following criteria: age over 18 years and diagnosis of a non-traumatic, symptomatic full thickness rotator cuff tear listed for surgery.

The patients (n = 44) included in the present study underwent surgical repair of the rotator cuff and had pre- and intraoperative measurements available.

Eight surgeons treated at least one participant in the RCT.[5]

## Tear Measurement and Classification

The size, classification, and location of the rotator cuff tear were determined during the routine presurgical diagnostic work-up via US or MRI according to local pathways and clinical preference. A consultant radiologist or experienced musculoskeletal ultrasonographer evaluated the US. The MRI measurement was in an anteroposterior direction using axial, coronal and sagittal views. Data were subsequently obtained from clinical notes. The intraoperative measurement of size and classification were performed by comparison with the surgical instruments and undertaken by the surgeon in line with their usual practice. As a pragmatic approach was taken, standardization of the procedure, pre- or intraoperatively, was not enforced. Patients involved in the present study had rotator cuff tears that were classified as either medium (1–3 cm) or large (3–5 cm).[2]

## Data Analysis

A pairwise *t*-test was used to determine any differences between the pre- and intraoperative measurements of tear sizes (in centimeters).

A Bland and Altman plot determined the agreement between the reported pre- and intraoperative tear sizes.

Sensitivity, specificity, PPV, and NPV were calculated for the preoperative (US or MRI) tear classification, and each tendon (that is, whether a tear was identified in a specific tendon) relative to the intraoperative findings.

## Results

The pre- and intraoperative tear data are reported in ►**Table 1**.

The difference between the pre- and intraoperative measurements was statistically significant for tear size (0.3 cm; $p < 0.01$). In total, 34/44 (77%) cases had identical values for the pre- and intraoperative measurements of tear size. Of the 10 patients (23%) whose measurements were not identical, 7 (16%) had a difference of $\geq$ 1 cm between the pre- and intraoperative measurements, with the remaining 3 (7%) presenting a difference of 2 cm.

The limit of agreement was of 1.36 cm on the Bland and Altman plot (►**Figure 1**); as such, only 4 (9%) cases fell outside of these limits, resulting in 91% (40 cases) of agreement between the pre- and intraoperative measurements.

**Table 1** Mean tear size, classification, and number of tears in each rotator cuff tendon identified pre- and intraoperatively

| | Preoperative | Intraopertive | Match between both measurements |
|---|---|---|---|
| Tear size (cm) – mean (+standard deviation) | 2.4 ± 1.2 | 2.7 ± 1.3 | **34** |
| Number of medium tears | 29 | 24 | 24 |
| Number of large tears | 15 | 20 | 15 |
| Total | 44 | 44 | **39** |
| | Number of tears pre-operatively | Number of tears intra-operatively | Number tears matched pre- and intraoperatively |
| Supraspinatus | 37 | 44 | 37 |
| Infraspinatus | 8 | 11 | 4 |
| Subscapularis | 5 | 6 | 1 |
| Teres minor | 0 | 1 | 0 |

 © 2022. Sociedade Brasileira de Ortopedia e Traumatologia. All rights reserved.

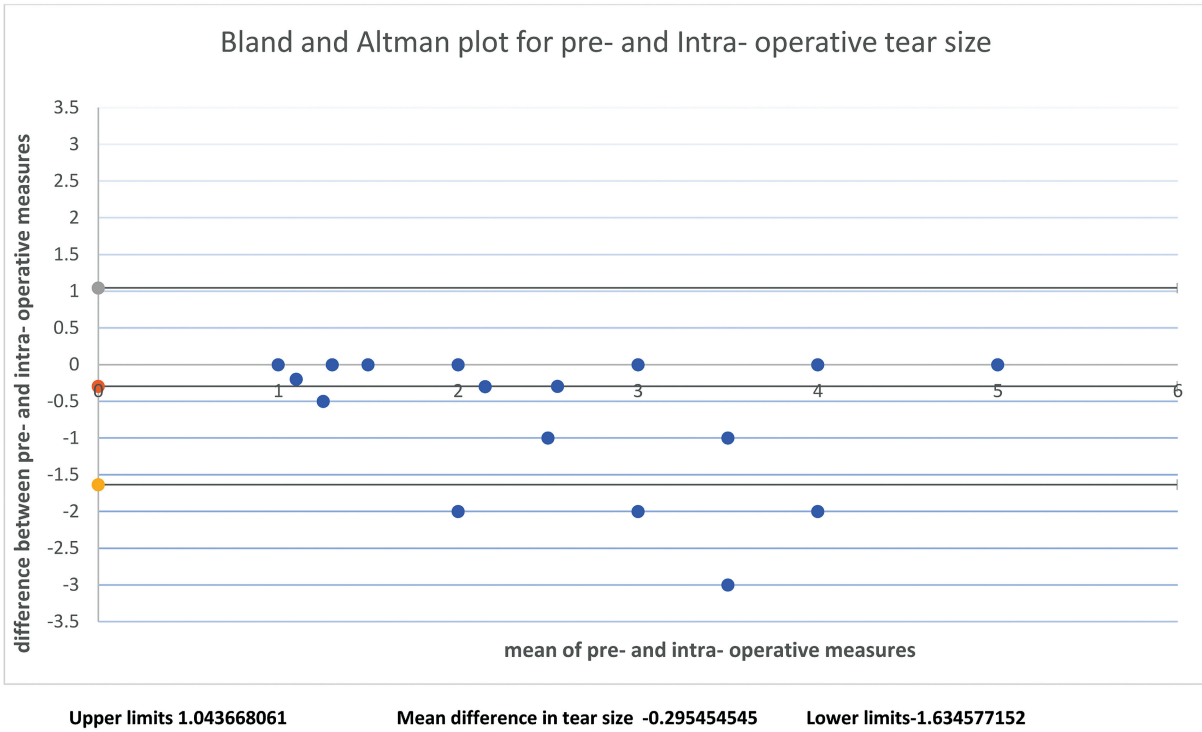


**Fig. 1** Bland and Altman plot between pre- and intraoperative tears. Upper limits: 1.043668061; mean difference in tear size: −0.295454545; lower limits: −1.634577152.

**Table 2** Sensitivity, specificity, and positive and negative predictive values for tear size and for each rotator cuff tendon

| | Sensitivity | Specificity | Positive predictive value | Negative predictive value |
|---|---|---|---|---|
| **Medium tears** | 100% | 75% | 83% | 100% |
| **Large tears** | 75% | 100% | 100% | 83% |
| **Supraspinatus** | 84% | 0 | 100% | 0% |
| **Infraspinatus** | 57% | 89% | 50% | 92% |
| **Subscapularis** | 17% | 89% | 20% | 87% |
| **Teres minor** | 0 | 100% | 0 | 98% |

In relation to the classification of tear size (that is, medium or large), there was agreement in 39/44 (89%) cases. The remaining 5 (11%) cases were identified as having large tears during surgery, but were classified as a medium-sized on the preoperative scan.

The sensitivity, specificity, PPV and NPV for tear classification and each tendon are reported in ►**Table 2**. The results for tear classification reflect that all medium-sized tears but not all large tears were identified preoperatively (5 large tears at surgery were classified as medium preoperatively). A sensitivity of 84% (and PPV of 100%) indicate that, when a tear in the supraspinatus tendon is present, it is usually identified on the scan. The sensitivity of 57% for the infraspinatus and of 17% for the subscapularis indicate increasing difficulty in identifying a tear in these tendons on a scan (low number of true-positives, with a relatively high number of false-negatives). Conversely, the high specificity and NPV for the infraspinatus (89%), subscapularis (89%), and teres minor (100%) indicate a relatively low number of false-positives in relation to the large number of true-negatives (with tears in these muscles being less common). During surgery, the supraspinatus tendon was found to be torn in every case; however, there were relatively fewer tears in other rotator cuff tendons: infraspinatus in 25%, subscapularis in 13.6%, and teres minor in 2% of the cases.

## Discussion

In the present study, the preoperative evaluation of rotator cuff integrity involved either US or MRI, which have been shown to be comparable, having similar sensitivities and specificities.[4] We found good agreement between preoperative imaging and intraoperative evaluation in terms of measurement and classification of rotator cuff tear. In 5 out of 44 cases (11%), the preoperative scans were reported as underestimating tear sizes, which were reclassified from medium to large tears when evaluated intraoperatively. The reason for this disagreement is unclear, but could be due to an

 © 2022. Sociedade Brasileira de Ortopedia e Traumatologia. All rights reserved.

underestimation when viewing the preoperative scans. As tears are in three dimensions, the orientation of the images may not have given the full extent of the tear, as tears may have different shapes, such as U-shaped, crescentic and L-shaped. A previous study[6] reported differing degrees of difficulty when identifying certain tears (especially L-shaped tears) when using magnetic resonance arthrography in comparison to arthroscopic findings. Conversely, a lack of a standardised approach to the intraoperative measurement might have contributed to any disagreement in measurement and classification, as the tear may have been measured in such a way as to report the largest value, or it may have been stretched or distorted to accommodate the tool used for measurement. The tear may have also progressed in size in the period between the performance of the preoperative scan and surgery, which is another potential source of disagreement.[7]

A second aim was to determine the sensitivity, specificity, PPV and NPV for the location of the rotator cuff tear. In the present study, the preoperative US or MRI was found to generally underreport the frequency of tears in the rotator cuff tendons (►**Table 2**). Preoperative scanning was most sensitive at identifying tears in the supraspinatus, but progressively less sensitive at identifying tears within the infraspinatus, subscapularis, and teres minor. Previous research[8] looking at the agreement between US and MRI found a similar pattern with greatest agreement in relation to the supraspinatus and infraspinatus, with the subscapularis evaluation proving the source of greatest disagreement. The difficulty in identifying a specific location of the rotator cuff tear may be due to the intimate nature of the rotator cuff and the merging of the tendons (rather than being distinctly separate structures) as they insert into the humerus and, as such, interpretation of the US/MRI preoperatively and tendon identification during surgery may be open to error.

## Strengths and Limitations

A pragmatic approach was taken when US or MRI was used as part of the routine diagnostic work-up prior to surgery. The tntraoperative measurement of tear size was an estimate in relation to the surgical instruments. Data were extracted from clinical notes, and the measurement processes were not standardized. The extent to which the choice of imaging modality and method of reporting contributed to any disagreement is unknown. However, despite the pragmatic nature of the measurements in the present study, the good agreement between the preoperative scans and intraoperative findings regarding tear size and the tendons involved is reassuring from a surgical planning perspective.

## Conclusions

Preoperative imaging, US or MRI, can be used to accurately measure or classify (medium or large) rotator cuff tears. In case of disagreement, it is unclear whether the tears are either underestimated during the preoperative scanning, or overestimated during the intraoperative evaluation.

The high sensitivity demonstrates that a supraspinatus tear is usually detected by preoperative US or MRI, but identification of a tear in the infraspinatus, subscapularis, or teres minor tendons is more problematic.

Financial Support
The present RCT, from which this data was derived, was funded by the National Institute for Health Research (NIHR) Research for Patient Benefit programme (PB-PG-0816-20009). CL is supported by an NIHR Postdoctoral Fellowship, (PDF-2018-11-ST2-005). The views expressed are those of the author(s), and not necessarily those of the NIHR or the Department of Health and Social Care.

Conflict of Interests
The authors have no conflict of interests to declare.

## References

1 Spencer EE Jr, Dunn WR, Wright RW, et al Shoulder Multicenter Orthopaedic Outcomes Network. Interobserver agreement in the classification of rotator cuff tears using magnetic resonance imaging. Am J Sports Med 2008;36(01):99–103
2 DeOrio JK, Cofield RH. Results of a second attempt at surgical repair of a failed initial rotator-cuff repair. J Bone Joint Surg Am 1984;66(04):563–567
3 Chalmers PN, Tashjian RZ. Patch Augmentation in Rotator Cuff Repair. Curr Rev Musculoskelet Med 2020;13(05):561–571
4 Lenza M, Buchbinder R, Takwoingi Y, Johnston RV, Hanchard NC, Faloppa F. Magnetic resonance imaging, magnetic resonance arthrography and ultrasonography for assessing rotator cuff tears in people with shoulder pain for whom surgery is being considered. Cochrane Database Syst Rev 2013;2013(09):CD009020
5 Littlewood C, Bateman M, Butler-Walley S, et al. Rehabilitation following rotator cuff repair: A multi-centre pilot & feasibility randomised controlled trial (RaCeR). [published online ahead of print, 2020 Dec 11]Clin Rehabil 2021;35(06):829–839
6 Lee YH, Kim AH, Suh JS. Magnetic resonance visualization of surgical classification of rotator cuff tear: comparison with three-dimensional shoulder magnetic resonance arthrography at 3.0 T. Clin Imaging 2014;38(06):858–863
7 Yamamoto N, Mineta M, Kawakami J, Sano H, Itoi E. Risk Factors for Tear Progression in Symptomatic Rotator Cuff Tears: A Prospective Study of 174 Shoulders. Am J Sports Med 2017;45(11): 2524–2531
8 Fischer CA, Weber MA, Neubecker C, Bruckner T, Tanner M, Zeifang F. Ultrasound vs. MRI in the assessment of rotator cuff structure prior to shoulder arthroplasty. J Orthop 2015;12(01):23–30

 © 2022. Sociedade Brasileira de Ortopedia e Traumatologia. All rights reserved.