Article published online: 2022-03-11

THIEME OPEN ACCESS

Case Report

Isolated Tillaux Fracture in Adults – Literature Review Based on a Rare Case Report

Fratura isolada de Tillaux em adultos – Revisão da literatura com base em um relato de caso raro

Nuno Vieira da Silva[1] Ana Esteves[1] Pedro Ribeiro[1] José Miradouro[1] Joana Pereira[1] Julio Marinheiro[1]

[1] Orthopaedic and Traumatology Department, Centro Hospitalar do Tâmega e Sousa, Penafiel, Portugal.

Address for correspondence Nuno Vieira da Silva, MD, Centro Hospitalar do Tâmega e Sousa, Penafiel, Portugal (e-mail: navsilva93@gmail.com).

Rev Bras Ortop

Abstract

Isolated Tillaux fracture is a rare anterolateral distal tibia fracture frequently misdiagnosed in adults. It typically occurs in adolescents nearing skeletal maturity by avulsion of the anterior-inferior tibiofibular ligament. This case-based literature review study aims to elicit the existing information regarding this fracture in adults, and summarize its injury mechanism, diagnosis, and treatment procedures. According to the literature, this is only the eighth case described: a 46-year-old woman that suffered an isolated Tillaux fracture with 4 mm of displacement, and open reduction and fixation with double cannulated screws were performed. After proper rehabilitation, an excellent functional and radiological outcome was reached. It is important to recognize and appropriately treat these distinct injuries to prevent further instability, degenerative changes, and ankle joint function limitation. Early diagnosis and appropriate osteosynthesis play a significant role in a successful recovery prognosis.

Keywords
- ankle fractures
- ankle injuries
- tibial fractures
- bone screws

Resumo

A fratura isolada de Tillaux representa uma rara e frequentemente mal diagnosticada fratura de tíbia distal anterolateral em adultos. Normalmente ocorre em adolescentes que se aproximam da maturidade esquelética por avulsão do ligamento tibiofibular anteroinferior. Este estudo de revisão de literatura baseada em caso tem como objetivo lembrar a existência dessa identidade em adultos, resumir seu mecanismo de lesão, diagnóstico e procedimentos de tratamento. De acordo com a literatura, este é apenas o oitavo caso descrito: uma mulher de 46 anos sofreu uma fratura isolada de Tillaux com 4mm de deslocamento e realizaram-se redução e fixação aberta com parafuso

Palavras-chave
- fraturas do tornozelo
- traumatismos do tornozelo
- fraturas da tíbia
- parafusos ósseos

This work was developed at the Centro Hospitalar do Tâmega e Sousa, Penafiel, Portugal.

received
May 23, 2021
accepted
January 3, 2022

DOI https://doi.org/10.1055/s-0042-1743270.
ISSN 0102-3616.

© 2022. Sociedade Brasileira de Ortopedia e Traumatologia. All rights reserved.
This is an open access article published by Thieme under the terms of the Creative Commons Attribution-NonDerivative-NonCommercial-License, permitting copying and reproduction so long as the original work is given appropriate credit. Contents may not be used for commercial purposes, or adapted, remixed, transformed or built upon. (https://creativecommons.org/licenses/by-nc-nd/4.0/)

Thieme Revinter Publicações Ltda., Rua do Matoso 170, Rio de Janeiro, RJ, CEP 20270-135, Brazil

canulado duplo. Após a reabilitação adequada, alcançou-se um excelente desfecho funcional e radiológico. É importante reconhecer e tratar adequadamente essas lesões distintas para evitar maiores instabilidades, alterações degenerativas e limitação da função articular do tornozelo. Um diagnóstico precoce e a osteossíntese apropriada desempenham um papel significativo em um prognóstico de recuperação bem-sucedido.

Introduction

Tillaux fractures are avulsion fractures of the anterior-inferior tibiofibular ligament (AITFL) from its tibial attachment, which typically occur in adolescents nearing skeletal maturity (12–14-years-old). This fracture pattern has not been commonly seen in an older population, since the ligaments usually fail before the bone.[1]

The incidence of isolated Tillaux fractures in adults has not been quantified in the current data, as it has been more commonly seen in association with other injuries. According to the literature, only 7 case reports have been published regarding this entity.[2]

The present case-report-based literature review aims to elicit the existing information regarding isolated Tillaux fractures in adults and provide a summary about its mechanism of injury, diagnosis, and treatment procedures.

Case Report

A 46-year-old woman was admitted to the emergency department after a domestic ankle trauma with external rotation mechanism. Physical examination revealed tenderness and swelling over the anterolateral aspect of the ankle with normal but painful passive range of motion.

The images of x-ray (►**Fig. 1**) and computed tomography (CT) scan (►**Fig. 2**) showed an isolated Tillaux fracture with 4 mm of fragments displacement and anterior disruption of the syndesmosis. Open reduction and fixation were performed with 2 cannulated 4.0 screws, perpendicular to the fracture line by a mini-open anterolateral approach—proximally centered between the tibia and fibula, and distally extended in line with the fourth metatarsal in an intermuscular plane between the peroneus brevis and tertius. The superficial peroneal nerve runs anterior to the fibula and requires identification in the proximal extent of the incision.[3]

Fluoroscopic imaging (►**Fig. 3**) was used intraoperatively to confirm fracture reduction, correct positioning of the screws, and syndesmotic stability with the negative external rotation stress test.

Postoperatively, a short leg cast was prescribed during 4 weeks for fear of patient's lack of compliance with the no weight-bearing discharge instructions. Mobilization started at the 4th week, partial weight-bearing was allowed from the 6th week onwards, and was gradually increased according to clinical and radiological evidence of union up to full weight-bearing and normal walking.

After 4 months of proper rehabilitation, the patient exhibited an excellent clinical and functional outcome, scoring 80 in the Karlsson scale. A postoperative control CT scan (►**Fig. 4**) confirmed a successful bone healing.

Discussion

Historically, this fracture pattern has been noted in the adolescent population due to the pattern of progression of physeal closure and classified as a Salter-Harris III fracture through the epiphysis.[4]

Ankle syndesmosis is formed by the distal tibia and fibula, and it is stabilized by four ligaments: the anterior, transverse, and posterior tibiofibular ligaments, as well as the interosseous membrane.[2]



Fig. 1 Preoperative X-ray view: (**A**) anteroposterior and (**B**) lateral.

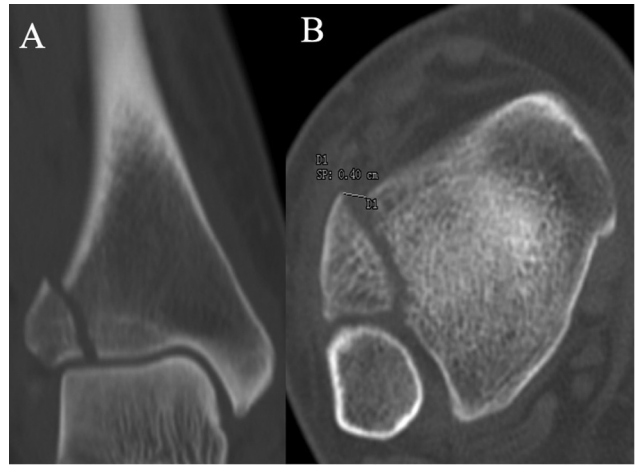

Fig. 2 Preoperative CT scan view: (**A**) coronal and (**B**) axial.

 © 2022. Sociedade Brasileira de Ortopedia e Traumatologia. All rights reserved.

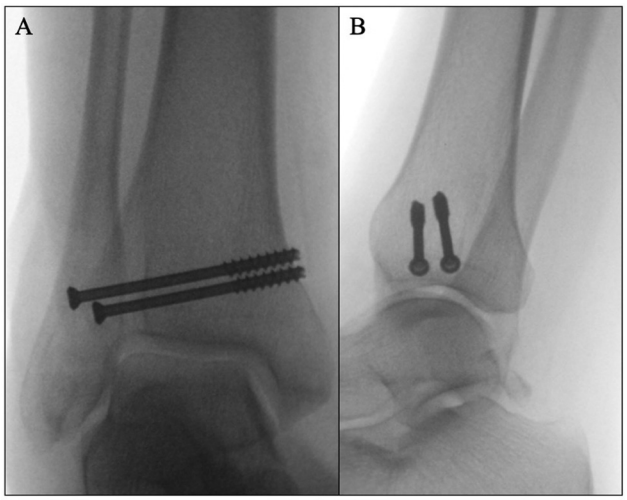

Fig. 3 Intraoperative fluoroscopic imaging view: (**A**) anteroposterior and (**B**) lateral.

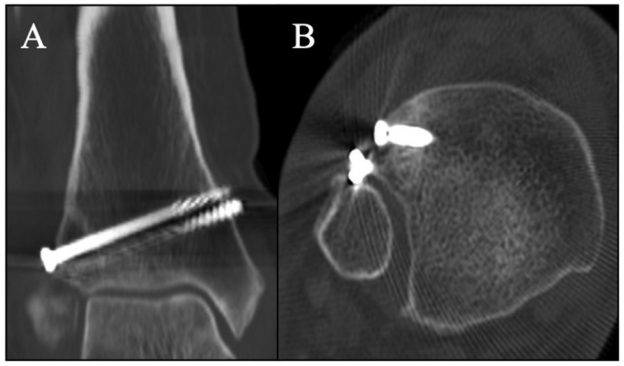

Fig. 4 Postoperative control CT scan view: (**A**) coronal and (**B**) axial.

Supination and external rotation (SER) were identified as the most common mechanism of injury; leading to avulsion of the anterolateral tibia site of attachment of the anterior inferior tibiofibular ligament. This mechanism of injury is typically divided into 4 stages. However, in isolated Tillaux fracture scenarios, the sequence of events ends at stage 1, since no fibula fracture, posterior osseous injury, or medial involvement are present.[1] Fall from height is also described as a possible injury mechanism.[2]

Nondisplaced Tillaux fractures are often almost unrecognizable on standard X-ray projections and may be misdiagnosed as a simple sprain due to its challenging diagnosis. Stress X-ray imaging and oblique projection should be used as supplemental diagnostictools.[1] Additional CT evaluation is also recommended for determining the distance of displacement, fracture fragments shape, and conditions of the articular surface.[4]

In adult Tillaux fractures the avulsed fragment is generally triangular, while in juvenile Tillaux fractures it is quadrangular.[5]

A total of three main types of fractures can be differentiated: (1) extra-articular avulsion fracture of the AITFL, (2) fracture of the anterolateral distal tibia with involvement of the articular surface, and (3) impaction fracture of the anterolateral tibial plafond.[6]

Nondisplaced fractures (< 2 mm) with no evidence of syndesmosis instability can be managed conservatively by long leg cast with internally rotated foot. Since the strong anteroinferior ligament is attached to the fibula, it renders the bone displaced and angulated, causing syndesmotic incompetency. Therefore, a displaced fracture (> 2mm) is an indication for close or open reduction and internal fixation.[7]

Conservative treatment of dislocated fragments leads to non-union and post-traumatic osteoarthritis. Impaction fractures can lead to secondary avascular necrosis of the anterolateral tibial plafond.[6]

The aim of surgical fixation of displaced anterolateral distal tibial fractures is the anatomical stabilization of the anterior syndesmosis and restoration of the tibial incisura for the distal fibula and joint surface. A type 1 fracture may be fixed with an anchor or transosseous suture, type 2 is mostly fixed with screws, and type 3 may need bone grafting of the impaction zone for restoration of the joint surface and buttress plating.[6]

It is not yet clear whether the fibula should be temporarily fixed to the tibia but, irrespective of the type of treatment, fixation for six weeks with instructions not to load the injured limb is indicated.[2]

Open reduction can be done by anterior or anterolateral approach—it should depend on the extent of the fracture line. Using the anterolateral approach, a second approach to address a medial component is often necessary in more severe injuries. On the other hand, using the anterior approach, the entire anterior portion of the distal tibia is accessible, but the neurovascular bundle is at higher risk both proximally and distally.[3]

Percutaneous fixation techniques have also been described to treat this injury, predominantly among adolescents.[8] Arthroscopically assisted fixation technique has been described but no actual literature evidence suggests that this method is overall superior to traditional open reduction.[9] It represents a more accurate method with treatment possibility of any associated intra-articular pathology and lower risk of infection, bleeding, and biological damage to structures.[1]

As a mainly intra-articular fracture, anatomical reduction, absolute stability, and early mobilization are the most important factors to ensure a better functional outcome.[10]

Conclusion

Isolated Tillaux fractures in adults may be indicative of a syndesmotic ankle injury. It is important to recognize and appropriately treat these distinct injuries to prevent further instability, degenerative changes, and ankle joint function limitation.

In addition to the rare occurrence in adulthood, another feature of this fracture is that it is challenging to detect, being easily overlooked. An early diagnosis and appropriate osteosynthesis play a significant role in a successful recovery prognosis.

 © 2022. Sociedade Brasileira de Ortopedia e Traumatologia. All rights reserved.

Financial Support
This study received no financial support from public, commercial or non-profit sources.

Conflict of Interests
The authors have no conflict of interests to declare.

References

1 Kose O, Yuksel HY, Guler F, Ege T. Isolated Adult Tillaux Fracture Associated With Volkmann Fracture-A Unique Combination of Injuries: Report of Two Cases and Review of the Literature. J Foot Ankle Surg 2016;55(05):1057–1062
2 Gasparova M, Falougy HE, Kubikova E, Almasi J. Isolated "Tillaux" fracture in adulthood: rarity where the key of success is not to miss it. Bratisl Lek Listy 2020;121(08):533–536
3 Hickerson LE, Verbeek DO, Klinger CE, Helfet DL. Anterolateral Approach to the Pilon. J Orthop Trauma 2016;30(Suppl 2):S39–S40
4 Oak NR, Sabb BJ, Kadakia AR, Irwin TA. Isolated adult Tillaux fracture: a report of two cases. J Foot Ankle Surg 2014;53(04): 489–492
5 Sharma B, Reddy IS, Meanock C. The adult Tillaux fracture: one not to miss. BMJ Case Rep 2013;2013:bcr2013200105
6 Rammelt S, Bartoníček J, Neumann AP, Kroker L. [Fractures of the anterolateral tibial rim : The fourth malleolus]. Unfallchirurg 2021;124(03):212–221
7 Mishra PK, Patidar V, Singh SP. Chaput Tubercle Fracture in an Adult- A Rare Case Report. J Clin Diagn Res 2017;11(03): RD01–RD02
8 Feng SM, Sun QQ, Wang AG, Li CK. "All-Inside" Arthroscopic Treatment of Tillaux-Chaput Fractures: Clinical Experience and Outcomes Analysis. J Foot Ankle Surg 2018;57(01):56–59
9 Kumar N, Prasad M. Tillaux fracture of the ankle in an adult: a rare injury. J Foot Ankle Surg 2014;53(06):757–758
10 Syed T, Storey P, Rocha R, Kocheta A, Singhai S. Tillaux Fracture in Adult: A Case Report. Ortho J MPC 2020;26(02):95–98. Available from: https://ojmpc.com/index.php/ojmpc/article/view/126

 © 2022. Sociedade Brasileira de Ortopedia e Traumatologia. All rights reserved.