Article published online: 2022-06-02

THIEME OPEN ACCESS

Original Article

Outcomes of the Carlson Approach in the Treatment of Posterior Tibial Plateau Fractures

Resultados da abordagem de Carlson para o tratamento de fraturas no platô tibial posterior

Jonatas Brito de Alencar Neto[1,2] Itallo Epaminondas de Queiroz Rego[1]
Márcio Bezerra Gadelha Lopes[1,2] Lana Lacerda de Lima[3,4] Renata Clazzer[3] Diego Ariel de Lima[3,4]

[1] Division of Orthopedics and Traumatology, Instituto Doutor José Frota, Fortaleza, CE, Brazil
[2] Knee Surgery Group, Clínica Articular, Fortaleza, CE, Brazil
[3] Division of Orthopedics and Traumatology, Hospital Tarcísio Maia, Mossoró, RN, Brazil
[4] Department of Health Sciences, Universidade Federal Rural do Semi-Árido – UFERSA, Mossoró, RN, Brazil

Address for correspondence Diego Ariel de Lima, MD, PhD, Universidade Federal Rural do Semi-Árido, Rua Francisco Mota, 572, Pres. Costa e Silva, Mossoró, RN, 59625-900, Brazil (e-mail: arieldelima.diego@gmail.com).

Rev Bras Ortop

Abstract

Objectives To describe a series of cases of tibial fractures surgically treated using the posterior approach as described by Carlson, focusing on evaluating its functional results and complication rate.

Methods Eleven patients with tibial plateau fractures, who underwent surgical treatment using the Carlson approach from July to December 2019, were followed-up. The minimum follow-up period was defined as 6 months. The American Knee Society Score (AKSS), American Knee Society Score/Function (AKSS/Function) and the Lysholm score were used to check treatment results at 6 months after the fracture. The patients underwent standard anteroposterior and lateral radiographs to assess fracture healing, and clinical healing was determined by the absence of pain during full weight-bearing.

Results The mean follow-up period was 12 months (9–16 months). The primary mechanism of trauma was motorcycle accident, and the most prevalent side of fracture was the right side. Eight participants were male. The mean age of the patients was 28 years. All fractures healed, and none of the patients presented complications. The AKSS was excellent in 11 patients, with a mean AKSS/Function of 99.1 ± 3, and Lysholm scores with a median of 95.0 ± 5.6.

Conclusions The Carlson approach for posterior fractures of the tibial plateau can be considered safe, presenting a low complication rate and satisfactory functional results.

Keywords
- tibial fractures
- surgical procedures, operative
- rehabilitation

* *Work developed at the Instituto José Frota, Fortaleza, CE, Brasil.*

received
December 6, 2021
accepted
March 28, 2022

DOI https://doi.org/10.1055/s-0042-1749200.
ISSN 0102-3616.

© 2022. Sociedade Brasileira de Ortopedia e Traumatologia. All rights reserved.
This is an open access article published by Thieme under the terms of the Creative Commons Attribution-NonDerivative-NonCommercial-License, permitting copying and reproduction so long as the original work is given appropriate credit. Contents may not be used for commercial purposes, or adapted, remixed, transformed or built upon. (https://creativecommons.org/licenses/by-nc-nd/4.0/)

Thieme Revinter Publicações Ltda., Rua do Matoso 170, Rio de Janeiro, RJ, CEP 20270-135, Brazil

Resumo

Objetivos O objetivo deste trabalho é descrever uma série de casos de fraturas de tíbia submetidas ao tratamento cirúrgico pela via posterior de Carlson para avaliação de resultados funcionais e frequência de complicações.

Métodos Onze pacientes com fraturas do platô tibial foram submetidos a tratamento cirúrgico pela via de Carlson de julho a dezembro de 2019 e acompanhados por um período mínimo de 6 meses. As pontuações *American Knee Society Score* (AKSS), *American Knee Society Score/Function* (AKSS/Função) e de Lysholm verificaram os resultados do tratamento 6 meses após a fratura. Os pacientes foram submetidos a radiografias comuns em incidência anteroposterior e de perfil para avaliação da consolidação da fratura, e a cicatrização clínica foi determinada pela ausência de dor à descarga total de peso.

Resultados O período médio de acompanhamento foi de 12 meses (9–16 meses). O principal mecanismo de trauma foi acidente motociclístico, e a fratura foi mais prevalente no lado direito. Oito pacientes eram do sexo masculino. A média de idade dos pacientes foi de 28 anos. Todas as fraturas cicatrizaram e nenhum paciente apresentou complicações. A AKSS foi excelente em 11 pacientes, com AKSS/Função média de $99{,}1 \pm 3$, e a mediana das pontuações de Lysholm foi de $95{,}0 \pm 5{,}6$.

Conclusões Nas fraturas posteriores do platô tibial a abordagem de Carlson pode ser considerada segura apresentando baixo índice de complicações e resultados funcionais satisfatórios.

Palavras-chave

- fraturas da tíbia
- procedimentos cirúrgicos operatórios
- reabilitação

Introduction

Tibial plateau fractures represent 1 to 2% of all fractures and approximately 8% of fractures in the elderly.[1] The mechanism of injury consists of an axial force with the knee flexed. The position of the knee (varus, valgus, or neutral) determines the location of the fracture in the posterior column of the tibial plateau (medial, lateral, or both, respectively).[2] The incidence rate of posteromedial and/or posterolateral fractures is approximately 30%.[2–7]

Access to the posterior region of the knee is often considered a difficult task due to the depth of the operative field and the presence of vascular and nervous elements that pass through it. Approaches used in posterior tibial plateau fractures (PTPFs) have undergone significant changes in recent years.[8]

Among the most used surgical access options for the treatment of posterior fractures, some stand out, such as the direct posterolateral approach in S without fibular osteotomy, the transfibular osteotomy approach, partial ostectomy of the fibular head, the direct posteromedial approach in S, and, less frequently, the posteromedial reversed L-shaped approach.[9–11]

The aim of the present study was to describe a case series of surgical treatment of PTPF conducted using the posterior approach as described by Carlson,[9] analyzing, during the follow-up, the quality of the reduction and the functional results obtained with this approach.

Methods

The present study was approved by the Ethics Committee (CAEE- 27128619.6.0000.5047).

During 2019, 11 patients were submitted to the Carlson[9] approach for PTPFs (through a posteromedial and posterolateral approach). All surgeries were performed by two surgeons with expertise in knee fractures. All fractures were classified by two expert knee fracture surgeons according to the Schatzker, Schatzker and Kfuri, Hohl and Moore, Luo, and the Osteosynthesefragen/Association for the Study of Internal Fixation (AO/ASIF) classification methods (►**Table 1**).[4–8] All patients were followed up with regular clinical and radiological assessments.

The American Knee Society Score (AKSS), American Knee Society Score/Function (AKSS/Function), and the Lysholm score were used to check treatment results at 6 months after the fracture. The patients underwent standard anteroposterior and lateral radiographs to assess fracture healing during follow-up, and clinical healing was determined by the absence of pain during full weight bearing.

Surgical Technique

Carlson[9] described two independent S-shaped approaches for the posteromedial and posterolateral regions of the tibial plateau without fibular osteotomy. After carrying out the operating room safety protocol and administering a prophylactic antibiotic (1 g of intravenous cefazolin), the patient was submitted to spinal anesthesia.

The approach begins with a smooth curvilinear S-shaped incision on the posteromedial side of the knee (►**Figure 1**), proceeding with careful dissection, due to the proximity of the saphenous nerve, visualizing the insertion of the semimembranosus muscle, which is lifted with the popliteal fascia, exposing the posteromedial plateau fracture. On the posterolateral side of the knee, a similar S-shaped incision (►**Figure 2**) is made over the femoral biceps muscle. The fibular nerve is identified on the posterior side of the biceps femoris muscle, being exposed proximally and distally. Then,

 © 2022. Sociedade Brasileira de Ortopedia e Traumatologia. All rights reserved.

Table 1 Mechanism of injury, fixation methods, and complications

Patients	Age	Mechanism	Time until surgery (days)	Classification				
				Shatzker	Schatzker/ Kfuri	Moore	AO/ASIF	Luo
1	47	Motorcycle accident	3	III	V P ML	I	41B2.2	Posterior column (medial and lateral)
2	30	Motorcycle accident	1	III	V P ML	I	41B2.2	Posterior column (medial and lateral)
3	23	Sports trauma	3	IV	V P ML	V	41C.1	Posterior column (medial and lateral)
4	19	Motorcycle accident	5	III	V P ML	IV	41B2.3	Posterior column (medial and lateral)
5	28	Motorcycle accident	2	III	V P ML	I	41B2.3	Posterior column (medial and lateral)
6	41	Motorcycle accident	2	III	V P ML	IV	41B2.2	Posterior column (medial and lateral)
7	19	Motorcycle accident	4	V	V P ML	V	41C1	Posterior column (medial and lateral)
8	22	Motorcycle accident	9	III	V P ML	IV	41B2.2	Posterior column (medial and lateral)
9	28	Motorcycle accident	18	II	V P ML	II	41B3.1	Posterior column (medial and lateral)
10	29	Motorcycle accident	12	V	V P ML	V	41C1	Posterior column (medial and lateral)
11	22	Motorcycle accident	10	II	V P ML	I	41B2.2	Posterior column (medial and lateral)

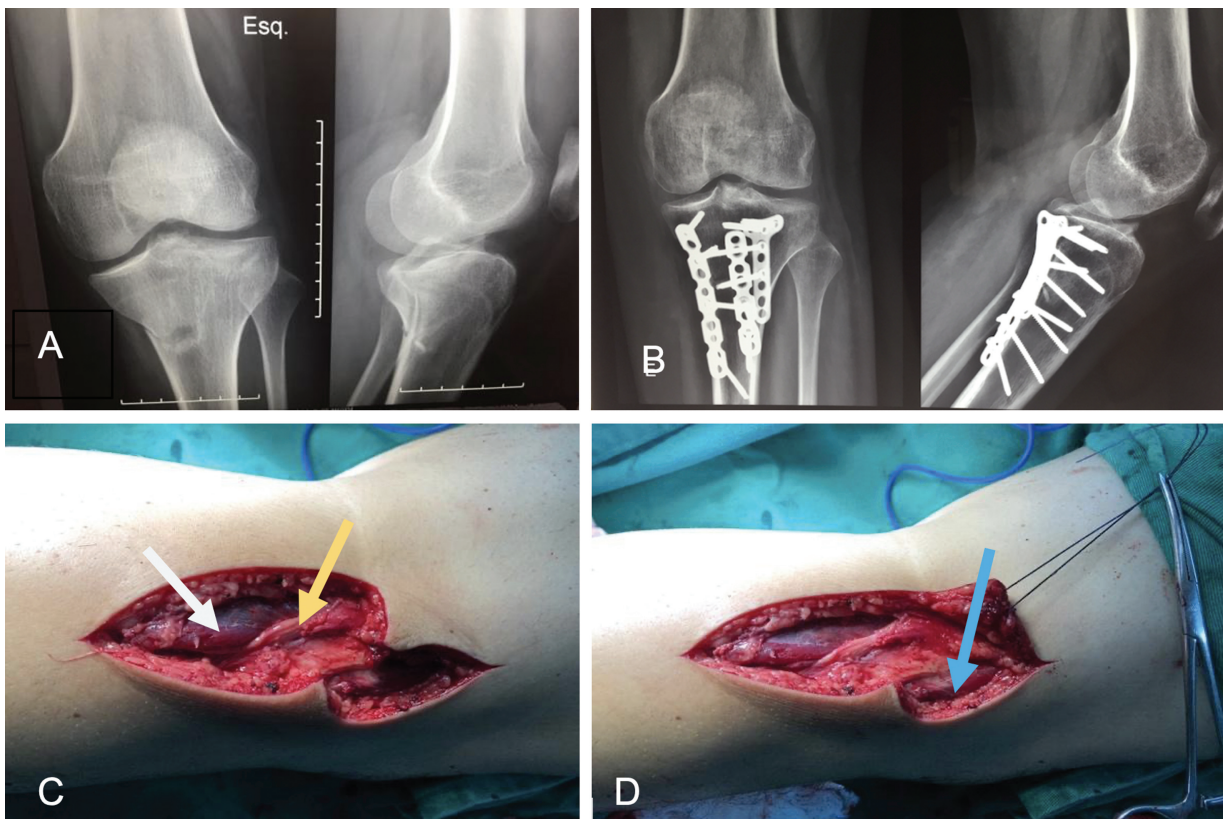

Fig. 1 (A) Anteroposterior and lateral radiographs showing a fracture of the posterior column of the left tibial plateau. (**B**) Postoperative images of anteroposterior and lateral radiographs of the left knee evidencing fracture reduction and internal fixation with a 3.5-mm T plate (Lateral) + 3.5 reconstruction plate (medial) + 3.5 reconstruction plate (central). (**C and D**) Intraoperative images showing a lateral Carlson incision in a posterolateral curvilinear "S" shape. White arrow - Lateral head of the gastrocnemius muscle. Yellow arrow - Fibular nerve. Blue arrow - Lateral head of the biceps femoris muscle.

 © 2022. Sociedade Brasileira de Ortopedia e Traumatologia. All rights reserved.

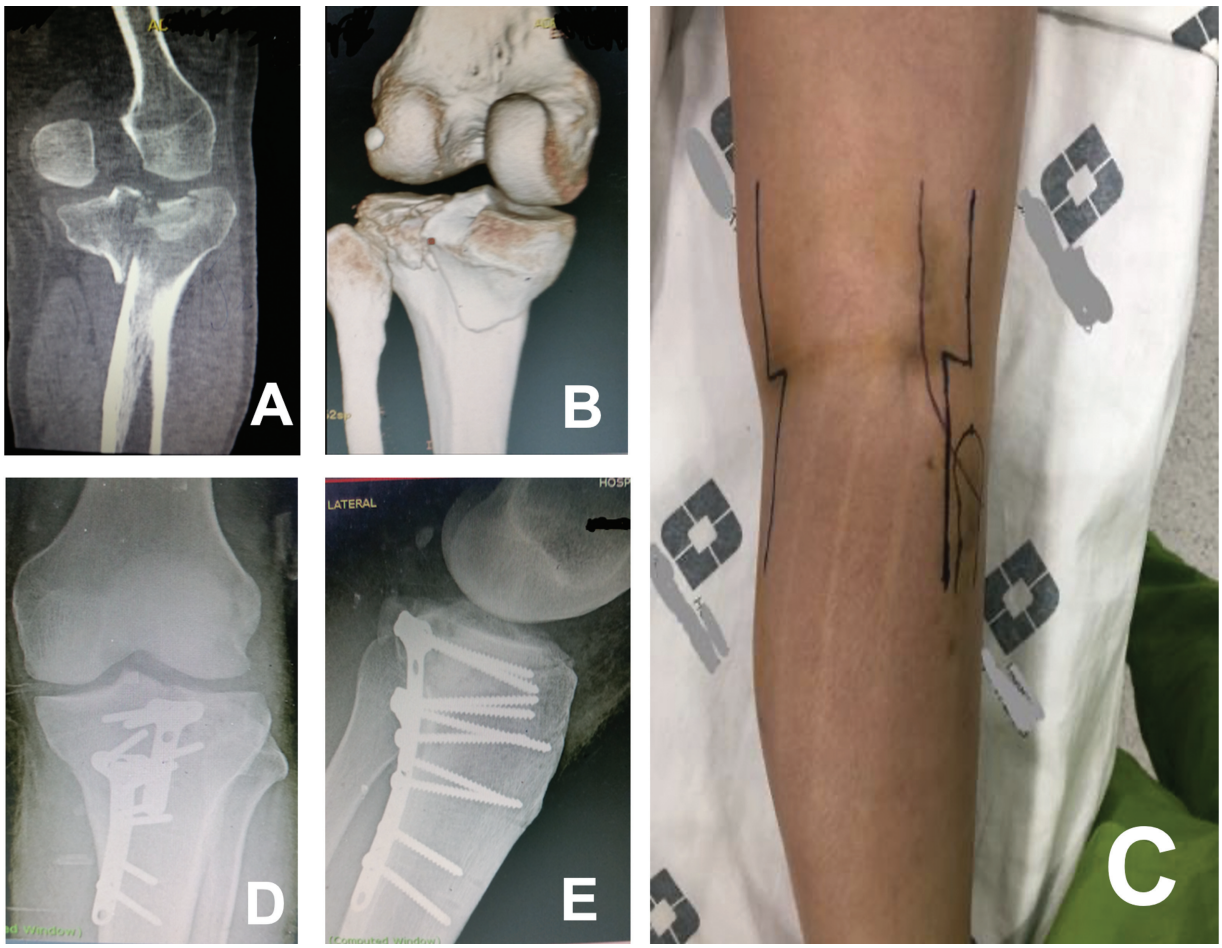

Fig. 2 (A) Coronal section computed tomography, evidencing the lateral depression and medial shear of the joint surface. **(B)** 3D reconstruction of computed tomography showing a posteromedial shear. **(C)** Carlson's "S"-shaped lateral and medial operative incision. **(D and E)** Postoperative anteroposterior and lateral radiographs revealing fracture.

the lateral head of the gastrocnemius muscle is retracted medially, allowing the visualization of the soleus muscle insertion. The popliteal tendon can be moved proximally, thus exposing the posterolateral plateau fracture. At this point, careful positioning of the retractors is required. A Hohmann retractor must be placed directly on the bone under direct visualization and verifying correct placement. For this, a Langenbeck retractor is very useful. A Hohmann retractor may be placed in the posteromedial cortical border. After visualizing the fracture, it is reduced and fixed with small fragment conventional plates, 3.5-mm reconstruction plates, or T plates with or without traction screws.

After surgery, the patients remained without weight bearing on the operated limb for 3 weeks. Range-of-motion exercises were allowed from the first postoperative day. Also, isometric strengthening exercises were commenced from day 1. No immobilizers, braces, or orthoses were used.

Statistical Analysis

The data were analyzed using the IBM SPSS Statistics for Windows, Version 23.0 software (IBM Corp., Armonk, NY, USA). Comparisons with *p*-values up to 0.05, with a 95% confidence interval, were considered significant. To compare two paired groups, a non-parametric Wilcoxon signed-rank test was used.

Results

The mean follow-up period was 12 months (9–16 months), and all fractures had healed by then. No discrepancies or deformities of the lower limbs were observed, nor did any of the patients present superficial or deep infection. In all cases, dorsiflexion strength of the ankle and toes was symmetrical to that of the non-operated limb (►**Table 1**).

Of the 11 patients who took part in the study, 8 were male (72.7%). The primary mechanism of trauma was motorcycle accident (90.9%), and the most prevalent side of fracture was the right side (63.6%). In this study, the mean age of the participants was 28 years, ranging from 10 to 47 years (►**Table 1**).

The mean duration of surgery was 100 minutes, varying between 70 and 130 minutes. Conventional implants were used (3.5 non-locking plates) in most of the patients (90.90%). Anatomical reduction was achieved in 72.7% of the participants, evaluated through conventional X-ray examination. In 2 patients (18.18%) with bone failure, a bone graft was inserted to cover the defect. In one case,

 © 2022. Sociedade Brasileira de Ortopedia e Traumatologia. All rights reserved.

Table 2 Intraoperative variables

Patients	Duration of surgery (in minutes)	Bone graft	Fixation type	Quality of the reduction	Complications
1	70'	No	3.5 T plate (lateral) + 3.5 T plate (medial)	Anatomical	No
2	93'	No	3.5 T plate (lateral) + 3.5 T plate (medial)	Anatomical	No
3	130'	Yes (iliac)	3.5 T plate (lateral) + 3.5 T plate (medial)	Anatomical	No
4	100'	No	3.5 T plate (lateral) + 3.5 T plate (medial)	Anatomical	No
5	112'	No	3.5 T plate (lateral) + 3.5 T plate (medial) - locking	Anatomical	No
6	83'	Yes (synthetic)	3.5 T plate (lateral) + 3.5 T plate (medial) + cannulated screw	Anatomical	No
7	97'	No	3.5 T plate (lateral) + 3.5 reconstruction plate (medial) + 3.5 reconstruction plate (central)	Anatomical	No
8	72'	No	3.5 T plate (lateral) + compression screws (medial)	3 mm Lateral depression	No
9	107'	No	Cannulated screws (lateral) + reconstruction plate 3.5 (medial)	4 mm lateral depression	Injury of the superficial branch of the fibular nerve
10	111'	No	3.5 T plate (lateral) + 3.5 reconstruction plate /compression screw (medial)	1 mm lateral depression	No
11	125'	Yes (synthetic)	3.5 T plate/3.5 cannulated screws (lateral) + 3.5 reconstruction plate (medial)	Anatomical	No

the graft was harvested from the posterior iliac crest, while in the other the graft was synthetic, using the Nanogel injectable hydroxyapatite gel (Teknimed, L'Union, France) (►**Table 2**).

Six of 11 patients had their fractures classified as Schatzker III; two as Schatzker II, two as Schatzker V, and one as Schatzker IV. All patients had their fractures classified as Schatzker/Kfuri V P ML (►**Table 1**).

The results of the scores (Lysholm, AKSS, AKSS/Function, and Lysholm) and the range of motion after 6 months of procedure can be seen in ►**Table 3**. No postoperative complications were observed.

When analyzing sex, the female patients presented longer mean duration of surgery. The Wilcoxon signed-rank test did not indicate significant difference between sexes for the AKSS ($p = 0.295$), AKSS/Function ($p = 0.6831$), and Lysholm ($p = 0.0637$) scores.

Discussion

The prognosis of tibial plateau fractures is related to the quality of anatomical reduction of the joint surface and stable osteosynthesis to enable early knee mobilization.[12] The treatment of PTPFs is challenging, and several

 © 2022. Sociedade Brasileira de Ortopedia e Traumatologia. All rights reserved.

Table 3 Functional results

Patients	Lysholm*		AKKS**/AKKS Function***	ROM	Reduction/Alignment	Complications
	Pre-injury	6 months				
1	100	90	96/100	0–117	Anatomical/Maintained	No
2	100	94	97/100	0–123	Anatomical/Maintained	No
3	100	85	90/100	0–115	Anatomical/Maintained	No
4	100	95	88/100	0–100	Anatomical/Maintained	No
5	100	99	100/100	0–125	Anatomical/Maintained	No
6	100	95	100/100	0–125	Loss of 2 mm/ Maintained	No
7	100	99	95/100	0–125	Anatomical/Maintained	No
8	100	84	92/90	0–113	3 mm lateral depression/ Maintained	No
9	100	85	95/100	0–123	4 mm lateral depression/ Maintained	No
10	100	96	100/100	0–125	1 mm lateral depression/ Maintained	No
11	100	96	100/100	0–125	Anatomical/Maintained	No

Abbreviations: AKKS, American Knee Society Score; ROM, range of motion.
*$p = 0.0637$.
** $p = 0.295$.
***$p = 0.6831$.

approaches have been described for the treatment of these fractures, including the Carlson approach.[9]

Wang et al.[13] reported an approach that can be used for posterior shearing tibial plateau fractures, a procedure that is technically demanding and presents a risk for iatrogenic vascular injury due to the traction required to allow for visualization.[14] Lobenhoffer[15] described a transfibular approach for the treatment of posterolateral tibial plateau fractures. At the same time, Frosch et al.[16] proposed the posterolateral route with anterolateral and posterolateral arthrotomies, without osteotomy of the fibular neck, to treat combined fractures of the anterolateral and posterolateral zones of the tibial plateau. The partial ostectomy of the head of the fibula was described by Yu et al.[10] for the treatment of tibial plateau fractures, with preservation of the insertion of the lateral ligament complex of the knee. Good visibility is a positive aspect of the approach described by Yu; however, this access increases patient morbidity due to the addition of a fracture. He et al.[11] reported an extended posteromedial reversed L-shaped approach, without tenotomy of the gastrocnemius head, whereas Hu et al.[17] described a supra-fibular-head approach without fibular osteotomy for the treatment of PTPFs.

Despite the different proportions between the studies, it can be observed in the present manuscript that the leading mechanism of injury was motorcycle accidents (90.9%), and only one patient suffered a sports-related injury, contrasting with the study published by Albuquerque et al.,[1] who, in their epidemiological survey on tibial plateau fractures, found that, among the 239 patients analyzed, the main mechanism of injury was falls from heights, reported in 96 patients. In a retrospective study conducted by Xiang et al.,[3] the authors described the morphological characteristics of tibial plateau fractures in 242 patients and found that 36 of them presented posterolateral fractures. The mechanisms of injury included falling to the ground (9 patients), electric scooter injuries (8 patients), motor vehicle accidents (13), blow by a heavy object (2), and unknown causes (4).

In a study by Solomon et al.,[18] plates with fixed-angle screws were used, in addition to Norian bone graft substitutes (DePuy Synthes/Johnson & Johnson, USA) for filling bone defects, with satisfactory results in 100% of the patients, according to Rasmussen and Lysholm criteria.[19] Ehlinger et al.,[20] in a retrospective study comparing the use of 3.5-mm and 4.5-mm plates for tibial plateau fractures, recommended the use of 3.5-mm plates, corroborating with Hasan et al.,[21] in a biomechanical study, evidenced that there are no differences between 4.5-mm and 3.5-mm plates for tibial plateau fractures. In the present study, we used non-locking implants such as 3.5-mm fragment plates, 3.5-mm reconstruction plates, or 3.5-mm T plates and, in only one patient, a locking plate. Non-locking implants cost less and are available in the public health system, yielding a potentially reproducible technique.

Considering the complexity of PTPFs, we believe that the results obtained in the present study are encouraging, with 95.72% of them presenting excellent results as measured by the AKSS, with a mean AKSS/Function of 99.1 ± 3 (90–100), and Lysholm scores with a median of 95.0 ± 5.6 (84-99). These results are similar to those described by Solomon et al.,[19] who reported satisfactory results in 100% of the patients, according to the Lysholm criteria.

Fractures of the posterior tibial plateau can be addressed using different approaches; however, through this study, we were able to observe that the Carlson[9] approach can be used safely, with low morbidity and good functional outcomes. These good functional results are largely related to the anatomical reduction of the fracture.

In tibial plateau fractures, long-term functional levels, anatomical joint reduction, fixation stability, and early joint mobilization remain the objective of articular fracture

 © 2022. Sociedade Brasileira de Ortopedia e Traumatologia. All rights reserved.

osteosynthesis. Residual spacing between the tibial condyles, with consequent widening of the tibial articular surface, promotes abnormal contact relationships with the femoral condyles, favoring the emergence of posttraumatic arthritis. Similarly, poor alignment of the tibial condyles in reference to tibial diaphysis favors degenerative joint disease, by promoting deviation from the mechanical axis.[12]

Stiff knee is a frequent complication when initial postoperative joint mobilization care is not emphasized in rehabilitation protocols.[11,12,14] No pseudoarthrosis was observed. The Carlson approach[9] showed encouraging functional results, and low complication rates.

Another point that is important to emphasize is that since the Carlson approach[9] is used only for PTPFs, the patients in this study, classified according to the Schatzker-Kfuri system, were 100% posterior fracture pattern.

There were some limitations in this study that require consideration. One of them was the limited sample size, which did not allow us to demonstrate complete safety of the procedure. The absence of a prolonged follow-up comprises another limiting factor since it hampers the analysis of long-term complications. Detailed functional evaluation obtained during the medium-term follow-up confirms the safety of the procedure, and the absence of postoperative complications. Also, in functionally analyzing only fractures with a specific type of injury, we did not compare them with other forms of tibial plateau fractures (anterior), or even with different types of access for PTPFs. Finally, all surgical procedures were performed by only two surgeons, without randomization, a fact that hinders the evaluation of good functional results by others.

Prospective controlled studies with a larger sample size are necessary to obtain more robust conclusions. Therefore, the follow-up of the patients in this study will be maintained in order to evaluate results with a longer follow-up time, with the inclusion of further patients.

Conclusion

The Carlson approach for posterior fractures of the tibial plateau can be considered safe, presenting a low complication rate and satisfactory functional results.

Financial Support
There was no financial support from public, commercial, or non-profit sources.

Conflict of Interests
The authors have no conflict of interests to declare.

References

1 Albuquerque RP, Hara R, Prado J, Schiavo L, Giordano V, do Amaral NP. Epidemiological study on tibial plateau fractures at a level I trauma center. Acta Ortop Bras 2013;21(02):109–115
2 Yang G, Zhai Q, Zhu Y, Sun H, Putnis S, Luo C. The incidence of posterior tibial plateau fracture: an investigation of 525 fractures by using a CT-based classification system. Arch Orthop Trauma Surg 2013;133(07):929–934
3 Xiang G, Zhi-Jun P, Qiang Z, Hang L. Morphological characteristics of posterolateral articular fragments in tibial plateau fractures. Orthopedics 2013;36(10):e1256–e1261
4 Schatzker J, McBroom R, Bruce D. The tibial plateau fracture. The Toronto experience 1968–1975. Clin Orthop Relat Res 1979; (138):94–104
5 Mthethwa J, Chikate A. A review of the management of tibial plateau fractures. Musculoskelet Surg 2018;102(02):119–127
6 Brunner A, Horisberger M, Ulmar B, Hoffmann A, Babst R. Classification systems for tibial plateau fractures; does computed tomography scanning improve their reliability? Injury 2010;41 (02):173–178
7 Maripuri SN, Rao P, Manoj-Thomas A, Mohanty K. The classification systems for tibial plateau fractures: how reliable are they? Injury 2008;39(10):1216–1221
8 Luo CF, Sun H, Zhang B, Zeng BF. Three-column fixation for complex tibial plateau fractures. J Orthop Trauma 2010;24(11): 683–692
9 Carlson DA. Posterior bicondylar tibial plateau fractures. J Orthop Trauma 2005;19(02):73–78
10 Yu B, Han K, Zhan C, Zhang C, Ma H, Su J. Fibular head osteotomy: a new approach for the treatment of lateral or posterolateral tibial plateau fractures. Knee 2010;17(05):313–318
11 He X, Ye P, Hu Y, et al. A posterior inverted L-shaped approach for the treatment of posterior bicondylar tibial plateau fractures. Arch Orthop Trauma Surg 2013;133(01):23–28
12 Júnior MK, Fogagnolo F, Bitar RC, Freitas RL, Salim R, Jansen Paccola CA. Fraturas Do Planalto Tibial Tibial Plateau Fractures. Rev Bras Ortop 2015;44(06):468–474
13 Wang SQ, Gao YS, Wang JQ, Zhang CQ, Mei J, Rao ZT. Surgical approach for high-energy posterior tibial plateau fractures. Indian J Orthop 2011;45(02):125–131
14 Pires RES, Giordano V, Wajnsztejn A, et al. Complications and outcomes of the transfibular approach for posterolateral fractures of the tibial plateau. Injury 2016;47(10):2320–2325
15 Lobenhoffer P. Posterolateral transfibular approach to tibial plateau fractures. J Orthop Trauma 2011;25(03):e31, author reply e31
16 Frosch KH, Balcarek P, Walde T, Stürmer KM. A new posterolateral approach without fibula osteotomy for the treatment of tibial plateau fractures. J Orthop Trauma 2010;24(08):515–520
17 Hu SJ, Chang SM, Zhang YQ, Ma Z, Du SC, Zhang K. The anterolateral supra-fibular-head approach for plating posterolateral tibial plateau fractures: A novel surgical technique. Injury 2016;47(02):502–507
18 Solomon LB, Stevenson AW, Lee YC, Baird RPV, Howie DW. Posterolateral and anterolateral approaches to unicondylar posterolateral tibial plateau fractures: a comparative study. Injury 2013;44(11):1561–1568
19 Lysholm J, Gillquist J. Evaluation of knee ligament surgery results with special emphasis on use of a scoring scale. Am J Sports Med 1982;10(03):150–154
20 Ehlinger M, Adamczewski B, Rahmé M, Adam P, Bonnomet F. Comparison of the pre-shaped anatomical locking plate of 3.5 mm versus 4.5 mm for the treatment of tibial plateau fractures. Int Orthop 2015;39(12):2465–2471
21 Hasan S, Ayalon OB, Yoon RS, et al. A biomechanical comparison between locked 3.5-mm plates and 4.5-mm plates for the treatment of simple bicondylar tibial plateau fractures: is bigger necessarily better? J Orthop Traumatol 2014;15(02):123–129

 © 2022. Sociedade Brasileira de Ortopedia e Traumatologia. All rights reserved.