Article published online: 2022-06-06

Functional Shoulder Evaluation after Osteosynthesis of Greater Tuberosity Fracture: Is There any Influence of Glenohumeral Dislocation?*

Avaliação funcional do ombro após osteossíntese da fratura da tuberosidade maior: Há influência da luxação glenoumeral?

Guilherme Grisi Mouraria[1] Renato Mason Rodrigues da Cunha[1] Sérgio de Paula Coelho[1] Rafael Mulati Brigatto[2] Márcio Alves Cruz[1] Maurício Etchebehere[1]

[1] Shoulder and Elbow Group, Department of Orthopedics, Rheumatology and Traumatology, Faculdade de Ciências Médicas, Universidade Estadual de Campinas (UNICAMP), Campinas, SP, Brazil
[2] Hospital Estadual Sumaré, Universidade Estadual de Campinas (UNICAMP), Campinas, SP, Brazil
[3] Faculdade de Ciências Médicas, Universidade Estadual de Campinas (UNICAMP), Campinas, SP, Brazil

Address for correspondence Guilherme Grisi Mouraria, PhD, Orthopedics, Rheumatology and Traumatology, Faculdade de Ciências Médicas, Universidade Estadual de Campinas, Rua Tessália Vieira de Camargo, 126, Campinas, SP, Brazil (e-mail: mouraria@unicamp.br).

Rev Bras Ortop

Abstract

Objective To evaluate the postoperative functional and radiographic outcomes of the shoulder of patients submitted to transosseous suturing of a greater tuberosity fracture (GTF) through an anterolateral route and the influence of the glenohumeral dislocation on these outcomes.

Methods We conducted a retrospective study and functional assessment using the Constant-Murley score. The distance between the greater tuberosity and the joint surface of the proximal humerus (in true anteroposterior radiographs) after the union was calculated. We used the Fisher exact test for the categorical independent variables, and the Student *t* or Mann-Whitney test for the non-categorical variables.

Results In total, 26 patients met the inclusion criteria, and 38% of the sample presented an association between glenohumeral dislocation and GTF. The mean Constant-Murley score was of 82.5 + 8.02 points. The presence of an associated dislocation did not alter the functional outcome. The mean distance between the

Keywords
- humeral fractures
- shoulder dislocation
- suture anchors
- suture techniques

* *Study developed at the Department of Orthopedics, Rheumatology and Traumatology, Faculdade de Ciências Médicas, Universidade Estadual de Campinas (UNICAMP), Campinas, São Paulo–SP, Brazil.*

received
July 10, 2021
accepted
April 5, 2022

DOI https://doi.org/10.1055/s-0042-1749417.
ISSN 0102-3616.

© 2022. Sociedade Brasileira de Ortopedia e Traumatologia. All rights reserved.
This is an open access article published by Thieme under the terms of the Creative Commons Attribution-NonDerivative-NonCommercial-License, permitting copying and reproduction so long as the original work is given appropriate credit. Contents may not be used for commercial purposes, or adapted, remixed, transformed or built upon. (https://creativecommons.org/licenses/by-nc-nd/4.0/)

Thieme Revinter Publicações Ltda., Rua do Matoso 170, Rio de Janeiro, RJ, CEP 20270-135, Brazil

greater tuberosity of the humerus and the joint surface of the humeral head after the union was of 9 + 4.3 mm below the articular line of the humeral head. The dislocation led to a lower level of reduction, but this did not influence the Constant-Murley score.
Conclusion The cases of GTF submitted to surgical treatment with transosseous sutures had good functional outcomes. The presence of dislocation made the anatomical reduction of the greater tuberosity difficult. However, it did not influence the Constant-Murley score.

Resumo

Objetivo Avaliar os resultados funcional e radiográfico pós-operatórios do ombro, em pacientes submetidos a sutura transóssea de fratura da tuberosidade maior (FTM) por acesso anterolateral, e a influência da luxação glenoumeral nesses resultados.
Materiais e Métodos Realizou-se estudo retrospectivo e avaliação funcional (pela escala de Constant-Murley). Calculou-se a distância entre a tuberosidade maior e a superfície articular do úmero proximal (por meio de radiografia em incidência anteroposterior verdadeira) após a consolidação. Usou-se o teste Exato de Fisher para as variáveis independentes categóricas, e os testes *t*de Student ou de Mann-Whitney para as não categóricas.
Resultados Ao todo, 26 pacientes preencheram os critérios de inclusão. A associação de luxação glenoumeral com FTM foi observada em 38% da amostra. A média da pontuação na escala de Constant-Murley foi de 82,5 + 8,02. A presença de luxação associada não alterou o resultado funcional. A distância média da consolidação da tuberosidade maior do úmero em relação à superfície articular da cabeça umeral foi de 9 + 4,3 mm abaixo da linha articular da cabeça umeral. Pacientes com luxação associada evoluíram com redução menor, mas isso não influenciou na pontuação na escala de Constant-Murley.
Conclusão As FTMs submetidas ao tratamento cirúrgico com sutura transóssea evoluíram com bom resultado funcional. A presença de luxação dificultou a redução anatômica da tuberosidade maior. Entretanto, isso não influenciou na pontuação na escala de Constant-Murley.

Palavras-chave
- fraturas do úmero
- luxação do ombro
- âncoras de sutura
- técnicas de sutura

Introduction

Greater tuberosity fractures (GTFs) account for 20% of fractures of the proximal humerus.[1] Although their prevalence is low, GTFs are functionally relevant because they affect the attachment site for the supraspinatus and infraspinatus muscles, playing a role in shoulder joint flexion, abduction, and external rotation. Thus, the anatomical reduction of the greater tuberosity is fundamental for a good functional outcome for the shoulder.[2] Approximately 10% to 30% of dislocations are concurrent with GTF[3] and a potential Hill-Sachs lesion.[4] Reduction of the glenohumeral dislocation can lead to concomitant reduction of the greater tuberosity. One study[5] showed that only 4% of patients with GTF and anterior dislocation of the humerus required surgical treatment to correct the fracture deviation.

The greater tuberosity requires surgical treatment if the fracture deviation is $\geq$ 5 mm.[6] Surgery is more indicated for young patients or those performing activities with arm elevation above the head.[7] The surgical treatment aims at an anatomical reduction between the greater tuberosity and the humeral head in a portion approximately 9 mm distal to its most proximal aspect.[7] An improper reduction may cause secondary impingement syndrome and/or cuff failure (high tuberosity), or tendon rupture due to excessive stress (low tuberosity).[6]

The deltopectoral and anterolateral approaches are the most used to treat proximal humerus fractures.[8] The anterolateral approach is lateral to the proximal humerus, and it provides better exposure of the greater tuberosity.[9]

Fracture morphology may influence the osteosynthesis technique. The treatment of a large-fragment GTF (split type) uses a plate and a screw compression system. A tension band or transosseous suture is an option for the fixation of comminuted and small fragments.[7]

Few studies have evaluated the surgical treatment of GTFs and the influence of a glenohumeral dislocation on the postoperative functional outcome of the shoulder.

Our primary objective was to evaluate shoulder function and the final position of GTF union after a transosseous suture by the anterolateral approach. A secondary goal was to assess whether an associated glenohumeral dislocation could influence these outcomes.

 © 2022. Sociedade Brasileira de Ortopedia e Traumatologia. All rights reserved.

Materials and Methods

We conducted a retrospective study analyzing medical records from patients undergoing osteosynthesis of the greater tuberosity with bone sutures from January 2010 to August 2019.

The inclusion criteria were the following: patients over 18 years old with GTF (deviation greater than 5 mm) surgically treated with transosseous suture via the anterolateral approach, and a minimum follow-up of one year postoperatively.

The exclusion criteria were the following: patients with proximal humerus fractures classified as Neer III and IV (such as, lesser tuberosity fractures and surgical or anatomical neck fractures associated with a GTF)[10] or previous shoulder injuries (cuff or neurological lesions).

The patients were placed in the beach chair position. The anterolateral[11] (Mackenzie) approach was used in every case. We performed an incision of approximately 5 cm inferiorly to the anterior extremity of the acromion, running along the lateral region of the arm. Then, we divided the deltoid muscle, in the same direction as its fibers, between the anterior and middle portions. We did not isolate the axillary nerve if a 5-cm incision was enough for osteosynthesis. However, if wider exposure were required, the nerve was dissected and protected with a Penrose drain. Next, we perforated the greater tuberosity bone (in cases with a larger bone fragment) or sutured the supraspinatus or infraspinatus tendons. Then, we perforated the humeral diaphysis and performed the transosseous suture with non-absorbable #5 Ethibond (Ethicon, Inc., Bridgewater, NJ, United States) suture.

We reviewed the demographic and trauma data from the medical records. The postoperative functional assessment used the Constant-Murley Shoulder Outcome Score.[12] The preoperative evaluation of the axillary nerve used the corresponding dermatome sensitivity test. Postoperatively, we investigated dermatome changes and the presence of inferior humeral subluxation on the clinical or radiographic examinations.

The preoperative and postoperative radiographic analyses were based on the true anteroposterior view, lateral view of the scapula, and axillary view. The final position of fracture healing corresponded to the distance (in millimeters) from the apex of the greater tuberosity to the joint surface of the proximal humerus (true anteroposterior view) (►**Figure 1**). Consolidation was complete when there was no fracture line in at least two views. The Radiographs and measurements were performed using the Synapse (Fujifilm Healthcare, Lexington, MA, United States) digital radiology software.

The inferential analysis used the Chi-squared or Fisher exact tests for the independent categorical variables (comorbidities, gender, fracture side). The numerical variables were analyzed after normality evaluation by the Kolmogorov-Smirnov test using the Student *t* (age) or the Mann-Whitney (distance to the final position of fracture union) tests. Data analysis was performed using the Statistical Package for the Social Sciences (IBM SPSS Statistics for Windows, IBM Corp., Armonk, NY, United States) software, version 27.0, assuming a significance level of 5%.

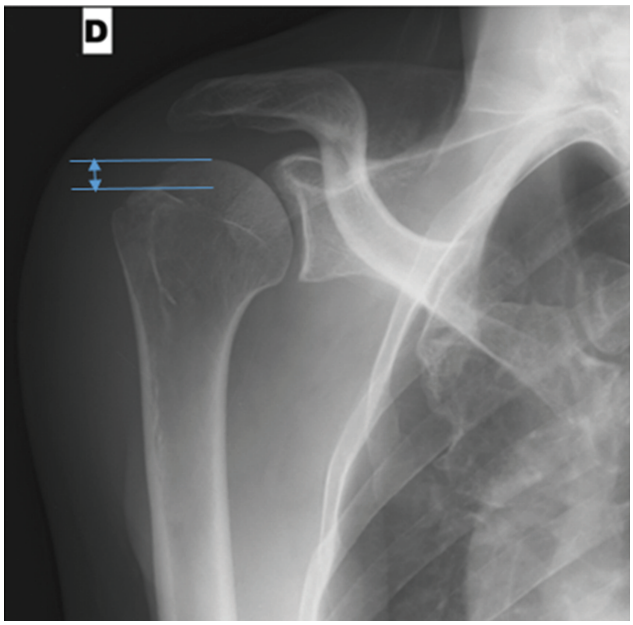

Fig. 1 Distance (mm) between the greater tuberosity fracture and the humeral joint surface.

The institutional ethics committee approved the study under CAAE number 73273317.8.0000.5404.

Results

The present study evaluated 59 patients, and 33 subjects were excluded for not meeting the inclusion criteria; therefore, the final sample consisted of 26 patients. The main reasons for exclusion were the presence of a fracture line extending to the lesser tuberosity and loss to follow-up. The mean follow-up time was of $15 + 13$ months.

The mean age of the study participants was of $39.72 + 16.27$ years. Most subjects were male, and the right side was most affected (73%). The main comorbidities were diabetes mellitus, drug addiction, alcoholism, smoking, epilepsy, and hypothyroidism. Among them, epilepsy was the most prevalent (11%). ►**Table 1** summarizes the demographic data.

In total, 10 patients (38%) presented a glenohumeral dislocation associated with GTF. Men presented more dislocations than women ($p = 0.05$).

The average Constant-Murley score was good ($82.5 + 8.02$ points). The presence of an associated dislocation did not alter the functional outcome (►**Table 2**).

Radiologically, the average time until consolidation was of $2.2 + 0.9$ months. The final position of the greater tuberosity apex was $9 + 4.3$ mm below the joint surface of the humeral head. There were no cases of postoperative reduction above the level of the humeral head. The final position of the GTF did not influence the functional assessment ($p = 0.32$).

Patients with dislocations presented lower levels of greater tuberosity reduction (hyperreduction) compared to those with no dislocation ($p = 0.01$). However, the presence of

 © 2022. Sociedade Brasileira de Ortopedia e Traumatologia. All rights reserved.

Table 1 Demographics and trauma characteristics according to the associated dislocation

		Dislocation		
	Total (n)	No – n (%)	Yes – n (%)	*p*-value
Gender				
Male	20	10 (50%)	10 (50%)	0.05[a]
Female	06	6 (100%)	0 (0.0%)	
Age (years)				
Mean ± standard deviation		41.1 ± 15.3	42.5 ± 12.4	0.73[b]
Comorbidities				
Yes	11	6 (54.5%)	5 (45.5%)	0.68[a]
No	15	10 (66.6%)	5 (33.3%)	
Affected side				
Dominant	19	14 (73.7%)	5 (26.3.%)	0.69[a]
Non-dominant	07	2 (28.6%)	5 (71.4%)	

Notes: [a]Fisher exact test; [b]Student *t*-test.

Table 2 Difference between Constant-Murley score and the radiographic parameter according to the history of dislocation

	Dislocation		
	No	Yes	*p*-value
Constant-Murley score: median (minimum-maximum)	83.0 (72-95)	84.0 (78-92)	0.63[c]
Distance (mm) from the apex of the great tuberosity to the joint surface: median (minimum-maximum)	6.92 (2-13)	9.98 (7-16)	0.01[c]

Note: [c]Mann-Whitney test.

dislocation did not influence the Constant-Murley score (►**Table 2**).

Two patients presented greater tuberosity resorption. There were no cases of postoperative infection or axillary nerve injury. A single case required dissection and protection of the axillary nerve because fracture reduction needed an incision larger than 5 cm.

Discussion

In a study with 610 proximal humerus fractures to perform an epidemiological comparison of GTFs (group I) with other types of proximal humerus fractures (group II), Kim et al.[13] concluded that younger patients (with mean age of 42.8 years) and men (67.8%) were predominant in group I, which is consistent with our findings. In contrast, other types of proximal humerus fracture predominated in older subjects and women.[13] This same study[13] reported a glenohumeral dislocation rate of 6.9% in group I and of 3.4% in group II. Robinson et al.[14] analyzed 2,208 traumatic anterior dislocations and observed a 34% incidence of associated GTF, which also consistent with our rate of 38%.

We did not observe a relationship between comorbidities, age, fracture side, and the prevalence of GTF-associated dislocation (►**Table 1**). The prevalence of comorbidities is higher in older patients. In addition, they tend to present fractures involving other anatomical structures (such as the surgical neck, the lesser tuberosity) than isolated GTFs.[13,15]

The average Constant-Murley score was good, and its lowest value was of 72 points. Rouleau et al.[16] observed a good or excellent outcome in 80% to 100% of their patients. Flatow et al.[17] found good functional outcomes and fracture healing in their case series.

We did not observe axillary nerve-related complications. Theoretically, the axillary nerve is more at risk in the anterolateral approach (incisions larger than 5 cm) compared to the deltopectoral approach. However, some authors[18,19] have shown that the anterolateral approach is safe for the axillary nerve, resulting in good functional outcomes. Similarly, a systematic review[20] of 24 articles involving 831 patients submitted to the anterolateral approach found a low incidence of iatrogenic axillary nerve injury and a good functional outcome (Constant-Murley score of 75.2) after osteosynthesis of a proximal humerus fracture.

The presence of a dislocation influenced the quality of the postoperative reduction ($p = 0.01$) in the present study (►**Table 2**). In patients with a dislocation, the median distance from the apex of the greater tuberosity to the joint surface was greater (9.98 mm) than in subjects without dislocation (6.92 mm). One hypothesis for this difference is the presence of a Hill-Sachs lesion, which could alter the

 © 2022. Sociedade Brasileira de Ortopedia e Traumatologia. All rights reserved.

anatomical parameters and make it difficult to reduce the greater tuberosity.

Bhatia et al.[21] studied GTFs with displaced and comminuted fragments treated with open reduction and anchor fixation. These authors[21] observed fragment consolidation below the joint level of the humeral head in most patients. The study did not specifically assess fracture comminution. However, we believe that the presence of a Hill-Sachs lesion acts in the same way, as it changes the anatomical parameters and makes fracture reduction difficult.

Regarding our results, the presence of glenohumeral dislocation did not influence the functional assessment of the shoulder through the total Constant-Murley score. Several aspects of the score (such as lateral rotation and strength) were not statistically different in patients with or without GTF-associated dislocation. Moreover, the final position of the greater tuberosity after surgery did not influence the Constant-Murley score. We hypothesized that tuberosity reduction below the humeral joint surface resulted in no secondary subacromial impingement or functional deterioration. Hébert-Davies et al.[22] observed a mean Constant-Murley score of 83 points in a sample of patients with GTF, which is very similar to our findings (84 points).

The present study has some weaknesses. Its main limitation is the retrospective design. In addition, the reduced number of patients and the 1-year follow-up may decrease the rate of identification of complications. However, the lower prevalence of GTFs, especially those treated surgically, favors the performance of cross-sectional or retrospective studies to create subsidies for further prospective investigations.

Conclusion

The cases of GTF submitted to surgical treatment with transosseous sutures through the anterolateral approach had good functional outcomes.

A glenohumeral dislocation made the anatomical reduction of the greater tuberosity difficult. However, it did not influence the functional outcomes of the patients' shoulders.

Financial Support
The authors declare that the present study did not receive financial support from public, commercial, or non-profit sources.

Conflict of Interests
The authors have no conflict of interests to declare.

References

1 Court-Brown CM, Garg A, McQueen MM. The epidemiology of proximal humeral fractures. Acta Orthop Scand 2001;72(04): 365–371
2 Gruson KI, Ruchelsman DE, Tejwani NC. Isolated tuberosity fractures of the proximal humeral: current concepts. Injury 2008;39(03):284–298
3 Kristiansen B, Barfod G, Bredesen J, et al. Epidemiology of proximal humeral fractures. Acta Orthop Scand 1987;58(01):75–77
4 Provencher MT, Frank RM, Leclere LE, et al. The Hill-Sachs lesion: diagnosis, classification, and management. J Am Acad Orthop Surg 2012;20(04):242–252
5 Dussing F, Plachel F, Grossauer T, et al. Anterior shoulder dislocation and concomitant fracture of the greater tuberosity: Clinical and radiological results. Obere Extrem 2018;13(03):211–217
6 Nyffeler RW, Seidel A, Werlen S, Bergmann M. Radiological and biomechanical assessment of displaced greater tuberosity fractures. Int Orthop 2019;43(06):1479–1486
7 DeBottis D, Anavian J, Green A. Surgical management of isolated greater tuberosity fractures of the proximal humerus. Orthop Clin North Am 2014;45(02):207–218
8 Mouraria GG, de Souza PAM, Saheb RLC, Cruz MA, Moratelli L, Etchebehere M. Does surgeon specialization change the proximal humeral osteo-synthesis approach? Acta Ortop Bras 2019;27 (02):113–115
9 Gardner MJ, Boraiah S, Helfet DL, Lorich DG. The anterolateral acromial approach for fractures of the proximal humerus. J Orthop Trauma 2008;22(02):132–137
10 Neer CS II. Four-segment classification of proximal humeral fractures: purpose and reliable use. J Shoulder Elbow Surg 2002;11(04):389–400
11 Mackenzie D. The antero-superior exposure for total shoulder replacement. Orthop Traumatol 1993;2(02):71–77
12 Barreto RP, Barbosa ML, Balbinotti MA, Mothes FC, da Rosa LH, Silva MF. The Brazilian version of the Constant-Murley Score (CMS-BR): convergent and construct validity, internal consistency, and unidimensionality. Rev Bras Ortop 2016;51(05): 515–520
13 Kim E, Shin HK, Kim CH. Characteristics of an isolated greater tuberosity fracture of the humerus. J Orthop Sci 2005;10(05): 441–444
14 Robinson CM, Shur N, Sharpe T, Ray A, Murray IR. Injuries associated with traumatic anterior glenohumeral dislocations. J Bone Joint Surg Am 2012;94(01):18–26
15 Chun JM, Groh GI, Rockwood CA Jr. Two-part fractures of the proximal humerus. J Shoulder Elbow Surg 1994;3(05):273–287
16 Rouleau DM, Mutch J, Laflamme GY. Surgical Treatment of Displaced Greater Tuberosity Fractures of the Humerus. J Am Acad Orthop Surg 2016;24(01):46–56
17 Flatow EL, Cuomo F, Maday MG, Miller SR, McIlveen SJ, Bigliani LU. Open reduction and internal fixation of two-part displaced fractures of the greater tuberosity of the proximal part of the humerus. J Bone Joint Surg Am 1991;73(08):1213–1218
18 Xie L, Zhang Y, Chen C, Zheng W, Chen H, Cai L. Deltoid-split approach versus deltopectoral approach for proximal humerus fractures: A systematic review and meta-analysis. Orthop Traumatol Surg Res 2019;105(02):307–316
19 Ikemoto RY, Nascimento LGP, Bueno RS, Almeida LHO, Strose E, Murachovsky J. Axillary nerve position in the anterosuperior approach of the shoulder: a cadaveric study. Acta Ortop Bras 2015;23(01):26–28
20 Mouraria GG, Zoppi A, Kikuta FK, Moratelli L, Cruz MA, Etchebehere M. Anterolateral approaches for proximal humeral osteosynthesis: a systematic review. Acta Ortop Bras 2019;27(03): 178–182
21 Bhatia DN, van Rooyen KS, du Toit DF, de Beer JF. Surgical treatment of comminuted, displaced fractures of the greater tuberosity of the proximal humerus: a new technique of double-row suture-anchor fixation and long-term results. Injury 2006;37(10):946–952
22 Hébert-Davies J, Mutch J, Rouleau D, Laflamme GY. Delayed migration of greater tuberosity fractures associated with anterior shoulder dislocation. J Orthop Trauma 2015;29(10):e396–e400

 © 2022. Sociedade Brasileira de Ortopedia e Traumatologia. All rights reserved.