Article published online: 2022-06-10

Anatomy of the Medial Meniscotibial Ligament of the Knee: A Systematic Review*

Anatomia do ligamento meniscotibial medial do joelho: Uma revisão sistemática

Jonatas Brito de Alencar Neto[1,2] Amanda Progênio dos Santos[1] Márcio Bezerra Gadelha Lopes[1,2] Lana Lacerda de Lima[3,4] Renata Clazzer[3] Diego Ariel de Lima[3,4]

[1] Division of Orthopedics and Traumatology, Instituto Doutor José Frota, Fortaleza, CE, Brazil
[2] Knee Surgery Group, Clínica Articular, Fortaleza, CE, Brazil
[3] Division of Orthopedics and Traumatology, Hospital Tarcísio Maia, Mossoró, RN, Brazil
[4] Department of Health Sciences, Universidade Federal Rural do Semi-Árido - UFERSA, Mossoró, RN, Brazil

Address for correspondence Diego Ariel de Lima, MD, PhD, Universidade Federal Rural do Semi-Árido, Rua Francisco Mota, 572, Presidente Costa e Silva, Mossoró, RN, Brazil, 59625-900 (e-mail: arieldelima.diego@gmail.com).Instagram: @arieldelima.diego

Rev Bras Ortop

Abstract

Objectives To perform a systematic review of the literature on the anatomy of the medial meniscotibial ligaments (MTLs), and to present the most accepted findings, as well as the evolution of the anatomical knowledge on this structure.

Materials and Methods An electronic search was conducted in the MEDLINE/PubMed, Google Scholar, EMBASE and Cochrane library databases with no date restrictions. The following index terms were used in the search: *anatomy* AND *meniscotibial* AND *ligament* AND *medial*. The review was performed according to the Preferred Reporting Items for Systematic Reviews and Meta-Analyses (PRISMA) statement. We included anatomical studies of the knee were included, such as cadaver dissections, histological and/or biological investigations, and/or imaging of the medial MTL anatomy.

Results Eight articles that met the inclusion criteria were selected. The first article was published in 1984 and the last, in 2020. The total sample in the 8 articles was of 96 patients. Most studies are purely descriptive in terms of the macroscopic morphological and microscopic histological findings. Two studies evaluated the biomechanical aspects of the MTL, and one, the anatomical correlation with the magnetic resonance imaging examination.

Conclusion The main function of the medial MTL, a ligament that originates in the tibia and is inserted in the lower meniscus, is to stabilize and maintain the meniscus in its position on the tibial plateau. However, there is a limited amount of information regarding medial MTLs, primarily in terms of anatomy, especially vascularization and innervation.

Keywords
- ligaments
- meniscus
- tibia
- knee
- anatomy

* *Worked developed at Instituto Doutor José Frota, Fortaleza, Ceará, Brazil.*

received
December 5, 2021
accepted
March 28, 2022

DOI https://doi.org/10.1055/s-0042-1749198.
ISSN 0102-3616.

© 2022. Sociedade Brasileira de Ortopedia e Traumatologia. All rights reserved.
This is an open access article published by Thieme under the terms of the Creative Commons Attribution-NonDerivative-NonCommercial-License, permitting copying and reproduction so long as the original work is given appropriate credit. Contents may not be used for commercial purposes, or adapted, remixed, transformed or built upon. (https://creativecommons.org/licenses/by-nc-nd/4.0/)

Thieme Revinter Publicações Ltda., Rua do Matoso 170, Rio de Janeiro, RJ, CEP 20270-135, Brazil

Resumo

Objetivos Fazer uma revisão sistemática da literatura sobre a anatomia dos ligamentos meniscotibiais (LMTs) mediais, e apresentar os achados mais aceitos e a evolução das informações anatômicas sobre essa estrutura.

Materiais e Métodos A busca eletrônica foi realizada nos bancos de dados MEDLINE/PubMed, Google Scholar, EMBASE e Cochrane, sem restrições de data. Os seguintes termos de indexação foram utilizados: *anatomy AND meniscotibial AND ligament AND medial*. A revisão seguiu as recomendações da declaração de Principais Itens para Relatar Revisões Sistemáticas e Metanálises (Preferred Reporting Items for Systematic Reviews and Meta-Analyses, PRISMA, em inglês). Foram incluídos estudos anatômicos do joelho, como dissecções de cadáveres, investigações histológicas e/ou biológicas, e/ou imagens da anatomia do LMT medial.

Resultados Oito artigos atenderam aos critérios de inclusão e foram selecionados. O primeiro foi publicado em 1984, e o último, em 2020. A amostra total nos 8 artigos foi de 96 pacientes. A maioria dos estudos é puramente descritiva em relação aos achados morfológicos macroscópicos e histológicos microscópicos. Dois estudos avaliaram os aspectos biomecânicos do LMT, e um analisou a correlação anatômica com o exame de ressonância magnética.

Conclusão A principal função do LMT medial, ligamento que se origina na tíbia e se insere no menisco inferior, é estabilizar e manter a posição do menisco no platô tibial. No entanto, há poucas informações sobre LMTs mediais, principalmente em termos de anatomia, vascularização e inervação.

Palavras-chave

- ligamentos
- menisco
- tíbia
- joelho
- anatomia

Introduction

The meniscotibial ligaments (MTLs) were examined by anatomical dissection in 1914[1] and re-evaluated arthrographically in 1984.[2] The MTLs (►**Fig. 1**), a fibrous band that originates in the tibia and is inserted in the lower portion of the menisci, stabilize and maintain the meniscus in its position on the tibial plateau.[3,4]

The medial MTLs show greater pullout strength compared with their lateral counterparts, and their anterior portion is more resistant than the posterior.[5] The anteromedial MTLs exhibit a tensile strength of 396.6 N, supporting a maximum elongation of 7.7 mm.[6]

In 2015, Peltier et al.[3] identified the importance of MTLs to knee stability, especially posteromedial rotational stability. Injuries to the MTL are a common cause of knee pain in middle-aged athletes.[7] In addition, MTLs display synergistic action with the anterior cruciate ligament (ACL), mainly regarding rotational stability, anterior translation, and internal and external rotations, which is clinically evidenced by rotational testing during the physical examination.[3]

Thus, the present study aimed to perform a systematic review of the literature on the anatomy of the medial MTLs, displaying the most accepted findings, as well as the evolution of anatomical knowledge on this structure.

Materials and Methods

In August 2021, an electronic search was conducted independently by 2 authors (APS and JBAN) on the MEDLINE/PubMed, Google Scholar, EMBASE and Cochrane databases, with no date restrictions. The following index terms were used: *anatomy* AND *meniscotibial* AND *ligament* AND *medial*.

The review was performed according to the Preferred Reporting Items for Systematic Reviews and Meta-Analyses (PRISMA) statement. Titles and abstracts were used to select articles that met the research objective. Only original articles that described anatomical aspects of the medial MTL ligament in the titles or abstracts were selected.

The selected articles were read in their entirety and their references were manually searched to find additional relevant studies. Discrepancies in data extraction were resolved through discussion between the authors.

The inclusion criteria were anatomical studies of the entire knee, such as cadaver dissections, histological and/or biological investigations, and/or anatomy imaging. Studies containing only biochemical and/or intraoperative data, as well as review articles without original data, were excluded. Articles found more than once on different platforms were excluded.

The following data were collected from the selected studies: authors, date of publication, type of study, sample size, presence of the ligament, and measures of length, width, and thickness. The anatomical findings were submitted to a descriptive analysis.

Results

A total of 350 articles were initially selected. Following the application of the inclusion and exclusion criteria, eight

 © 2022. Sociedade Brasileira de Ortopedia e Traumatologia. All rights reserved.

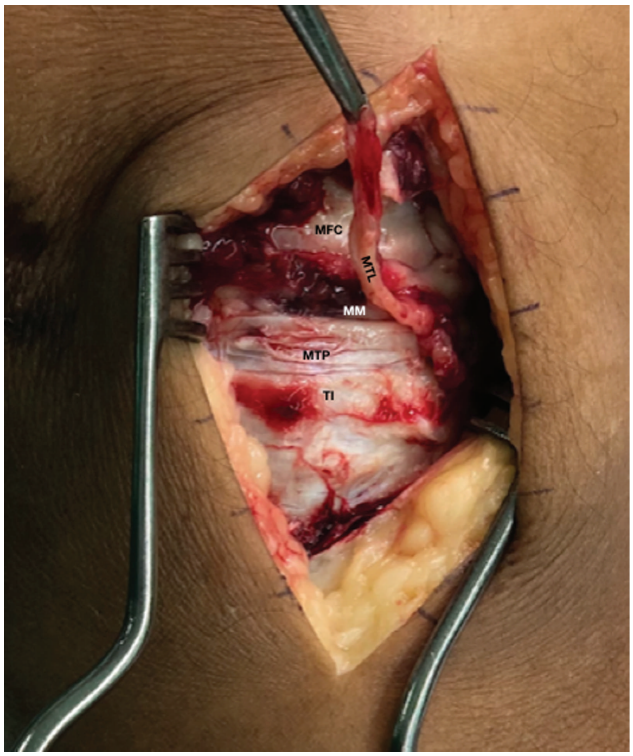

Fig. 1 Medial meniscotibial ligament (MTL). Abbreviations: MFC, medial femoral condyle; MTL, meniscotibial ligament; MTP, medial tibial plateau; MM, medial meniscus; TI, tibial insertion of the medial MTL.

articles that described the anatomical aspects of the MTLs (►**Table 1**)[2–4,8–12] were selected for full reading (►**Fig. 2**).

Year of Publication

Due to the scarcity of articles, there is a large time lag between the publication of the first article, in 1984,[2] and the next, only in 2000.[6] In the ensuing years, MTLs began to be described, mostly as part of larger studies on the medial region of the knee. Only two articles[11,12] describing the anatomy of medial MTLs have been published in the last five years.

Type of Study

With respect to the evaluation of MTL anatomy, the studies analyzed exhibited significantly different objectives, with some focusing only on anatomy,[2,4,8,11] others comparing the findings of imaging examinations – magnetic resonance imaging (MRI) – with anatomical dissections,[9] and others correlating with knee biomechanics.[3,10]

Nevertheless, they all conducted descriptive analysis of the findings, but without explaining the presence or absence of anatomical variations in the sample or performing statistical analyses to correlate the findings described.

Sample of Studies

In the 8 studies analyzed, the total sample was of 96 patients. One study evaluated 24 ligaments;[10] 2 assessed 14;[11,12] 3 investigated 10;[2,3,8] 1 analyzed 6;[9] and 1 evaluated 8.[4]

Table 1 Characteristics of selected articles

Authors	Year	N	Type of study	Finding
E-khoury et al.[2]	1984	10	Anatomical dissection in cadavers and histological study	Qualitative description of the medial meniscotibial ligament
De Maeseneer et al.[9]	2000	6	Comparative study of magnetic resonance imaging scans and cadaver dissection	Qualitative description of the medial meniscotibial ligament
La Prade et al.[4]	2007	8	Cadaver dissection evaluating medial knee anatomy	Qualitative description of the medial meniscotibial ligament
Griffith et al.[10]	2009	24	Anatomical dissection in cadavers evaluating the individual biomechanical correlation of the medial structures of the knee	Qualitative description of the medial meniscotibial ligament
Liu et al.[8]	2010	10	Cadaver dissection evaluating medial knee anatomy	Qualitative description of the medial meniscotibial ligament and morphological characteristics
Peltier et al.[3]	2015	10	Cadaver dissection evaluating the action of the medial meniscotibial ligament on posteromedial rotational instability of the knee	Biomechanical description before and after medial meniscotibial ligament injury
DePhillipo et al.[11]	2019	14	Dissection in cadavers evaluating anatomical and histological aspects between the posterior portion of the medial meniscus and the medial meniscotibial ligament	Morphological description of the meniscotibial ligament, the meniscocapsular insertion of the posterior portion of the medial meniscus, and its histological peculiarities
Cavaignac et al.[12]	2021	14	Dissection in cadavers evaluating the relationship of the distal semimembranosus tendon and the medial meniscus	Qualitative description of the medial meniscotibial ligament and morphological and histological characteristics of its insertion in the medial meniscus and distal semimembranosus tendon

 © 2022. Sociedade Brasileira de Ortopedia e Traumatologia. All rights reserved.

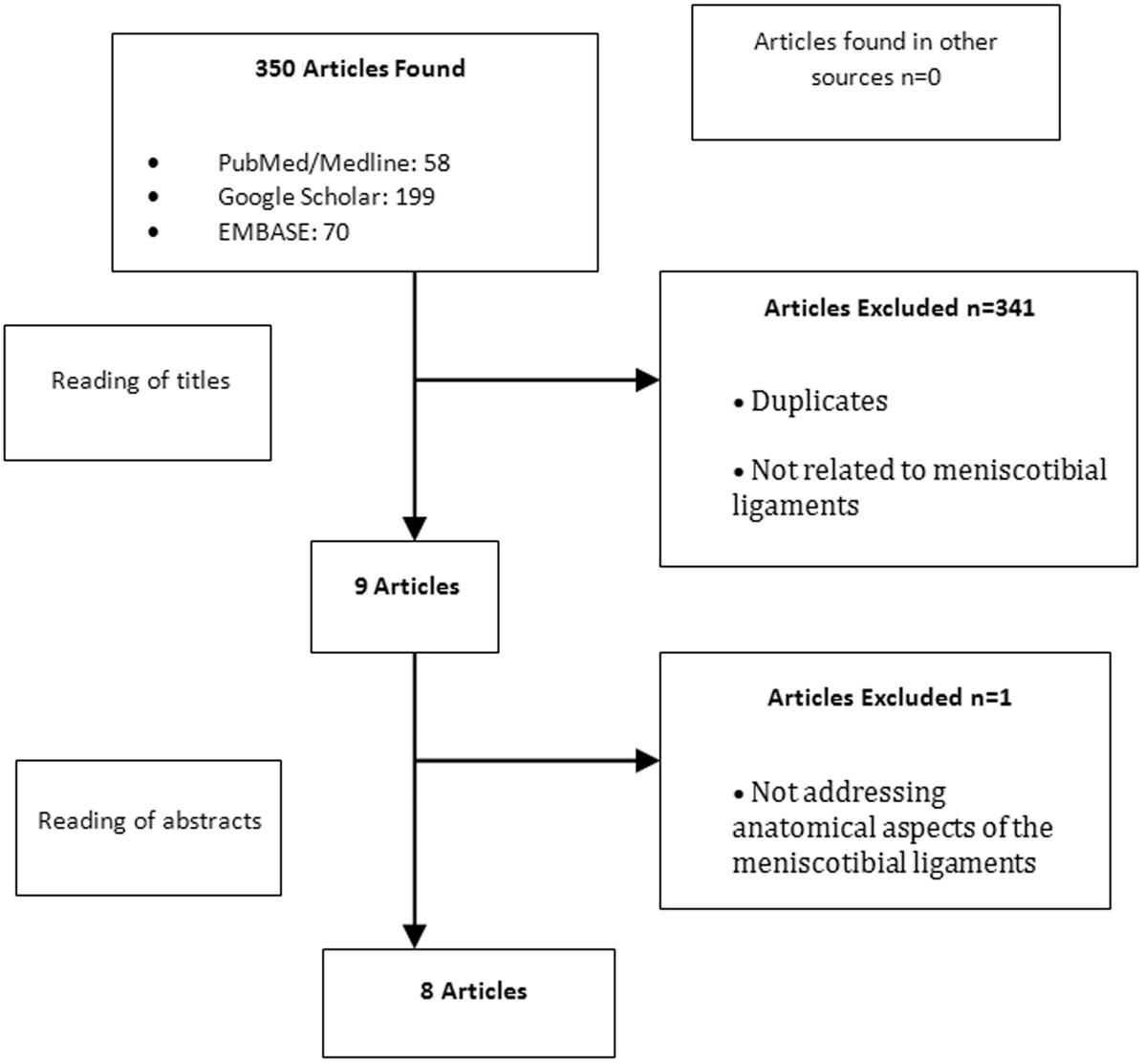

Fig. 2 Flowchart of the selection of articles.

Study Findings

Two studies only describe the macroscopic anatomical findings (qualitative description of the medial MTL and morphological characteristics).[4,8] In addition to the macroscopic anatomy, three studies[2,11,12] performed histological analyses of the samples. One study[9] compared the MRI findings with post examination anatomical dissection in the same samples. Finally, two studies[3,10] assessed biomechanical aspects related to the medial structures of the knees, anatomically describing the structures involved.

Discussion

The number of articles on the research platforms regarding the anatomical aspects of MTLs is limited – only 8 were found over the past 40 years –, with most containing superficial descriptions of their characteristics.

E-khoury et al.[2] performed anatomical dissections of ten cadaver knees and observed that the MTL is almost always identifiable as a separate structure, but histologically its fibers are mixed with those of the medial collateral ligament.

When La Prade et al.[4] studied the medial anatomy of the knee through anatomical dissection of eight cadaver knees, among other findings, they described the MTLs as structures that were consistently shorter and thicker than the meniscofemoral ligaments, fixed only distally to the edge of the articular cartilage of the medial tibial plateau. Liu et al.[8] studied ten samples, focusing on the medial collateral ligament, and observed other structures during anatomical dissection, with the medial MTL described as three times shorter than the medial meniscofemoral ligament.

Some studies sought to correlate the anatomy found in dissections with the findings of imaging studies. De Maeseneer et al.[9] correlated MRI scans with anatomical dissection performed on six cadaveric knees. With respect to the MTLs, the authors[9] reported that the shorter meniscotibial extension originated from the inferior outer margin of the meniscus, fixing itself to the tibial cortex, inferiorly to the joint

 © 2022. Sociedade Brasileira de Ortopedia e Traumatologia. All rights reserved.

space, whereas in the MRI they were described only as low-signal band-like structures located deep in the superficial portion of the medial collateral ligament.

Griffith et al.[10] studied 24 knees and evaluated the primary and secondary medial structures involved in biomechanical joint stability at different degrees of flexion.[10] They identified the presence of medial MTLs related to stability in external and internal rotations in all the specimens, but without detailed descriptions regarding ligament morphology.[10]

Corroborating these findings, Peltier et al.[3] demonstrated the presence of MTLs and their role in the rotational stability of the knee in their study with ten samples, and they observed an increase in internal and external rotations when the MTL injury is associated with ACL injury compared with isolated ACL injuries.

More recently, DePhilipo et al.[11] performed a study with 14 knees and observed the MTLs in all specimens running at an oblique angle from the posterior tibia until their insertion proximal to the posterior and inferior border of the medial meniscus, with an average length of 14.0 mm. A histological analysis revealed that the MTLs were formed by type-I collagen fibers arranged linearly. The authors[11] also mention that the insertion of the MTL in the posterior horn of the meniscus and meniscus-capsular insertion are common, and that no histological differences were found between these two structures.

However, in their study of 14 knees, Cavaignac et al.[12] described the MTLs as tissue connecting the posteroinferior edge of the posterior horn of the medial meniscus to the tibial plateau, finding totally separate insertions for the two structures, an attachment in the posteroinferior edge of the meniscus (for the MTL) and another on the posterosuperior edge (meniscus-capsular).

Finally, it is noted that there is a limited amount of information regarding the medial MTLs, mainly with respect to anatomy (especially vascularization and innervation), with few studies referring to this structure and others providing only brief descriptions. As such, more studies are needed, with an emphasis on methodological quality and further refinement in the description of findings, to provide enhanced knowledge of MTL anatomy, which will in turn contribute to the understanding of knee pathologies and their treatment.

The limitations of the present investigation were the small number of articles, the lack of standardized anatomical findings, and the wide range of methodologies used in the articles found, which precluded comparison across studies.

Conclusion

The medial MTL originates in the tibia and is inserted in the inferior portion of the meniscus. Its main function is to stabilize and maintain the meniscus in its position on the tibial plateau. However, there is a limited amount of information regarding medial MTLs, mainly regarding anatomy, especially vascularization and innervation.

Financial Support
The authors declare that they have not received financial support from public, private, or non-profit sources for the conduction of the present study.

Conflict of Interests
The authors have no conflict of interests to declare.

References

1 Jeong JJ, Oh SB, Ji JH, Park SJ, Ko MS. Immediate arthroscopy following ORIF for tibial plateau fractures provide early diagnosis and treatment of the combined intra-articular pathologies. Knee Surg Sports Traumatol Arthrosc 2019;27(10): 3327–3333
2 El-Khoury GY, Usta HY, Berger RA. Meniscotibial (coronary) ligament tears. Skeletal Radiol 1984;11(03):191–196
3 Peltier A, Lording T, Maubisson L, Ballis R, Neyret P, Lustig S. The role of the meniscotibial ligament in posteromedial rotational knee stability. Knee Surg Sports Traumatol Arthrosc 2015;23(10): 2967–2973
4 LaPrade RF, Engebretsen AH, Ly TV, Johansen S, Wentorf FA, Engebretsen L. The anatomy of the medial part of the knee. J Bone Joint Surg Am 2007;89(09):2000–2010
5 Hauch KN, Villegas DF, Haut Donahue TL. Geometry, time-dependent and failure properties of human meniscal attachments. J Biomech 2010;43(03):463–468
6 Seitz A, Kasisari R, Claes L, Ignatius A, Dürselen L. Forces acting on the anterior meniscotibial ligaments. Knee Surg Sports Traumatol Arthrosc 2012;20(08):1488–1495
7 Millar AP. Meniscotibial ligament strains: a prospective survey. Br J Sports Med 1991;25(02):94–95
8 Liu F, Yue B, Gadikota HR, et al. Morphology of the medial collateral ligament of the knee. J Orthop Surg Res 2010;5:69
9 De Maeseneer M, Van Roy F, Lenchik L, Barbaix E, De Ridder F, Osteaux M. Three layers of the medial capsular and supporting structures of the knee: MR imaging-anatomic correlation. Radiographics 2000;20(Spec No):S83–S89
10 Griffith CJ, LaPrade RF, Johansen S, Armitage B, Wijdicks C, Engebretsen L. Medial knee injury: Part 1, static function of the individual components of the main medial knee structures. Am J Sports Med 2009;37(09):1762–1770
11 DePhillipo NN, Moatshe G, Chahla J, et al. Quantitative and Qualitative Assessment of the Posterior Medial Meniscus Anatomy: Defining Meniscal Ramp Lesions. Am J Sports Med 2019;47 (02):372–378
12 Cavaignac E, Sylvie R, Teulières M, et al. What Is the Relationship Between the Distal Semimembranosus Tendon and the Medial Meniscus? A Gross and Microscopic Analysis From the SANTI Study Group. Am J Sports Med 2021;49(02): 459–466

 © 2022. Sociedade Brasileira de Ortopedia e Traumatologia. All rights reserved.