Article published online: 2022-06-10

THIEME OPEN ACCESS

Update Article

Child Fractures: Are We Getting More Surgical?*

Fraturas na criança: Estamos ficando mais cirúrgicos?

Luiz Antônio Munhoz da Cunha[1] Mariana Demétrio de Sousa Pontes[1]

[1] Pediatric Orthopedics Service, Hospital Pequeno Príncipe, Curitiba, PR, Brazil

Address for correspondence Prof. Dr. Luiz Antônio Munhoz da Cunha, MD, MSc, PhD, Rua Desembargador Motta, 1070, Água Verde, 80250-060, Curitiba, Paraná, Brazil (e-mail: lamcunha@gmail.com).

Rev Bras Ortop

Abstract

Historically, surgeries on the immature skeleton were reserved for open or articular fractures. In recent years, the improvement in the quality and safety of anesthesia, new imaging equipment, implants designed especially for pediatric fractures, associated with the possibility of shorter hospitalization time and rapid return to social life has demonstrated a new tendency to evaluate and treat fractures in children. The purpose of this update article is to answer the following questions: (1) Are we really turning more surgical in addressing fractures in children? (2) If this is true, is this surgical conduct based on scientific evidence? In fact, in recent decades, the medical literature demonstrates articles that support better evolution of fractures in children with surgical treatment. In the upper limbs, this is very evident in the systematization of the reduction and percutaneous fixation of supracondylar fractures of the humerus and fractures of the forearm bones. In the lower limbs, the same occurs with diaphyseal fractures of the femur and tibia. However, there are gaps in the literature. The available published studies show low scientific evidence. Thus, it can be inferred that, even though the surgical approach is more present, the treatment of pediatric fractures should always be individualized and conducted according to the knowledge and experience of the professional physician, taking into account the presence of technological resources available for the care of the small patient. All possibilities, non-surgical and/or surgical, should be included, always instituting actions based on science and in agreement with the family's wishes.

Keywords

- cartilage, epiphyseal
- fracture fixation, internal
- fractures, growth plate
- fractures, bone
- orthopedics
- pediatrics

Resumo

Historicamente, as cirurgias no esqueleto imaturo eram reservadas às fraturas expostas ou articulares. Nos últimos anos, a melhora na qualidade e segurança das anestesias, novos equipamentos de imagem, implantes desenhados especialmente para fraturas pediátricas, associados à possibilidade de menor tempo de hospitalização e rápido retorno ao convívio social vêm demonstrando uma nova tendência de avaliar e tratar fraturas na criança. O objetivo deste artigo de atualização é responder às seguintes questões: (1) estamos realmente ficando mais cirúrgicos na abordagem das fraturas em crianças? (2) Caso isto seja verdadeiro, esta conduta cirúrgica está baseada em evidências científicas? De fato, nas últimas décadas, a literatura médica demonstra artigos que suportam melhor evolução das fraturas na criança com o tratamento

Palavras-chave

- cartilagem epifisial
- fixação interna de fraturas
- fraturas da placa de crescimento
- fraturas ósseas
- ortopedia
- pediatria

* *Work developed at Hospital Pequeno Príncipe, Curitiba, PR, Brazil.*

received
November 6, 2021
accepted
March 28, 2022

DOI https://doi.org/10.1055/s-0042-1748814.
ISSN 0102-3616.

© 2022. Sociedade Brasileira de Ortopedia e Traumatologia. All rights reserved.
This is an open access article published by Thieme under the terms of the Creative Commons Attribution-NonDerivative-NonCommercial-License, permitting copying and reproduction so long as the original work is given appropriate credit. Contents may not be used for commercial purposes, or adapted, remixed, transformed or built upon. (https://creativecommons.org/licenses/by-nc-nd/4.0/)

Thieme Revinter Publicações Ltda., Rua do Matoso 170, Rio de Janeiro, RJ, CEP 20270-135, Brazil

cirúrgico. Nos membros superiores, isto fica muito evidente na sistematização da redução e fixação percutânea das fraturas supracondilianas do úmero e das fraturas de ossos do antebraço. Nos membros inferiores, o mesmo ocorre com fraturas diafisárias do fêmur e tíbia. No entanto, há lacunas na literatura. Os estudos publicados são geralmente com baixa evidência científica. Assim, pode-se deduzir que, mesmo sendo a abordagem cirúrgica mais presente, o tratamento de fraturas pediátricas deve ser sempre individualizado e conduzido de acordo com o conhecimento e experiência do médico profissional, levando em conta a presença de recursos tecnológicos disponíveis para o atendimento do pequeno paciente. Deve-se incluir todas as possibilidades, não cirúrgicas e/ou cirúrgicas, sempre instituindo ações baseadas na ciência e em concordância com os anseios da família.

Introduction

Traumatic injuries in immature skeletons have increased in recent years.[1,2] Each year, at least 2% of children suffer some type of fracture.

Joeris et al.,[3] in an epidemiological study with 2,716 children treated between 2009 and 2011, observed 2,840 fractures of long bones, 59% in the radius/ulna; 21% in the humerus; 15% in the tibia/fibula, and 5% in the femur. The mean age in this study was 8.2 years old, 6% of which were infants; 26% preschoolers; 40% school children, and 28% adolescents. Fractures in adolescents were more common in males. Twenty-seven percent of fractures in children were related to a fall from height; 50% took place in recreational and/or domestic activities; 11% in traffic accidents; and 8% of the fractures occurred in the school environment. Twenty-six percent of the patients were overweight or obese. The authors concluded that the difference in fracture distribution is mainly related to the patients' sex and age, and report that overweight and obesity increase the risk of fractures in children.

Fractures in children and adolescents, with some frequency, can lead to complications, some of them exclusively linked to the growth of the extremities. The growth cartilages, located in the metaphysis of the long bones, due to their firmer anatomy and consistency, often act as protectors of the articular surface, as they partially absorb the impact/trauma at said extremity. However, when injured, they can lead to unique complications and harmful consequences to the growing skeleton, such as deformities and bone shortening.[4] On the other hand, in some types of fractures, the growth provided by epiphyseal cartilages can also act as a great ally in the correction of residual deformities. Other favorable factors in children's fractures are the greater plasticity of the bone, the thicker and active periosteum, and the faster consolidation process, because the periosteum functions as a stabilizing and facilitating element of conservative treatment. This bone remodeling will not occur or will not be adequate in fractures that compromise the joint, the epiphyseal cartilage or those that affect the diasphysis and produce deviations and/or with excessive shortening.[4]

The change in the physician's behavior in relation to the type of treatment, conservative or surgical, in some fractures in children, has been influenced by several factors: technological development, availability of imaging equipment in surgical centers, safer anesthesias, better bone implants designed specifically for the pediatric skeleton and orthopedists' surgical training in minimally invasive surgeries. These resources have introduced a new way to diagnose, evaluate, and treat traumatic, bone and/or ligament injuries, and, as it could not fail to be, also fractures in children.

Orthopedics and traumatology, as other medical specialties, changed and ended up suffering an irreversible division into subareas.[5,6] With this specialization, the physician also had better knowledge and preparation to perform surgeries that, in part, can influence the time of hospitalization, the ease of care by the parents and give a faster rehabilitation.

In view of the above, some questions can be raised and constitute the main objective of this update article: (1) Are we really turning more aggressive in the approach to fractures in children? (2) If this new approach to pediatric fractures is true, is it supported by evidence-based medicine?

Special Aspects In Traumatic Injuries Of The Immature Skeleton

The bones in children are very cellularized, have a high coefficient of elasticity and, sometimes, when they suffer trauma, they deform without presenting an evident trace of fracture (plastic deformation). Subperiosteal lesions at the junction of the metaphysis with the diaphysis may also hinder the diagnosis if radiographs are evaluated by less experienced professionals.[7] In the elbow, as well as in other bone extremities, the multiple ossification centers may confuse the physician and lead to a mistaken fracture diagnosis.

Mardani-Kivi et al.[8] evaluated the influence of emergency physicians, not specialized in orthopedics, on decisions related to pediatric fractures, especially of the forearm and elbow. Fractures of 108 patients under the age of 14 years were evaluated by two physicians, one emergency physician

 © 2022. Sociedade Brasileira de Ortopedia e Traumatologia. All rights reserved.

and one orthopedist. Sixty-four percent of the fractures received the same diagnosis, but, in the other 36%, there were statistically significant differences, mainly in relation to fractures of the lateral condyle of the elbow and in fractures of the distal radius compromising the growth cartilage. The authors concluded that in institutions that have emergency physicians, they should be better educated about fractures in children.

Some fractures are exclusive to children and adolescents, including obstetric fractures and accidental and non-accidental fractures (maltreatment) that affect the epiphysis cartilage (physis) and/or the diasis of long bones. Non-accidental fractures related to violence against children and adolescents require medical knowledge for their diagnosis and constitute a major public health problem.[9,10]

Surgeries in fractures in children require special care regarding lower tolerance to blood loss, injury to growth areas, and the possibility of significant complications in cases of infection.

The Treatment of Fractures in Children

Blount,[11] in 1955, reported that due to the anatomical and physiological characteristics of the immature bone, surgical treatment is rarely indicated in children. Charnley,[12] in his classic treatise: "*The Incrusing Treatment of Frequent Fractures*" states: "*we are not yet in a position to compare conservative treatment with surgery due to the great technical difficulties and complications of fixations*". In the same book, in the 2003 edition, he ratified his preference for conservative treatment. Ogden,[13] in 1984, wrote that the principles of reduction and surgical fixation for adult fractures should not be extrapolated for the treatment of fractures in children, since, almost always, they are related to delayed consolidation. According to him, surgeries for fractures in children should be reserved for fractures of the humerus' lateral condyle and the femoral neck.

Few reports of surgeries on children's fractures occurred until the 1990s. One of the pioneers to draw attention to surgical fixation of fractures in children was Wilkins,[14] who, in 1991, stated that the quality of images facilitates the diagnosis and treatment of skeletal lesions, making clearer the indications for surgical interventions in pediatric fractures.

Since then, reports on fracture fixation have become more frequent, especially in fractures of the elbow and forearm—in the upper limbs—and femur and tibia—in the lower limbs. This surgical trend has been increasing progressively in the last three decades.[15]

Literature Data

Data obtained from the medical records of patients treated in trauma centers show that there is a significant percentage increase in the surgical treatment of fractures in children. Cheng et al.,[16] in 1999, reported an increase from 3 to 22% between 1985 and 1995 in the percutaneous fixations of supracondylian fractures of the elbow, distal radius, and diaphysary fractures of the femur. Helenius et al.,[17] between 1997 and 2006, observed a 22% increase in the rate of fractures attended when compared to previous years, and an increase of 28% in surgeries in upper limbs fractures and 4% in lower limbs fractures. Some records also demonstrate the significant increase in forearm bone surgeries using intramedullary fixation.[2,18,19] Meling et al.[20] analyzed data from a center in Norway and observed that 61% of fractures in children are treated conservatively, 31% through percutaneous fixation and 8% through internal fixation.

In relation to upper limb fractures, these represent 70 to 90% of fractures in the pediatric population. Fractures in the proximal humerus, even in older children, are rarely treated surgically for the ease of bone consolidation and remodeling provided by the large range of motion of the shoulder joint.[21] Even with good results with the non-surgical treatment of these fractures, Dobbs et al.[22] suggest a reduction in deviated fractures that affect adolescents over 12 years of age who present significant deviation. They also suggest percutaneous fixation of fractures that are unstable. In unacceptable reductions, they propose open reduction through access to the fracture focus by the deltopectoral groove. Hannonen et al.[23] studied 300 patients under 16 years of age with proximal humerus fractures treated at a pediatric trauma center between 2005 and 2015. These authors pointed out that the incidence of this fracture remains stable, but the rate of surgical treatment in relation to the conservative one has increased, even though the reasons for such elevation remain uncertain.

The supracondylar fracture of the humerus is the second most frequent in the upper limbs in children, and its peak incidence is between 5 and 8 years of age. Among the fractures of the upper limbs, this is the one that has the most expressive results in relation to surgical stabilization. Surgery in this fracture is associated with lower rates of neurovascular lesions, compartment syndrome and residual deformities, such as varus.[24] A Finnish study[25] evaluated a sample of 9,017 supracondylar humerus fractures surgically treated over a 30-year period. The authors noted that, over time, surgeons began to perform osteosynthesis of the distal humerus four times more frequently. In the same study, they also noted a significant reduction in late reconstructive procedures, such as those necessary for the treatment of sequelae of compartment syndromes and osteotomies for the correction of residual deformities. Few fractures benefit from both treatment standardization (unscrupulous reduction and percutaneous fixation with Kirschner wires) and supracondylar humerus fracture. Surgical management, in Gartland grade IIb or III devious fractures, minimizes complications and virtually eliminates the chances of reinterventions, besides favoring functional recovery in a few weeks. The configuration in the placement of the pins in the fixation of this fracture, crossed or unilateral divergent, has been the subject of some controversy. Lamdan et al.[26] concluded that, under normal implantation conditions, two divergent

 © 2022. Sociedade Brasileira de Ortopedia e Traumatologia. All rights reserved.

lateral wires offer satisfactory mechanical stability. In addition, lateral placement of the wires prevents iatrogenic injury of the ulnar nerve. Vascular changes may be present in 10 to 20% of the diverted supracondylar fractures, but, most of the time, the perfusion is restored soon after the reduction of the fragments. Nerve lesions are usually neuropraxias, which occur in 6.5 to 19% of cases and improve spontaneously. At first, there is no indication for surgical exploration of the fracture and/or injured nerve in the initial treatment. Open reductions are reserved for open fractures, vascular lesions without capillary filling for more than 10 minutes after reduction, or failures in the reduction in the fracture approach.[27]

On the treatment of forearm fractures in children and adolescents, it is known that, although the unscrupulous reduction followed by plastered immobilization is considered the gold standard, there has been a growing trend towards surgical stabilization of diaphysary fractures.[28] In general, studies suggest that surgery should be reserved for cases in which satisfactory alignment is not achieved by closed reductions.[29]

Kim et al.[30] analyzed the results of intramedullary fixation with flexible stems in 40 children and adolescents with diaphyseal or meta-diaphyseal fractures of the forearm. Eight out of 40 patients required open fracture reduction, and consolidation time occurred, on average, after 8.3 weeks. In 38 patients, the result was good and, in 2, excellent (recovery of mobility in rotation). The authors concluded that the method produces satisfactory results maintaining adequate stability and mobility of the segment.

Pogorelić et al.[31] retrospectively evaluated 173 forearm fractures treated with flexible intramedullary nail stems with a mean follow-up of 68 months. They demonstrated that this type of minimally invasive fixation promotes good results both functional and cosmetic, has very low complication rates, and often dispenses with the use of additional stabilization by a casted apparatus.

Stöckell et al.[32] evaluated the stage of development of the four elbow ossification centers, according to the Classification of Sauvegrain and Dimeglio, and correlated its development with possible alterations in the consolidation of forearm fractures treated with intramedullary fixation with flexible stems. They suggest that, in stages equal to or greater than 6 of the olecranon ossification nucleus, the occurrence of changes in consolidation is more frequent.

Volpon,[33] in 2008, recommended that diaphyseal fractures of forearm bones in children be fixed, when necessary, with titanium rods. According to him, these fractures are among those that most benefit from surgical treatment. He emphasized that the correct diagnosis and reduction of the poor alignment of forearm bones should be taken to maximum values of 20° in the metaphysis; 15° in the diaphysis, and 10° in the proximal region. He also established that these values should be lower the older the child is. He draws attention to the importance of the approach to fractures in the transition from metaphysis to the diasphysis and also to monteggia fractures-dislocations. It also proposes to establish the first treatment as the definitive one, avoiding re-interventions.

Liu et al.[34] compared two types of treatment in 175 fractures of the distal third of forearm bones in children between 8 and 14 years of age. One hundred and fourteen were fixed percutaneously and 61 submitted to unscrupulous reduction and immobilization in plastered apparatus. Postreduction angulation, residual angulation in the last follow-up, radiation exposure, total immobilization time, time of absence from school, total costs, and complications were evaluated. Postreduction angulation was significantly lower in the group submitted to percutaneous fixation, but after 6 months of follow-up, the residual deformity was similar. According to the authors, patients undergoing non-operative reduction received more radiation than those treated surgically through percutaneous fixation.

In the lower limbs, some fractures, such as proximal fractures of the femur, deserve special care. Diagnosis should be rapid and appropriate, as they require adequate stabilization and anatomical reduction to minimize the possibility of serious complications such as osteonecrosis.[35]

Freitas,[36] in his study published in 2006, already warns of the severity of femoral neck fracture in children due to high rates of complications (40%). Alluri,[37] when evaluating a national database in the USA, demonstrates an increase in the rates of fixation of femoral diaphyseal fractures with flexible intramedullary stems of 35 and 58%, respectively, for the 4- and 5-year-old age groups, between 1997 and 2012. According to him, this increase is related to several factors, including the fact that spica casting entails greater risks of vicious consolidation, delay in joint mobilization and demand greater care by parents. Santili et al.,[38] in 2002, used flexible titanium rods in 8 patients aged 8 to 12 years with femoral diaphyseal fractures and found an important reduction in hospitalization time, evolution to support in the fractured limb and early joint mobility. Even though these are preliminary results, the authors are optimistic about the surgical treatment that progresses to consolidation and functional recovery without major complications. In 2012, Soni,[39] when retrospectively evaluating[24] pediatric femur diaphyseal fractures, suggested that titanium elastic intramedullary rods are related to good results in unstable fractures.

Leet et al.[40] studied the treatment of femoral fractures in children with cerebral palsy. They evaluated 47 fractures, 22 in non-ambulatory patients, and 15 in ambulatory patients. Even with complications, such as residual deviations and pseudoarthrosis, in fractures treated with unscrupulous treatment and/or surgeries, the authors recommend that fractures in children with non-ambulatory cerebral palsy be addressed in a non-surgical manner. Its follow-up should be careful to avoid major residual deviations or areas of pressure by the plaster. However, surgical alignment and fixation in femoral fractures should

 © 2022. Sociedade Brasileira de Ortopedia e Traumatologia. All rights reserved.

be considered in paralyzed cerebral patients with good walking capacity.

In the case of tibia fractures, the third most common fracture of the child's long bones, a retrospective study also showed increased rates of surgical treatment over time. Kleiner et al.[41] evaluated[24]166 diaphyseal tibial fractures over a 12-year period and observed that the highest incidence of fixation was in the age groups between 5 and 9 years, older adolescents, and in patients with associated fractures of the femur. Although traditionally treated conservatively,[42] Rickert et al.[43] suggest that fractures of the tibia with more than 20% deviation and associated with fibula fracture are operated, as they present a 40% risk of residual deformities that will culminate in late surgical intervention.

Weber et al.[44] reported that, among 168 tibia fractures in children treated in the emergency room between 2005 and 2017, 38 were surgically treated, 36 of which were fixed with flexible rods or plate and two stabilized with external fixator. The mean age of the patients treated conservatively was statistically lower (6 years old) when compared to that of the operated patients (10.2 years old). They concluded that, up to 4 years of age, tibial fractures are simpler and quickly consolidate with conservative treatment, while fractures fixed with intramedullary nail stems are related to a longer time of consolidation. Despite this, the rehabilitation time was similar in both groups.

Civan et al.[45] investigated the time of consolidation of tibia fractures in 46 patients with a mean age of 9.5 years old, relating it to variables of age, type of fracture (closed or exposed), location in bone (diaphysary or metaphysary), association with fibula fracture, and type of treatment instituted (unscrupulous reduction and plaster or surgery). The consolidation score was evaluated at 4, 6, and 8 weeks after the fracture, and the authors noted that there is a negative correlation between age and the consolidation score. Conservative treatment is related to better consolidation score, and open fractures, or those associated with fibula fracture, have significantly lower consolidation score. The level of the fracture in the bone showed no differences in relation to the consolidation score.

In recent decades, children have started to participate in riskier sports and recreational activities that expose them to a higher risk of fractures. Traffic accidents, collisions and/or hit-and-run also directly impact the increase in fractures in children and adolescents.[14] A greater exposure to accidents may be related to the appearance of new patterns of injuries, of high energy, in this age group.[14] Thus, these new types of injury, related or not to polytrauma, may also impact on the change in behavior of surgeons when deciding between non-surgical and surgical options in infant fractures.[2]

Some protocols have been developed by international societies to guide orthopedists in decision making and patient care. Although very useful, they are unclear and have no high level of evidence.[46,47] It is important to emphasize that, even with apparent benefits, surgical treatment of fractures in children is a therapeutic method that requires general anesthesia for its execution and, often, a second procedure, also under anesthesia, to remove the synthesis material. Surgeries in children, as well as in adults, are also related to other complications of higher morbidity, such as infection and changes in bone consolidation.[48]

Scientific Evidence

Fractures in which surgery has been most frequently indicated are: supracondylar of the humerus (►**Figure 1**), forearm bones (►**Figure 2**), and femoral dyaphysis (►**Figure 3**). It is not discussed that surgical reduction with percutaneous fixation of the supracondylar humerus fracture brought benefits to patients, reducing complications and the need for reoperations. In the same way, fixation with flexible rods in fractures of long bones, in upper and lower limbs, they promote early consolidation and rehabilitation.

Although increased surgical tendency exists for supracondylar fracture of the humerus, fractures of the forearm, femoral neck, femoral and tibia diaphysis, most of the studies that recommend it are levels IV and V. Similarly, articles of

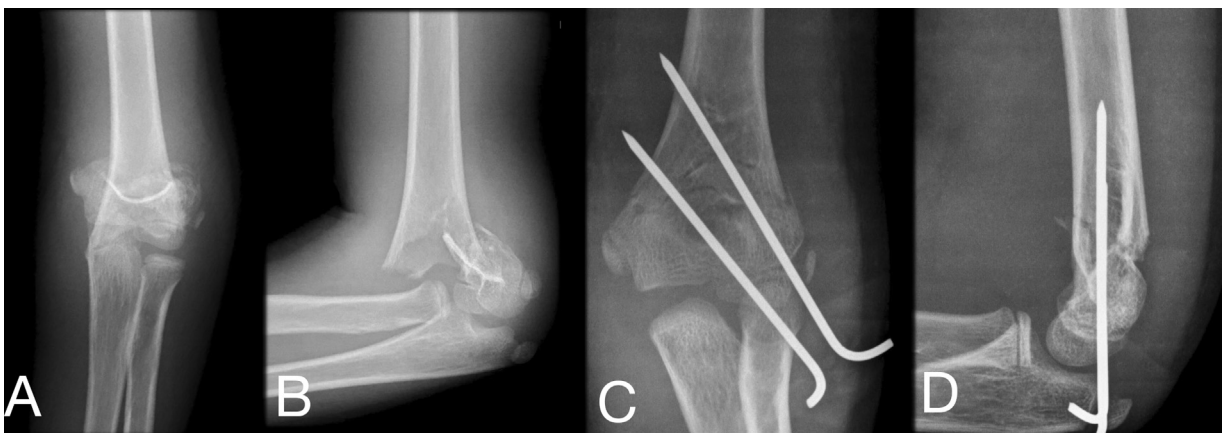

Fig. 1 Radiographs in anteroposterior (A) and profile (B) incidences of an 8-year-old female patient evidencing supracondylar humerus fracture, submitted to incruent reduction and percutaneous fixation with two divergent Kirschner wires with entrance by lateral condyle (C and D).

 © 2022. Sociedade Brasileira de Ortopedia e Traumatologia. All rights reserved.



Fig. 2 Radiographs in anteroposterior (A) and profile (B) incidences of a 9-year-old female patient with fractures of the distal third of the radius and ulna diaphysis, treated with closed reduction and fixation with flexible intramedullary titanium rods (C and D).

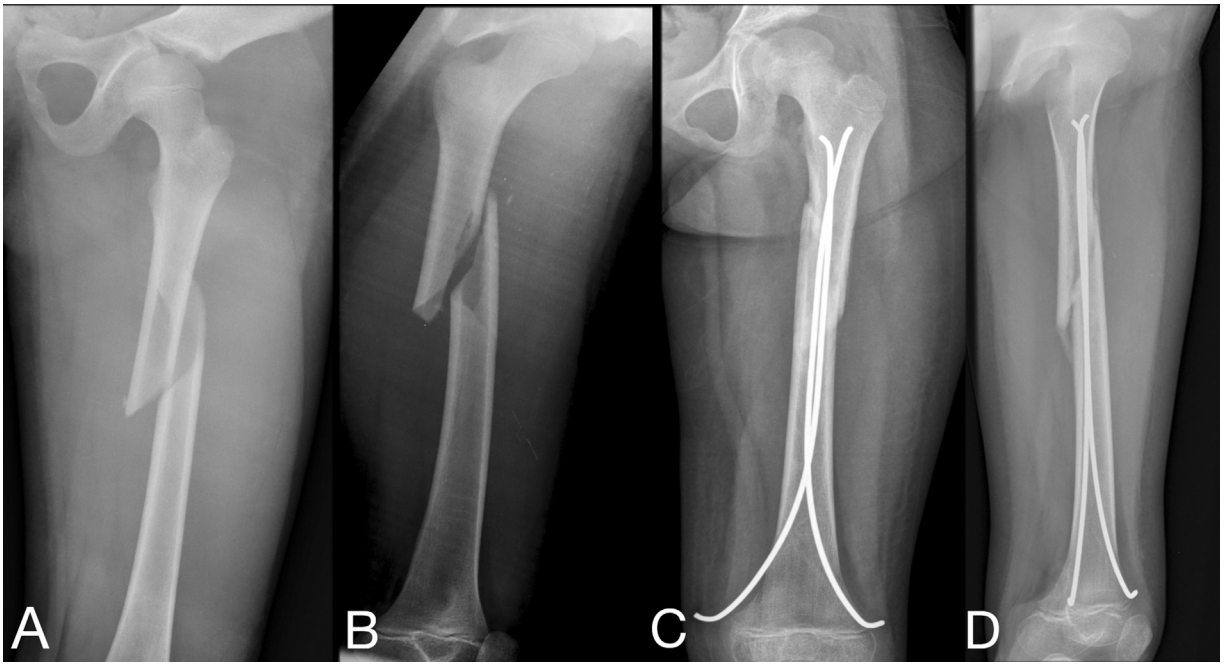

Fig. 3 Radiographs in anteroposterior (A) and profile (B) incidences of a 7-year-old female patient showing diaphyseal fracture of the femur, with indication of closed reduction and osteosynthesis with flexible intramedullary titanium stems (C and D).

the same scientific level show excellent functional results in fractures of the forearm, femur, tibia, and even of the distal humerus, with non-operative treatment. Thus, the lack of controlled studies prevents the establishment of protocols with evident superiority of surgical methods over conservative ones. It is very difficult to affirm that, in the long term, surgical treatment is superior to conservative treatment, even if some benefits are evident in the care and rehabilitation of some fractures with surgery.

Final Considerations

Certainly, in recent decades, the increase in the indication of surgical treatment for pediatric fractures has been evident. There are, however, gaps in the literature in determining the best treatment for each fracture in children and adolescents.

Randomized controlled trials have many ethical limitations in these cases. Thus, it is not possible to determine with safety whether the surgical treatment, already consolidated, is superior to the non-operative treatment.

Thus, the surgical indication should be individualized and conducted in accordance with the experience of the surgeon, with the available technological resources, based on the literature and the family's wishes.

Conflict of Interests

The authors declare that there is no conflict of interests.

 © 2022. Sociedade Brasileira de Ortopedia e Traumatologia. All rights reserved.

References

1 Landin LA. Epidemiology of children's fractures. J Pediatr Orthop B 1997;6(02):79–83
2 Ömeroğlu H, Cassiano Neves M. Tendency towards operative treatment is increasing in children's fractures: results obtained from patient databases, causes, impact of evidence-based medicine. EFORT Open Rev 2020;5(06): 347–353
3 Joeris A, Lutz N, Wicki B, Slongo T, Audigé L An epidemiological evaluation of pediatric long bone fractures - a retrospective cohort study of 2716 patients from two Swiss tertiary pediatric hospitals. BMC Pediatr 2014;14(14):314
4 Conrad EU, Rang MC. Fractures and sprains. Pediatr Clin North Am 1986;33(06):1523–1540
5 Holt JB, Glass NA, Bedard NA, Weinstein SL, Shah AS. Emerging U.S. National Trends in the Treatment of Pediatric Supracondylar Humeral Fractures. J Bone Joint Surg Am 2017;99 (08):681–687
6 Hosseinzadeh P, Rickert KD, Edmonds EW. What's New in Pediatric Orthopaedic Trauma: The Upper Extremity. J Pediatr Orthop 2020;40(04):e283–e286
7 Boutis K. The Emergency Evaluation and Management of Pediatric Extremity Fractures. Emerg Med Clin North Am 2020;38(01): 31–59
8 Mardani-Kivi M, Zohrevandi B, Saheb-Ekhtiari K, Hashemi-Motlagh K. How Much are Emergency Medicine Specialists' Decisions Reliable in the Diagnosis and Treatment of Pediatric Fractures? Arch Bone Jt Surg 2016;4(01):60–64
9 Kemp AM, Dunstan F, Harrison S, et al. Patterns of skeletal fractures in child abuse: systematic review. BMJ 2008;337:a1518
10 Berthold O, Frericks B, John T, Clemens V, Fegert JM, Moers AV. Abuse as a Cause of Childhood Fractures. Dtsch Arztebl Int 2018; 115(46):769–775
11 Blount WP. Fractures of the forearm in children. Pediatr Clin North Am 1955;2(04):1097–1119
12 Charnley J. The Closed Treatment of Common Fractures. 4th ed. Cambridge: Cambridge University Press; 2003
13 Ogden JA. Growth slowdown and arrest lines. J Pediatr Orthop 1984;4(04):409–415
14 Wilkins KE. Changing patterns in the management of fractures in children. Clin Orthop Relat Res 1991;(264):136–155
15 Gillingham BL, Rang M. Advances in children's elbow fractures. J Pediatr Orthop 1995;15(04):419–421
16 Cheng JC, Ng BK, Ying SY, Lam PK. A 10-year study of the changes in the pattern and treatment of 6,493 fractures. J Pediatr Orthop 1999;19(03):344–350
17 Helenius I, Lamberg TS, Kääriäinen S, Impinen A, Pakarinen MP. Operative treatment of fractures in children is increasing. A population-based study from Finland. J Bone Joint Surg Am 2009;91(11):2612–2616
18 Khuntia S, Swaroop S, Patro BP, Sahu S. Paediatric Long Bone Fractures Managed with Elastic Intramedullary Nails: A Retrospective Study of 30 Patients. Cureus 2020;12(04): e7847
19 Kruppa C, Bunge P, Schildhauer TA, Dudda M. Low complication rate of elastic stable intramedullary nailing (ESIN) of pediatric forearm fractures: A retrospective study of 202 cases. Medicine (Baltimore) 2017;96(16):e6669
20 Meling T, Harboe K, Søreide K. Incidence of traumatic long-bone fractures requiring in-hospital management: a prospective age- and gender-specific analysis of 4890 fractures. Injury 2009;40 (11):1212–1219
21 Beringer DC, Weiner DS, Noble JS, Bell RH. Severely displaced proximal humeral epiphyseal fractures: a follow-up study. J Pediatr Orthop 1998;18(01):31–37
22 Dobbs MB, Luhmann SL, Gordon JE, Strecker WB, Schoenecker PL. Severely displaced proximal humeral epiphyseal fractures. J Pediatr Orthop 2003;23(02):208–215
23 Hannonen J, Hyvönen H, Korhonen L, Serlo W, Sinikumpu JJ. The incidence and treatment trends of pediatric proximal humerus fractures. BMC Musculoskelet Disord 2019;20(01):571
24 Park MJ, Ho CA, Larson AN. AAOS Appropriate Use Criteria: Management of Pediatric Supracondylar Humerus Fractures. J Am Acad Orthop Surg 2015;23(10):e52–e55
25 Salonen A, Niemi ST, Kannus P, Laitakari E, Mattila VM. Increased incidence of distal humeral fracture surgery and decreased incidence of respective corrective osteotomy among Finns aged 0 to 18 years between 1987 and 2016: a population-based study. J Child Orthop 2019;13(04):399–403
26 Lamdan R, Liebergall M, Gefen A, Symanovsky N, Peleg E. Pediatric supracondylar humerus fractures: effect of bone-implant interface conditions on fracture stability. J Child Orthop 2013;7(06): 565–569
27 Vaquero-Picado A, González-Morán G, Moraleda L. Management of supracondylar fractures of the humerus in children. EFORT Open Rev 2018;3(10):526–540
28 Flynn JM, Jones KJ, Garner MR, Goebel J. Eleven years experience in the operative management of pediatric forearm fractures. J Pediatr Orthop 2010;30(04):313–319
29 Pace JL. Pediatric and Adolescent Forearm Fractures: Current Controversies and Treatment Recommendations. J Am Acad Orthop Surg 2016;24(11):780–788
30 Kim BS, Lee YS, Park SY, Nho JH, Lee SG, Kim YH. Flexible Intramedullary Nailing of Forearm Fractures at the Distal Metadiaphyseal Junction in Adolescents. Clin Orthop Surg 2017;9(01): 101–108
31 Pogorelić Z, Gulin M, Jukić M, Biliškov AN, Furlan D. Elastic stable intramedullary nailing for treatment of pediatric forearm fractures: A 15-year single centre retrospective study of 173 cases. Acta Orthop Traumatol Turc 2020;54(04):378–384
32 Stöckell M, Pokka T, Lutz N, Sinikumpu JJ. Determining the development stage of the ossification centers around the elbow may aid in deciding whether to use ESIN or not in adolescents' forearm shaft fractures. Acta Orthop 2021;92(04):461–467
33 Volpon JB. Osteossíntese das fraturas diafisárias da criança com hastes intramedulares flexíveis. Rev Bras Ortop 2008;43(07): 261–270
34 Liu Y, Zhang FY, Zhen YF, Zhu LQ, Guo ZX, Wang XD. Treatment Choice of Complete Distal Forearm Fractures in 8 to 14 Years Old Children. J Pediatr Orthop 2021;41(09):e763–e767
35 Patterson JT, Tangtiphaiboontana J, Pandya NK. Management of Pediatric Femoral Neck Fracture. J Am Acad Orthop Surg 2018;26 (12):411–419
36 Freitas MB, Mothes FC, Alimena JLM, Dirani M, Lompa P, Machado-Neto L. Fratura do colo do fêmur em crianças. Rev Bras Ortop 2006;41(05):151–156
37 Alluri RK, Sabour A, Heckmann N, Hatch GF, VandenBerg C. Increasing Rate of Surgical Fixation in Four- and Five-year-old Children With Femoral Shaft Fractures. J Am Acad Orthop Surg 2019;27(01):e24–e32
38 Santili C, Akkari M, Waisberg G, Camargo AA, Nogueira FP, Prado JCL. Haste flexível de titânio na fratura de fêmur na criança. Rev Bras Ortop 2002;37(05):
39 Soni JF, Schelle G, Valenza W, Pavelec AC, Souza CD. Unstable femoral fractures treated with titanium elastic intramedullary nails, in children. Rev Bras Ortop 2015;47(05):575–580
40 Leet AI, Shirley ED, Barker C, Launay F, Sponseller PD. Treatment of femur fractures in children with cerebral palsy. J Child Orthop 2009;3(04):253–258
41 Kleiner JE, Raducha JE, Cruz AI Jr. Increasing rates of surgical treatment for paediatric tibial shaft fractures: a national database study from between 2000 and 2012. J Child Orthop 2019;13(02): 213–219
42 Stenroos A, Laaksonen T, Nietosvaara N, Jalkanen J, Nietosvaara Y. One in Three of Pediatric Tibia Shaft Fractures is Currently Treated Operatively: A 6-Year Epidemiological Study in two University

 © 2022. Sociedade Brasileira de Ortopedia e Traumatologia. All rights reserved.

Hospitals in Finland Treatment of Pediatric Tibia Shaft Fractures. Scand J Surg 2018;107(03):269–274
43 Rickert KD, Hosseinzadeh P, Edmonds EW. What's New in Pediatric Orthopaedic Trauma: The Lower Extremity. J Pediatr Orthop 2018;38(08):e434–e439
44 Weber B, Kalbitz M, Baur M, Braun CK, Zwingmann J, Pressmar J. Lower Leg Fractures in Children and Adolescents-Comparison of Conservative vs. ECMES Treatment. Front Pediatr 2021;9:597870
45 Civan O, Alimoğlu B, İçen M, et al. Pediatric tibial shaft and distal metaphyseal fractures. Jt Dis Relat Surg 2020;31(03):532–540
46 Hubbard EW, Riccio AI. Pediatric Orthopedic Trauma: An Evidence-Based Approach. Orthop Clin North Am 2018;49(02): 195–210
47 Scott ML, Baldwin KD, Mistovich RJ. Operative Versus Nonoperative Treatment of Pediatric and Adolescent Clavicular Fractures: A Systematic Review and Critical Analysis. JBJS Rev 2019; 7(03):e5
48 Hogue GD, Wilkins KE, Kim IS. Management of Pediatric Tibial Shaft Fractures. J Am Acad Orthop Surg 2019;27(20): 769–778

 © 2022. Sociedade Brasileira de Ortopedia e Traumatologia. All rights reserved.