Article published online: 2022-07-06

THIEME OPEN ACCESS

Investigation the Effect of Human Recombinant Epidermal Growth Factor on Rotator Cuff Healing: An Experimental Model*

Investigação do efeito do fator de crescimento epidérmico recombinante humano na cicatrização do manguito rotador: Um modelo experimental

Anil Gulcu[1] Egemen Turhan[2] Ahmet Aslan[1] Sevil Çaylı[3] Ebru Alimogullari[3] Gülben Akcan[3]

[1] Department of Orthopedics and Traumatology, Faculty of Medicine, Alanya Alaaddin Keykubat University, Alanya/Antalya, Turkey
[2] Department of Orthopedics and Traumatology, Faculty of Medicine, Hacettepe University, Ankara, Turkey
[3] Department of Histology and Embryology, Ankara Yıldırım Beyazıt University, Medical Faculty, Ankara, Turkey

Address for correspondence Anil Gulcu, Assistant Professor, Faculty of Medicine, Alanya Alaaddin Keykubat University, Kestel, Merines Cd., 07450 Alanya/Antalya, Turkey (e-mail: anilgulcu@gmail.com).

Rev Bras Ortop

Abstract

Objective To investigate the effectiveness of human recombinant epidermal growth factor in the healing of rotator cuff tear in the rabbit shoulder.

Methods Rotator cuff tears (RCTs) were experimentally created on both shoulders of 20 New Zealand rabbits. The rabbits were divided into the following groups: RCT (sham group; $n = 5$), RCT + EGF (EGF group; $n = 5$), RCT + transosseous repair (repair group; $n = 5$), and RCT + EGF + transosseous repair (combined repair + EGF group; $n = 5$). All rabbits were then observed for 3 weeks, and biopsies were taken from the right shoulders in the third week. After three more weeks of observation, all rabbits were sacrificed, and a biopsy removed from their left shoulders. All biopsy material was stained with haematoxylin & eosin (H&E) and vascularity, cellularity, the proportion of fibers and the number of fibrocartilage cells were evaluated under light microscope.

Results The highest collagen amount and the most regular collagen sequence was detected in the combined repair + EGF group. The repair group and the EGF group showed higher fibroblastic activity and capillary formation when compared with the sham group, but the highest fibroblastic activity and capillary formation with highest vascularity was detected in the combined repair + EGF group ($p < 0.001$). EGF seems to

Keywords
- rotator cuff injuries
- wound healing
- epidermal growth factor

* *Study developed at the Faculty of Medicine, Alanya Alaaddin Keykubat University, Alanya/Antalya, Turkey*

received
November 13, 2021
accepted
April 28, 2022

DOI https://doi.org/10.1055/s-0042-1750831.
ISSN 0102-3616.

© 2022. Sociedade Brasileira de Ortopedia e Traumatologia. All rights reserved.
This is an open access article published by Thieme under the terms of the Creative Commons Attribution-NonDerivative-NonCommercial-License, permitting copying and reproduction so long as the original work is given appropriate credit. Contents may not be used for commercial purposes, or adapted, remixed, transformed or built upon. (https://creativecommons.org/licenses/by-nc-nd/4.0/)

Thieme Revinter Publicações Ltda., Rua do Matoso 170, Rio de Janeiro, RJ, CEP 20270-135, Brazil

improve wound healing in the repair of RCT. The EGF application alone, even without repair surgery, seems to be beneficial to RCT healing.
Conclusion In addition to rotator cuff tear repair, application of human recombinant epidermal growth factor has an effect on rotator cuff healing in rabbit shoulders.

Resumo

Objetivo Investigar a eficácia do fator de crescimento epidérmico (EGF) recombinante humano na cicatrização da lesão do manguito rotador no ombro de coelhos.
Métodos As rupturas do manguito rotador (RMRs) foram criadas experimentalmente em ambos os ombros de 20 coelhos Nova Zelândia. Os coelhos foram divididos nos seguintes grupos: RMR (grupo controle; $n = 5$), RMR + EGF (grupo EGF; $n = 5$), RMR + reparo transósseo (grupo reparo; $n = 5$) e RMR + EGF + reparo transósseo (grupo reparo combinado + EGF; $n = 5$). Todos os coelhos foram observados por 3 semanas e amostras de biópsias foram coletadas do ombro direito na terceira semana. Após mais três semanas de observação, todos os coelhos foram submetidos à eutanásia e uma amostra de biópsia foi coletada dos ombros esquerdos. Todo o material de biópsia foi corado com hematoxilina e eosina (H&E) para avaliação de vascularidade, celularidade, proporção de fibras e número de células fibrocartilaginosas à microscopia óptica.
Resultados O grupo reparo combinado + EGF apresentou a maior quantidade e a sequência mais regular de colágeno. O grupo reparo e o grupo EGF apresentaram maior atividade fibroblástica e formação capilar em comparação ao grupo controle, mas a maior atividade fibroblástica e a formação capilar com maior vascularidade foram detectadas no grupo reparo combinado + EGF ($p < 0,001$). O EGF parece melhorar a cicatrização da ferida no reparo da RMR. A aplicação isolada de EGF, mesmo sem cirurgia reparadora, parece melhorar a cicatrização da RMR.
Conclusão Além do reparo da RMR, a aplicação de EGF recombinante humano auxilia a cicatrização do manguito rotador de ombros de coelhos.

Palavras-chave
- cicatrização
- fator de crescimento epidérmico
- lesões do manguito rotador

Introduction

The rotator cuff is a complex anatomical structure that involves the humeral head and a multiple muscle insertion. Rotator cuff tears (RCTs) are the most common cause of shoulder pain, and intrinsic and extrinsic factors play a role in the etiopathogenesis of a RCT.[1] The indication of symptomatic RCTs can be listed as younger age, the full-thickness cuff tear, fail or insufficient response to non-operative management, occupations with the requirement of active overhead usage of shoulder, limitation of shoulder movements.[2] Despite all the advanced surgical management for the listed groups, poor healing in aging patients is the main problem for the management of this disease, and it can result in re-tears and poor functional outcomes.[2,3]

Attempts have been made to explain the occurrence of RCTs based on both intrinsic and extrinsic mechanisms. The morphology of acromion is suspected to account for degenerative RCTs, whereas hypovascularity is viewed as another explanation. Regardless of the underlying mechanism, the current treatment strategies are focused on the fixation of RCTs to bone.[4,5] For this reason, surgical methods are combined with various healing stimulators, platelet rich plasma (PRP), growth factors, and stem cells, etc. Despite the recent use of these factors, the combined effects of additive treatment modalities require further investigation for clarification and understanding of the basis of tendon healing.[6,7]

An experimental RCT model has shown that bone marrow stem cells, which are known to improve angiogenesis, also promote the growth of the tendon-bone interface.[6] Other important modulators, such as growth factors, are also being introduced as combination therapies for the medical treatment of many diseases. The main aim of all these strategies is to improve angiogenesis, suppress inflammatory responses, and increase cell proliferation at the site of injury.[8] Previous studies have reported the crucial role of growth factors in tendon healing through the promotion of cell proliferation and migration, matrix production, proteinase expression, fibronectin binding, promotion of cell proliferation, and collagen production.[7,8] These beneficial effects have been investigated in many kinds of musculoskeletal disorders.

One popular growth hormone used to treat musculoskeletal disorders is fibroblast growth factor (FGF). The beneficial effects of FGF as a potential RCT treatment was shown by Takahashi et al., who found upregulation of FGF in tenocytes as well as in tendon sheath fibroblasts and inflammatory cells in FGF-treated RCTs.[9] Vascular endothelial growth factor (VEGF) is another important modulator that can aid in the healing of musculoskeletal disorders. Bidder et al.[10] showed that VEGF treatment increased angiogenic effects and

 © 2022. Sociedade Brasileira de Ortopedia e Traumatologia. All rights reserved.

improved tendon healing in a canine experimental model. Similarly, epidermal growth factor (EGF) can also promote bone healing via a proposed mechanism that involves suppression of osteoblastic activity and promotion of osteogenic activity.[11]

The aim of the present study was to investigate the effects of human recombinant EGF on RCT healing in an experimental animal model. The effects of EGF on neovascularity, fibroblast activity, and collagen production were studied in a rabbit model of RCT.

Materials & Methods

The study protocols were designed according to the animal welfare act and the guide for the care and use of laboratory animals. Ethical approval was obtained from our animal ethics and research committee (approval number: 2020/464). New Zealand rabbits were housed in climate-controlled cages with standard humidity ($50 \pm 5\%$) and temperature ($22 \pm 2°C$) and with a 12-hour light/dark cycle in the laboratory of animal production unit in our animal laboratory. The sample size of the study was determined by the ethical committee to lead to minimal animal loss.

Study Protocol

Twenty male New Zealand rabbits (weighing between 2.5 and 3.5 kg) were divided into the following four groups:

- Sham group ($n = 5$): Experimental RCTs were created on both shoulders and closed without repair.
- EGF group ($n = 5$): Experimental RCTs were created on both shoulders, EGF was injected into both defects (25 µg/kg), and both were closed without repair.
- RCT repair group ($n = 5$): Experimental RCTs were created on both shoulders, and both tendon defects were repaired.
- Combined RCT repair + EGF group ($n = 5$): Experimental RCTs were created on both shoulders, both tendons were repaired, and EGF (75 µg/kg) was injected into both injury sites.

Surgical Procedure

Both shoulders were opened surgically with the rabbit under anesthesia (130 mg/kg i.p. ketamine [Ketalar - Pfizer Inc., New York, NY, USA] and 20 mg/kg i.p. xylazine [Rompun - Bayer AG, Leverkusen, Alemanha]). Antibiotic prophylaxis was administered as 20 mg/kg of intramuscular cefazolin sodium. As described in the previous literature, both deltoid muscles were split to expose the insertion of the supraspinatus tendon on the greater tuberosity, followed by transection of the supraspinatus tendon to create a tear almost 0.7 mm in length (►**Fig. 1**), while avoiding the insertion of the infraspinatus tendon.[12] The tears were repaired with a transosseous procedure using 5.0 prolene sutures (Ethicon, Johnson & Johnson, New Brunswick, NJ, USA). The EGF (Heberprot-P1, Centre for Genetic Engineering and Biotechnology (CIGB), Havana, Cuba) was injected into the injury sites in the relevant groups. Intratendinous EGF was applied to the separated part from the supraspinatus tendon with an insulin injector.



Fig. 1 Experimentally creating a tear with supraspinatus tendon transection. (*) shows supraspinatus tear.

Postoperative Follow-Up

All rabbits were placed in individual cages after the treatments and were fed a standard diet. Eating and drinking habits were monitored, and the wounds were examined and cleaned daily with alcohol. No adverse situations were observed during this monitoring. On the third week, the right shoulder of every rabbit was opened, and tissue samples were obtained for histopathological examination. On the sixth week, the left shoulder was opened, and tissue samples were obtained for histopathological examination. All animals were sacrificed after the final experimental steps were completed.

Histochemistry and Histopathologic Evaluation

Five animals of each group were sacrificed under general anesthesia by intramuscular injection of 2 ml xylazine at 21 days and 42 days postoperatively for histological evaluations. After enucleation, the tendon was fixed in 4% formaldehyde for 48 hours to prevent tissue autolysis and putrefaction. The portion of each tendon, including the wound site was dissected, and embedded in paraffin. At least 10 sections 4-µm thick were cut from each tissue block, placed on slides and deparaffinized with xylene and a graded ethanol series. Each section was stained with hematoxylin/eosin (H&E) to identify vascularity, cellularity, the proportion of fibers oriented parallel/large diameter collagen fibers and the numbers of fibrocartilage cells. These features were graded on a scale from 0 to 4 according to a modification of a previous grading system used by Ide et al.[13] The grading scores for all groups were as follows: 1: $< 25\%$, 2: 25–50%, 3: 50–75%, and 4: $> 75\%$.

Morphometric analysis of the slide images was performed by image digitization and computational analysis using a specific image processing and analysis program (Image J, 1.50i - NIH, Bethesda, MD, USA). The areas representing the proportion of fibers oriented parallel/large diameter collagen fibers, vascularity, and cellularity were digitized from 5 fields observed using an Olympus BX43 light microscope (Olympus Europa SE & Co. KG, Hamburg, Germany) at $\times 100$, $\times 200$ and $\times 400$ magnifications. The result for each element corresponds to the arithmetic mean of the percentage measured in each of the 5 adjacent fields (by the same researcher, S. C., for all cases).

 © 2022. Sociedade Brasileira de Ortopedia e Traumatologia. All rights reserved.

Statistical Analysis

Statistical analysis was performed with SigmaPlot version 14 (Jandel Scientific Corp., San Rafael, CA, USA) for histochemistry analysis. Repetitive measurements from three samples were performed for each type of experiment, and all quantitative data were presented as mean ± standard error (SE) for all groups. Significant differences in the variables were assessed by analysis of variance (ANOVA) on ranks with the Holm-Sidak method, and multiple comparisons between the specific groups were conducted. Statistical analysis was performed with the IBM SPSS Statistics for Windows Ver. 19.0 package program for clinical score analysis (IBM Corp., Armonk, NY, USA).

Results

During the follow-up period, no anaphylactic reaction, adverse effects, or mortality were observed in any of the four groups.

The EGF-treated group had tighter collagen regulation when compared with the sham group (►**Fig. 2 A**, **B**, **C**, **D**). Similarly, a higher collagen amount was detected in the EGF-treated group than in the sham group (►**Fig. 2**). Both the EGF and the sham groups had lower collagen amounts and a less regular collagen sequence when compared with the RCT repair group; however, the amount of collagen and the most regular collagen sequence were detected in the group receiving the combined RCT repair and EGF treatment (►**Fig. 2 E**, **F**, **G**, **H**). The group with the combined treatment also had the thickest collagen and tendon measurements. The results for collagen and tendon thickness are listed in ►**Table 1**.

The group treated with EGF also showed greater capillary formation and increased fibroblastic activity than in the sham group (►**Fig. 3 A**, **B**, **C**, **D**). The RCT repair group showed a moderate increment in capillary formation and fibroblastic activity when compared with the sham or EGF groups, but the highest fibroblastic activity and capillary formation with the highest vascularity was detected in the group receiving the combined RCT repair and EGF treatment (►**Fig. 3 E**, **F**, **G**, **H**). The histological results were

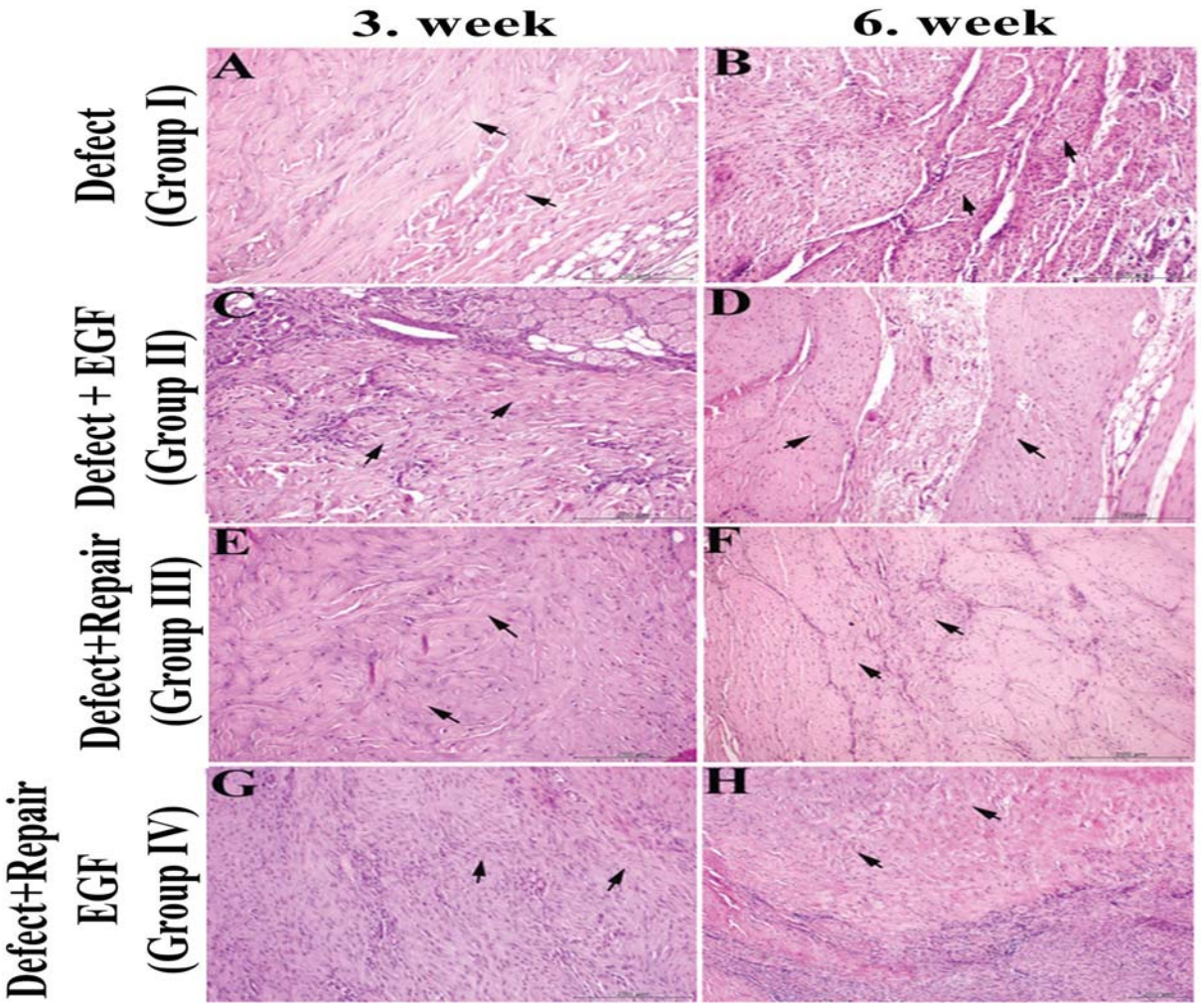

Fig. 2 The histological examination of collagen distribution and arrangement of fibers in tissue samples from a rabbit model of rotator cuff tear (RCT) treated with or without surgical repair and with or without epidermal growth factor (EGF). The changes in the third week are shown in A, C, E, and G, and the changes in the 6th week are shown in B, D, F, and H. The collagen bundles are indicated by black arrows. (Hematoxylin and eosin [H&E] staining; Bar: 20 µm)

 © 2022. Sociedade Brasileira de Ortopedia e Traumatologia. All rights reserved.

Table 1 Collagen and tendon thickness in samples from a rabbit model of rotator cuff tear treated with or without surgical repair and with or without epidermal growth factor

Groups	Defect	Defect + EGF*	Defect + repair	Defect + repair + EGF*	Defect	Defect + EGF*	Defect + repair	Defect + repair + EGF*
Sample histology	**3rd week n:5**	**3rd week n:5**	**3rd week n:5**	**3rd week n:5**	**6th week n:5**	**6th week n:5**	**6th week n:5**	**6th week n:5**
Collagen thickness	1.5 mm	1.9 mm	2.15 mm	2.4 mm	1.5 mm	1.9 mm	2.15 mm	2.4 mm
p	0.001							
Total tendon thickness	1.65 mm	2.15 mm	2.35 mm	2.55 mm	1.65 mm	2.15 mm	2.35 mm	2.55 mm
p	0.001							

*EGF: epidermal growth factor, $p < 0.05$ is significant

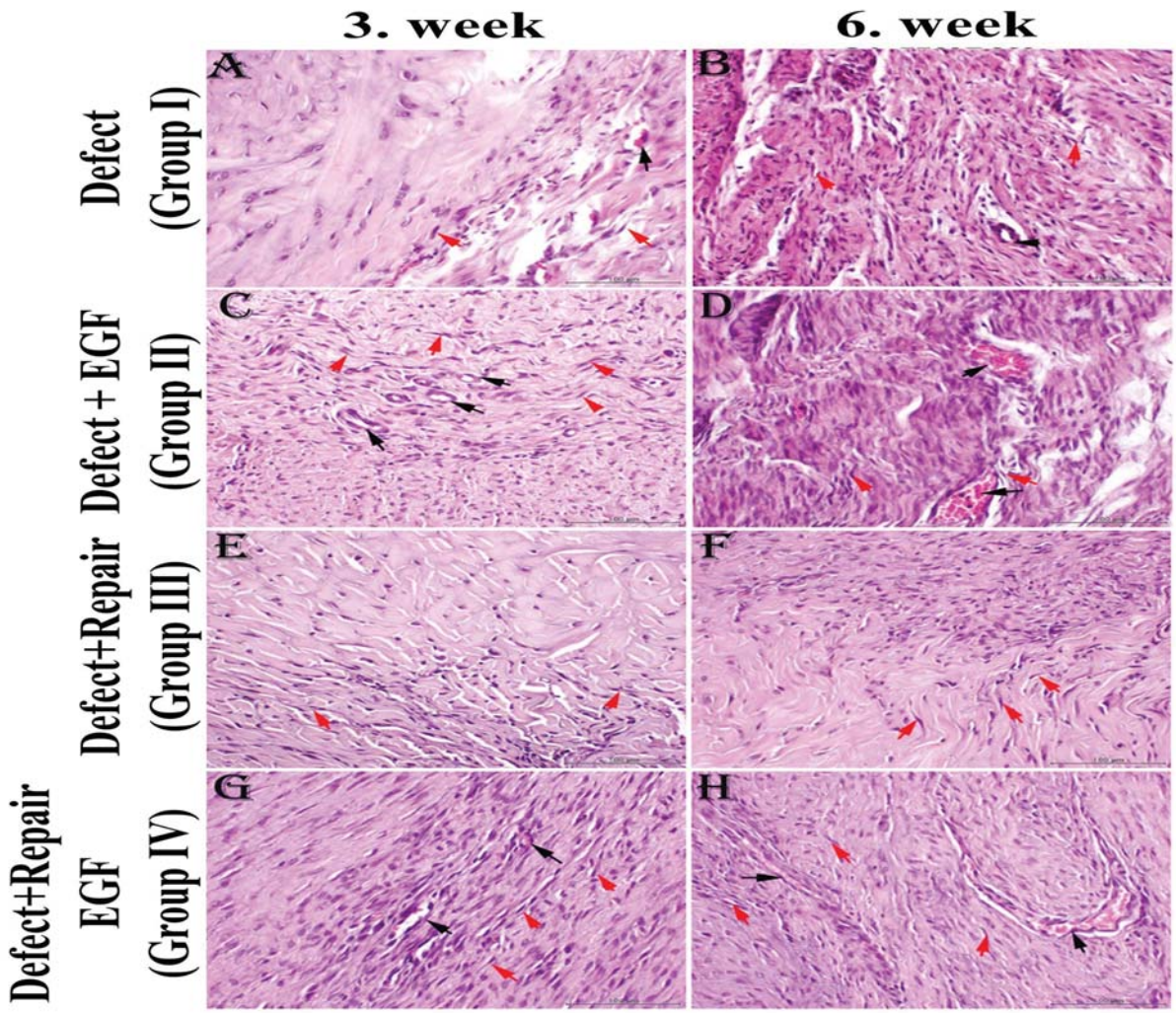

Fig. 3 The histological examination of the capillaries, the number of fibroblasts and their arrangement in tissue samples from a rabbit model of rotator cuff tear (RCT) treated with or without surgical repair and with or without epidermal growth factor (EGF). The changes in the third week are shown in A, C, E and G, and the changes in the sixth week are shown in B, D, F, and H. Capillaries are indicated with black arrows and fibroblast arrangements are marked with red arrows.

 © 2022. Sociedade Brasileira de Ortopedia e Traumatologia. All rights reserved.

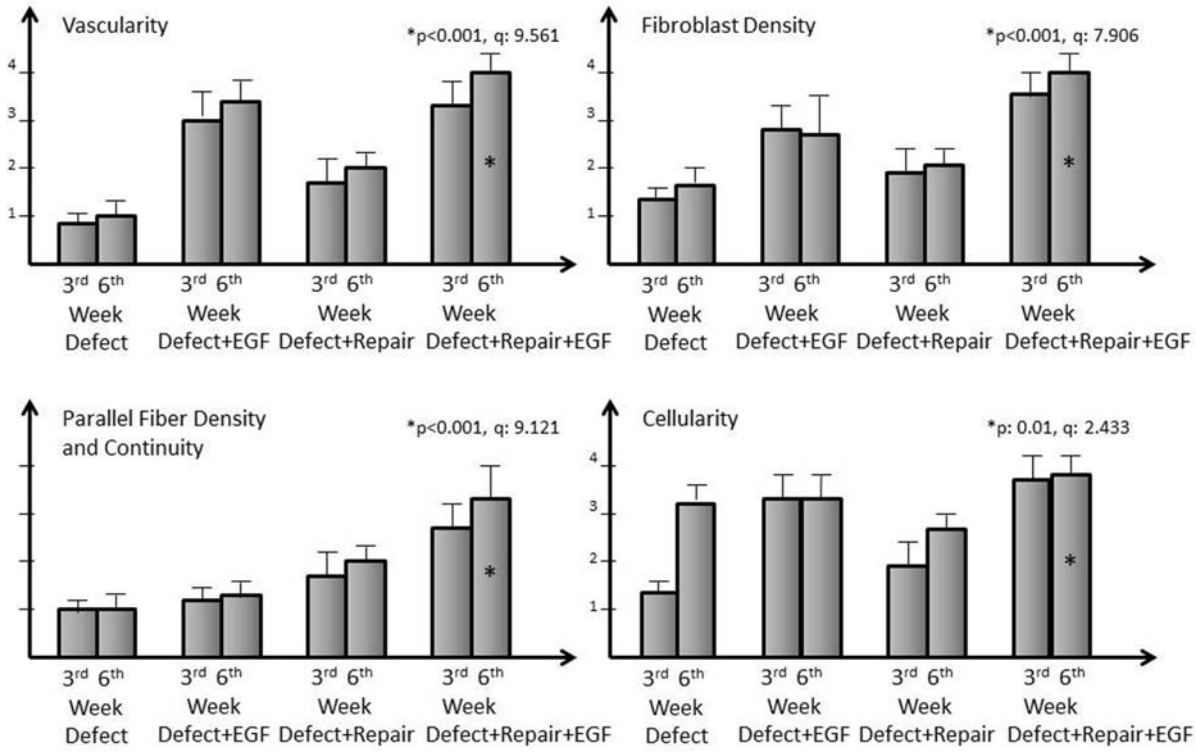

Fig. 4 Bar graphs of the tissue healing patterns for visual comparison between the groups.

similar for vascularity, collagen deposition and fibroblastic activity at the third and sixth weeks, although these cellular activities were slightly higher in the sixth than in the third week. The group receiving the combined treatment showed marked vascularity, fibroblast density, parallel fiber density and continuity ($p < 0.001$), but the cellularity was only moderately increased in this group compared with the other groups (p: 0.01). The statistical differences between groups in regard to vascularity, fibroblast density/continuity, and cellularity are presented in the bar graphs (►**Fig. 4**).

Discussion

The literature includes many reports of the failure of RCT repair as an unresolved surgical issue. Therefore, most studies have focused on resolving this issue and improving the healing of RCT injuries.[14] The tendon attachments of the rotator cuff have a fibrocartilage connection for absorbing shocks. However, its anatomical position imposes greater exercise activity and larger mechanical loads. Incremental shock effects can, therefore, lead to separation of the tendon from this fibrocartilage structure and result in either non-healing or difficult-to-heal injuries.[15] All scientific investigations are consequently aimed at improving the difficult-to-heal wound structure with combinations of biological supplements. For instance, hyaluronic acid therapies have been investigated by Honda et al.[16] in the repair of experimental RCTs. They found that hyaluronic treatment of rabbits with RCT repairs increased chondrocyte formation and tendon maturity, while also enhancing the biomechanical strength.[16] Similarly, Ide et al.[13] studied the effects of fibroblast growth factor (FGF) on tendon-to-bone remodelling in rats with acute injury and repair of the supraspinatus tendon. They reported higher bone insertion maturation scores in FGF-treated rats when compared with an untreated RCT group. They also found increased biomechanical strength at the second, fourth and sixth weeks when FGF treatment was combined with RCT repair.[13] Similarly, our findings support the previous literature that indicates growth factors improve the outcomes of RCT repair. Differently, our results reveal the effects of human recombinant EGF instead of FGF on RCT recovery.

Randelli et al.[17] investigated platelet rich plasma (PRP) treatment after arthroscopic treatment of human subjects with RCT and reported improved outcomes with good post-operative scores in PRP-treated RCT patients. The demonstrated beneficial effects of PRP have led to its current use as a treatment for various orthopedic disorders.[17–19] Previous studies have claimed that PRP can improve tendon healing due to an involvement of growth factors, such as platelet derived growth factor (PDGF), epidermal growth factor (EGF), vascular endothelial growth factor and transforming growth factor β (TGF-β); these factors represent the key cytokines in PRP.[19] Platelet-rich plasma is also claimed to improve the capillary regeneration required for tendon healing.[20] The vascular response at the tendon-to-bone interface during rotator cuff repairs is accepted as a main step in the healing process, and its failure is a suspected cause of the failure of RCT repairs.[21] However, one study that

 © 2022. Sociedade Brasileira de Ortopedia e Traumatologia. All rights reserved.

compared PRP treatment versus EGF treatment on tendon healing claimed that EGF gave a higher neovascularization and greater tenocyte, fibroblast, collagen, and tissue macrophage levels, and the authors concluded that EGF may be a more effective treatment than other growth factors for tendon healing.[22] In light of this previous literature, we investigated the effect of human recombinant EGF on normal RCT healing, as well as the effect on vasculogenesis during the healing process.

The role of EGF has been examined in both pathological and normal tissue healing in previous studies.[23] Epidermal growth factor was found to act as a mitogenic factor for epithelial and endothelial cells, as well as for fibroblasts, and its application increased fibronectin synthesis, angiogenesis, fibroplasia and collagenase activity.[23] The crucial effect of EGF is initiated after the formation of a hemostatic platelet plug, which is a trigger step in wound healing.[23] Basal et al.[11] reported that EGF improves bone formation and microcirculation by provoking neoangiogenesis in early-stage osteonecrosis of the femoral head. Kocyigit et al.[24] investigated the effects of EGF treatment in a rat model of Achilles tendon healing and found more extensive vascularization, greater pericyte concentrations adjacent to vessel endothelial cells, and higher adipocyte concentrations in EGF-treated rats than in a normally healed group. However, they did not detect any biomechanical strength differences between EGF-treated and non-treated groups.[24] Similarly, we found increased vascularity, greater collagen deposition, and higher fibroblastic activity in EGF-treated rabbits with RCT. However, we were unable to conduct biomechanical strength tests because the bone tendon junction is rather weak in the animal rotator cuff.

Our findings indicated that injection of human recombinant EGF to a rabbit model of experimental RCT repair seemed to improve healing even in the absence of surgical repair. The fibroblastic activity, collagen deposition, and vascularity were all increased by the EGF treatment compared with the sham treatment. To the best of our knowledge, this is the first study to show a beneficial effect of EGF treatment on unrepaired RCTs.

Limitations of Study

The main limitation of the present study is its experimental design as an animal study. The effect of EGF should, therefore, be confirmed in human subjects. Another limitation is the small sample size, as the number of animals was kept as small as possible for ethical reasons. A comprehensive histological analysis with larger sample sizes will provide a better understanding of the effects of EGF.

Conclusion

In conclusion, EGF alone was found to enhance rotator cuff healing even in the absence of repair surgery. However, EGF is even more effective when provided in combination with RCT repair and the recovery seems faster. Therefore, the combination of EGF application with rotator cuff repair could be beneficial for treatment of the RCT, as this injury has a high recurrence risk due to insufficient healing.

Authors' Contributions

Each author contributed individually and significantly to the development of this article:
A. G.: Conceptualization (lead), data curation, application of the animal experiment, and application of surgery in an animal experiment.
E. T., A. A.: Methodology, project administration, planning of the project.
S. Ç., E. A., G. A.: Histology and embryology.

Conflict of Interests

The authors have no conflict of interests to declare.

References

1 Maffulli N, Longo UG, Berton A, Loppini M, Denaro V. Biological factors in the pathogenesis of rotator cuff tears. Sports Med Arthrosc Rev 2011;19(03):194–201
2 Oh LS, Wolf BR, Hall MP, Levy BA, Marx RG. Indications for rotator cuff repair: a systematic review. Clin Orthop Relat Res 2007;455 (455):52–63
3 Chillemi C, Petrozza V, Garro L, et al. Rotator cuff re-tear or non-healing: histopathological aspects and predictive factors. Knee Surg Sports Traumatol Arthrosc 2011;19(09):1588–1596
4 Umer M, Qadir I, Azam M. Subacromial impingement syndrome. Orthop Rev (Pavia) 2012;4(02):e18
5 VanBaak K, Aerni G. Shoulder Conditions: Rotator Cuff Injuries and Bursitis. FP Essent 2020;491:11–16
6 Huang Y, He B, Wang L, et al. Bone marrow mesenchymal stem cell-derived exosomes promote rotator cuff tendon-bone healing by promoting angiogenesis and regulating M1 macrophages in rats. Stem Cell Res Ther 2020;11(01):496
7 Oliva F, Gatti S, Porcellini G, Forsyth NR, Maffulli N. Growth factors and tendon healing. Med Sport Sci 2012;57:53–64
8 Molloy T, Wang Y, Murrell G. The roles of growth factors in tendon and ligament healing. Sports Med 2003;33(05):381–394
9 Takahashi S, Nakajima M, Kobayashi M, et al. Effect of recombinant basic fibroblast growth factor (bFGF) on fibroblast-like cells from human rotator cuff tendon. Tohoku J Exp Med 2002;198(04): 207–214
10 Bidder M, Towler DA, Gelberman RH, Boyer MI. Expression of mRNA for vascular endothelial growth factor at the repair site of healing canine flexor tendon. J Orthop Res 2000;18(02): 247–252
11 Basal O, Atay T, Ciris İM, Baykal YB. Epidermal growth factor (EGF) promotes bone healing in surgically induced osteonecrosis of the femoral head (ONFH). Bosn J Basic Med Sci 2018;18(04): 352–360
12 Plate JF, Brown PJ, Walters J, et al. Advanced age diminishes tendon-to-bone healing in a rat model of rotator cuff repair. Am J Sports Med 2014;42(04):859–868
13 Ide J, Kikukawa K, Hirose J, et al. The effect of a local application of fibroblast growth factor-2 on tendon-to-bone remodeling in rats with acute injury and repair of the supraspinatus tendon. J Shoulder Elbow Surg 2009;18(03):391–398
14 Kwon J, Kim YH, Rhee SM, et al. Effects of Allogenic Dermal Fibroblasts on Rotator Cuff Healing in a Rabbit Model of Chronic Tear. Am J Sports Med 2018;46(08):1901–1908
15 Benjamin M, Toumi H, Ralphs JR, Bydder G, Best TM, Milz S. Where tendons and ligaments meet bone: attachment sites ('entheses') in relation to exercise and/or mechanical load. J Anat 2006;208 (04):471–490

 © 2022. Sociedade Brasileira de Ortopedia e Traumatologia. All rights reserved.

16 Honda H, Gotoh M, Kanazawa T, et al. Hyaluronic Acid Accelerates Tendon-to-Bone Healing After Rotator Cuff Repair. Am J Sports Med 2017;45(14):3322–3330
17 Randelli PS, Arrigoni P, Cabitza P, Volpi P, Maffulli N. Autologous platelet rich plasma for arthroscopic rotator cuff repair. A pilot study. Disabil Rehabil 2008;30(20-22): 1584–1589
18 Vilchez-Cavazos F, Millán-Alanís JM, Blázquez-Saldaña J, et al. Comparison of the Clinical Effectiveness of Single Versus Multiple Injections of Platelet-Rich Plasma in the Treatment of Knee Osteoarthritis: A Systematic Review and Meta-analysis. Orthop J Sports Med 2019;7(12):2325967119887116
19 Middleton KK, Barro V, Muller B, Terada S, Fu FH. Evaluation of the effects of platelet-rich plasma (PRP) therapy involved in the healing of sports-related soft tissue injuries. Iowa Orthop J 2012;32:150–163
20 Lindeboom JA, Mathura KR, Aartman IH, Kroon FH, Milstein DM, Ince C. Influence of the application of platelet-enriched plasma in oral mucosal wound healing. Clin Oral Implants Res 2007;18(01): 133–139
21 Pandey V, Jaap Willems W. Rotator cuff tear: A detailed update. Asia Pac J Sports Med Arthrosc Rehabil Technol 2015;2(01):1–14
22 Sarıkaya B, Yumuşak N, Yigin A, Sipahioğlu S, Yavuz Ü, Altay MA. Comparison of the effects of human recombinant epidermal growth factor and platelet-rich plasma on healing of rabbit patellar tendon. Eklem Hastalik Cerrahisi 2017;28(02):92–99
23 Hardwicke J, Schmaljohann D, Boyce D, Thomas D. Epidermal growth factor therapy and wound healing–past, present and future perspectives. Surgeon 2008;6(03):172–177
24 Kocyigit I, Huri G, Yürüker S, et al. Epidermal Growth Factor Stimulates Rabbit Achilles Tendon Histologically and Biomechanically Healing. Muscles Ligaments Tendons J 2020;10(04):589–602

 © 2022. Sociedade Brasileira de Ortopedia e Traumatologia. All rights reserved.