Article published online: 2022-07-22

Technique for Foot Reconstruction with Custom-made Calcaneal Prosthesis in Primary Malignancy – A Case Report*

Técnica de reconstrução do pé com prótese de calcâneo feita sob medida em câncer primário – Relato de caso

Aditya K.S. Gowda[1] Mohit Dhingra[1] Madhubari Vathulya[2] Rajkumar K. Seenivasagam[3]

[1] Department of Orthopedics, All India Institute of Medical Sciences, Rishikesh, Uttarakhand, India
[2] Department of Plastic Surgery, All India Institute of Medical Sciences, Rishikesh, Uttarakhand, India
[3] Department of Surgical Oncology, All India Institute of Medical Sciences, Rishikesh, Uttarakhand, India

Address for correspondence Mohit Dhingra, MS orthopedics, Associate Professor, Department of Orthopedics, All India Institute of Medical Sciences, Rishikesh, Uttarakhand, 249203, India (e-mail: modisbanu77@gmail.com).

Rev Bras Ortop

Abstract

The foot is an uncommon location for osseous tumors, comprising ~ 3% of all skeletal tumors, which occur particularly around the calcaneum. Radical surgery creates a void in the foot which adversely affects the ability to salvage it. Calcaneal replacement surgeries are not commonly performed due to factors involving instability of the prosthesis, soft-tissue defects, and resultant failure, which can occur in the postoperative period. Thus, we herein report a rare case of synovial sarcoma arising from the sheath of the tibialis posterior tendon, with secondary involvement of the calcaneus bone. Considering the previous experiences of different surgeons, a custom-made prosthesis was designed with relevant modifications.

Keywords
- bone neoplasms
- calcaneus
- prostheses and implants

Resumo

O pé é um local incomum para tumores ósseos, e compreende cerca de 3% de todos os tumores esqueléticos, em especial ao redor do calcâneo. A cirurgia radical cria um vazio no pé, o que afeta de forma negativa a capacidade de resgate do membro. As cirurgias de reconstrução do calcâneo não são comumente realizadas por causa da instabilidade da prótese, defeito de partes moles, e consequente possibilidade de insucesso pós-operatório. Assim, apresentamos aqui um caso raro de sarcoma sinovial originário da bainha do tendão tibial posterior com acometimento secundário do osso calcâneo. Considerando as experiências prévias de diferentes cirurgiões, projetamos uma prótese sob medida com modificações relevantes.

Palavras-chave
- calcâneo
- neoplasias ósseas
- próteses e implantes

* *Study conducted at the All India Institute of Medical Sciences, Rishikesh, India*

received
April 2, 2022
accepted
May 27, 2022

DOI https://doi.org/10.1055/s-0042-1753532.
ISSN 0102-3616.

© 2022. Sociedade Brasileira de Ortopedia e Traumatologia. All rights reserved.
This is an open access article published by Thieme under the terms of the Creative Commons Attribution-NonDerivative-NonCommercial-License, permitting copying and reproduction so long as the original work is given appropriate credit. Contents may not be used for commercial purposes, or adapted, remixed, transformed or built upon. (https://creativecommons.org/licenses/by-nc-nd/4.0/)

Thieme Revinter Publicações Ltda., Rua do Matoso 170, Rio de Janeiro, RJ, CEP 20270-135, Brazil

Introduction

The foot is an uncommon location for osseous tumors, comprising ~ 3% of all skeletal tumors, which occur particularly around the calcaneum.[1,2] Radical surgery for these malignant tumors involves the removal of the calcaneal bone, creating a void in the foot which adversely affects the ability to salvage it. Calcaneal replacement surgeries are not commonly performed due to factors involving instability of the prosthesis, soft-tissue defect, and resultant failure which can occur in the postoperative period.[3,4] Thus, we herein report a rare case of synovial sarcoma arising from the sheath of the tibialis posterior tendon, with secondary involvement of the calcaneus bone. Considering the previous experiences of different surgeons, a custom-made prosthesis was designed with relevant modifications.

Case Report

This case report was approved by the institutional Ethics Committee (no.139/IEC/PGM/2021), and the informed consent was obtained for the participation of the patient.

A 25-year-old man presented with a history of progressively worse pain in the right foot and difficulty in walking. Clinically, the patient had swelling on the medial aspect of the heel, which was soft to firm in consistency, with a Musculoskeletal Tumor Society (MSTS) score of 12.[5] The neurological examination was unremarkable, and the X-rays were normal, but the magnetic resonance imaging (MRI) scans showed features suggestive of soft-tissue sarcoma arising from the posterior tibialis tendon and secondarily involving the calcaneum of the right foot (►**Fig. 1**).

A biopsy was performed for the histopathological confirmation, which inferred synovial sarcoma.

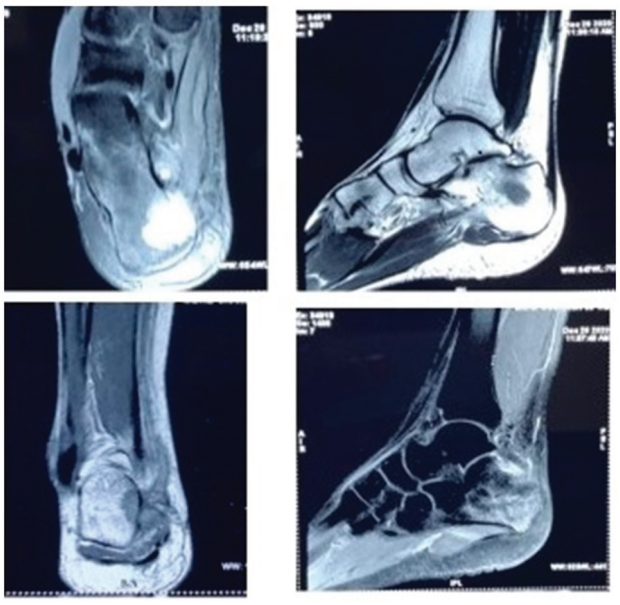

Fig. 1 Magnetic resonance imaging scan showing sarcoma of the tibialis posterior tendon with secondary involvement of the calcaneum.



Fig. 2 Transformation of DICOM files for the tridimensional reconstruction and modifications.

Planning concerning the calcaneal involvement was performed, and options for calcaneal replacement were offered to the patient. A prosthesis was made on a measure based on Files of Communication of Digital Images in Medicine (Digital Imaging and Communications in Medicine, DICOM, in English) gives computed tomography of both sides (XL Orthotics, India) (►**Fig. 2**). The modified prosthesis was coated with hydroxyapatite, covering the body, the posterior, middle and anterior facets of the calcaneum, as well as the holes of the attachment of the calcaneal tendon and plantar fascia. Two additional locking screws were planned from the calcaneum to the talus to provide stability to the construct (►**Fig. 3**).

Excision of the sarcomatous lesion was performed by extended medial incision. The lesion was involving the tibial nerve as well, so itwas excised along with the tumor tissue and calcaneal bone. The articular surface of the talus and cuboid was removed, leaving the subchondral bone exposed to be articulated with the matched surfaces of the calcaneum, which were coated with hydroxyapatite. The prosthesis of the calcaneum was then fixed by matching the facets with the corresponding facets of the talus and cuboid with the help of a locking screw. The calcaneal tendon and the plantar fascia were repaired with the help of Ethibond (Ethicon, Inc., Raritan, NJ, United States). The soft-tissue defect created was covered with a local sural flap (►**Fig. 4**). The patient was then readmitted after 3 weeks for reconstruction of the nerve gap with an interpositional sural nerve graft by anastomosing the proximal stump of the sural nerve with the distal nerve stump of plantar nerve and the distal sural nerve graft with the proximal stump of the tibial nerve to make the foot sensitive to pain (►**Fig. 5**).

Six weeks postoperatively, the patient was submitted to serial X-rays (►**Fig. 6**). The patient was then made to bear weight as per the tolerance of pain at three months. The effect of the anesthesia decreased by 50% during the follow-up period. The patient comfortably walks with support but without any instability, with an MSTS score of 21.[5]

 © 2022. Sociedade Brasileira de Ortopedia e Traumatologia. All rights reserved.



Fig. 3 Prototype of the implant and custom-made final prosthesis coated with hydroxyapatite.

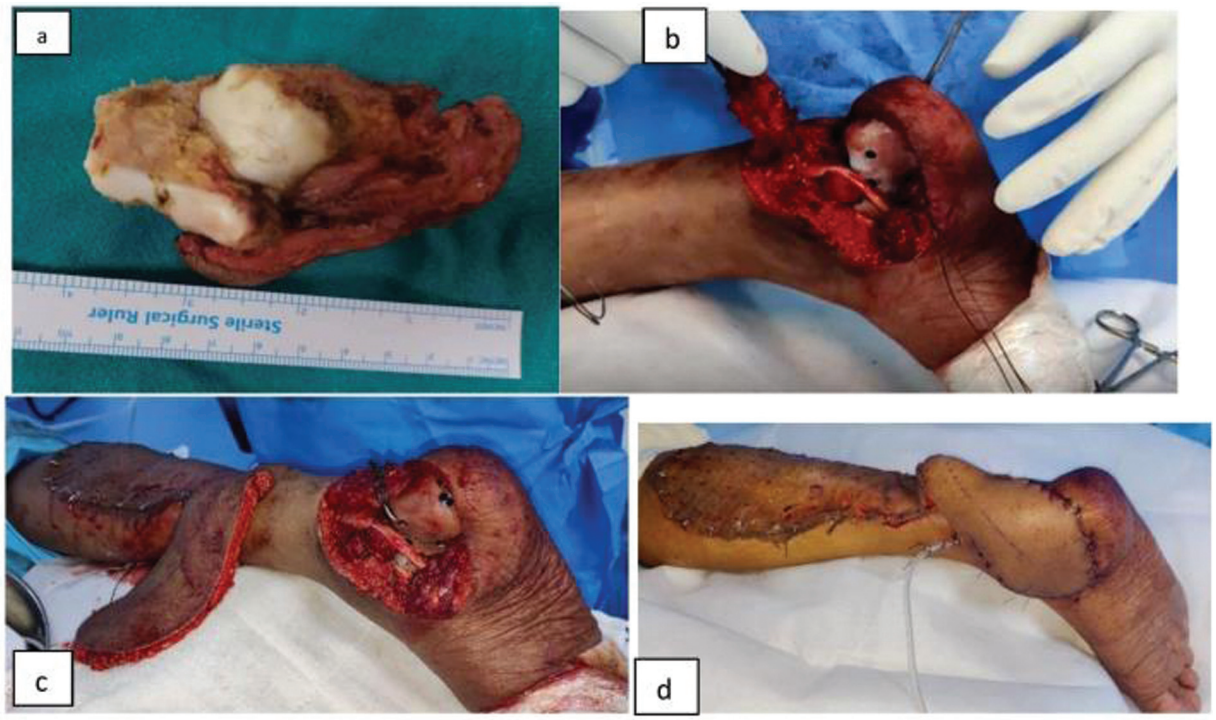

Fig. 4 (A) Resected synovial sarcoma with calcaneum; (B) reattachment of calcaneal tendon on the prosthesis; (C) implantation of calcaneum with screws and attachment of calcaneal tendon and plantar fascia; and (D) coverage of defect with sural flap.

Discussion

Limb salvage surgeries are always challenging. The challenge increases considerably when the tumor is of a rare variety and there is not much support from the industry in terms of implants and their design. Few case reports[4,6] have been published on the biological reconstruction of the resected calcaneum with the use of vascularized iliac crest and composite allograft with pedicled fibula. There are also few studies[7] in which a prosthesis has been developed for

 © 2022. Sociedade Brasileira de Ortopedia e Traumatologia. All rights reserved.

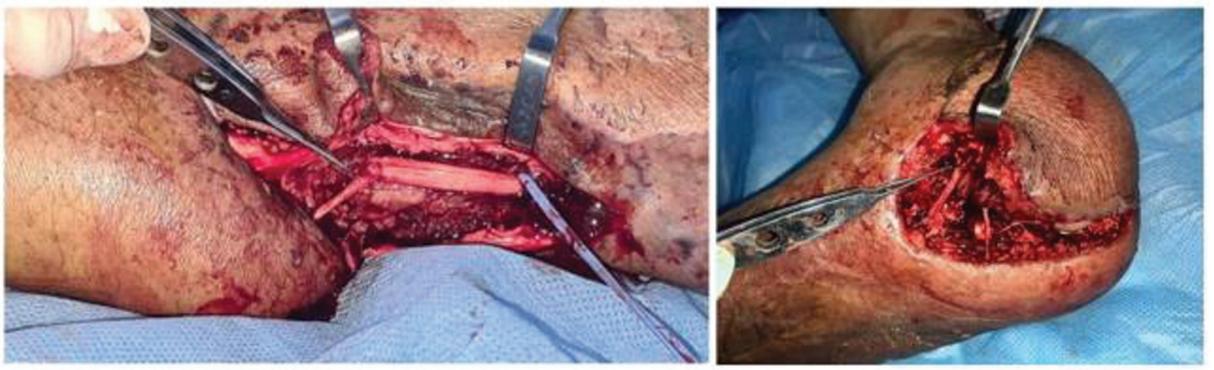

Fig. 5 Neurotization of the foot using a transfer of the sural nerve to the distal stump of the tibial nerve.



Fig. 6 (**A**) Postoperative radiograph. (**B**) Radiograph of the ankle at 3 months. (**C**) Radiograph of the ankle at 6 months. (**D,E**) Clinical picture of the patient walking with support.

the replacement of the calcaneum. Although these past experiences with allografts have yielded acceptable results, the limitation in the strength of these implanted bones is of concern, for these implants can fail on weight-bearing activities.

Most of the available literature is on primary tumors of the calcaneum, in which the soft tissue around the

 © 2022. Sociedade Brasileira de Ortopedia e Traumatologia. All rights reserved.

calcaneum is not involved, and reconstruction is possible with the available tissues.[2] The novelty of the prosthesis is represented by the fact that it was customized with the help of data available from the CT scan of the patient's foot, and consisted of a tailor-made replica of the patient's own calcaneum; secondly, we targeted the ingrowth of the subchondral bone of the talus and cuboid to provide long-term stability, so the surface of facets of the implant was coated with hydroxyapatite (in the study performed by Imanishi and Choong,[3] they made a prosthesis which was polished on the articular surfaces); thirdly, we further modified the prosthesis by placing two screw holes in the calcaneum for its fixation to the talus peri-operatively and to provide instant stability to the construct. No such information regarding any modification was available in the literature. The fourth advantage of using this prosthesis was that the anchor points for the attachment of the calcaneal tendon and plantar fascia were printed in such a way as to hold these tissues with the help of sutures passed through the holes; moreover, the hydroxyapatite coating helps incorporate the sleeve of bone, if there is any, to the implant in due time. Lastly, the prosthesis was made of titanium, so it is light and strong enough to bear the weight of the patient in the long term. In conclusion, this technique required few days, including meticulous planning, design of the implant, review of the design by the surgeon, 3D printing, and prototype manufacture.

Resection surgeries result in morbidity due to loss of soft tissue. The defect is covered with the available local flap. Moreover, reconstruction of the sensory supply to the foot was regained by neurotization surgery, which involved anastomosis of the proximal stump of the sural nerve to the distal stump of the posterior tibial nerve. To date, the recovery observed is satisfactory. This type of modification may provide a benchmark to carry out further studies on reconstruction prosthesis to make them more stable and durable.

Financial Support
The authors declare they have received no financial support for the research, authorship, and/or publication of the present article.

Conflict of Interests
The authors have no conflict of interests to declare.

Authors' Contributions
Each author contributed individually and significantly to the development of the present article: AKS G – assisted in the surgery, wrote the draft of the case report, and performed the literature search. MD – planned and performed the surgery, edited the draft, and helped to analyze the results and in the discussion. MV – planned and performed the surgery, and reviewed the case report. RKS – planned and performed the surgery, reviewed the case report.

References

1 Malawer MM, Sugarbaker PH. Musculoskeletal cancer surgery: treatment of sarcomas and allied diseases. Dordrecht, The Netherlands: Springer Science & Business Media; 2001
2 Yan L, Zong J, Chu J, et al. Primary tumours of the calcaneus. Oncol Lett 2018;15(06):8901–8914
3 Imanishi J, Choong PFM. Three-dimensional printed calcaneal prosthesis following total calcanectomy. Int J Surg Case Rep 2015; 10:83–87
4 Kurvin LA, Volkering C, Kessler SB. Calcaneus replacement after total calcanectomy via vascularized pelvis bone. Foot Ankle Surg 2008;14(04):221–224
5 Muscolo DL, Ayerza MA, Aponte-Tinao LA. Long-term results of allograft replacement after total calcanectomy. A report of two cases. J Bone Joint Surg Am 2000;82(01):109–112
6 Chou LB, Malawer MM. Osteosarcoma of the calcaneus treated with prosthetic replacement with twelve years of followup: a case report. Foot Ankle Int 2007;28(07):841–844
7 Wilson TJ. Novel Uses of Nerve Transfers. Neurotherapeutics 2019;16(01):26–35

 © 2022. Sociedade Brasileira de Ortopedia e Traumatologia. All rights reserved.