Article published online: 2022-07-22

The Effectiveness of Periarticular Anesthetic Infiltration in Postoperative Analgesia of Total Hip Arthroplasty*

A eficácia da infiltração periarticular anestésica na analgesia pós-operatória de artroplastia total do quadril

Rafael Wei Min Leal Chang[1] Juscimar Carneiro Nunes[2,3] Bruno Bellaguarda Batista[1] Thiago Couto Valle Bomfim de Borborema[1]

[1] Orthopedics and Traumatology Service, Hospital Universitário Getúlio Vargas (HUGV), Universidade Federal do Amazonas (UFAM), Manaus, AM, Brazil
[2] Faculdade de Medicina (UFAM) and Universidade do Estado do Amazonas, Manaus, AM, Brazil
[3] Hospital Universitário Getúlio Vargas (HUGV), Universidade Federal do Amazonas (UFAM), Manaus, AM, Brazil

Address for correspondence Rafael Wei Min Leal Chang, R. Tomas de Vila Nova, 4, Nossa Sra. das Graças, Manaus, AM 69020-170, Brazil (e-mail: rafchang@gmail.com).

Rev Bras Ortop

Abstract

Objective The present study aims to evaluate the effectiveness of the periarticular hip infiltration technique in the postoperative period of total hip arthroplasty.

Methods This is a randomized double-blind controlled clinical trial in patients with femoral neck fractures or hip osteoarthritis submitted to a total hip arthroplasty at our institution. The periarticular infiltration technique consisted of the administration of an anesthetic (levobupivacaine) and a steroid (dexamethasone) agent in the nociceptor-rich tissues of the hip after orthopedic implants placement. The control group received an injection of 0.9% saline into the same tissues. Pain, range of motion, and use of opioid analgesic agents after 24 and 48 hours of the procedure were evaluated, as well as the presence of adverse effects, time to resume walking, and total hospitalization time.

Results The study evaluated 34 patients. The experimental group required fewer opioid agents between 24 and 48 hours. The reduction in pain scores was greater in the placebo group.

Conclusion Periarticular anesthetic infiltration as a method of postoperative analgesia for total hip arthroplasty reduced the rates of opioid intake between 24 and 48 hours. It provided no benefits regarding pain, mobility, length of stay, or complications.

Keywords
- arthroplasty, replacement, hip
- injections, intra-articular
- analgesia
- rehabilitation

* *Study developed at Hospital Universitário Getúlio Vargas (HUGV), Universidade Federal do Amazonas (UFAM), Manaus, AM, Brazil.*

received
September 8, 2021
accepted
January 20, 2022

DOI https://doi.org/10.1055/s-0042-1744294.
ISSN 0102-3616.

© 2022. Sociedade Brasileira de Ortopedia e Traumatologia. All rights reserved.
This is an open access article published by Thieme under the terms of the Creative Commons Attribution-NonDerivative-NonCommercial-License, permitting copying and reproduction so long as the original work is given appropriate credit. Contents may not be used for commercial purposes, or adapted, remixed, transformed or built upon. (https://creativecommons.org/licenses/by-nc-nd/4.0/)

Thieme Revinter Publicações Ltda., Rua do Matoso 170, Rio de Janeiro, RJ, CEP 20270-135, Brazil

Resumo

Objetivo Este estudo tem como objetivo avaliar a eficácia da técnica de infiltração periarticular do quadril no pós-operatório de artroplastia total do quadril.

Métodos Estudo clínico randomizado duplo-cego controlado. O estudo foi realizado nos pacientes com fratura de colo femoral ou osteoartrose de quadril, submetidos ao procedimento cirúrgico de artroplastia total do quadril em nossa instituição. A técnica de infiltração periarticular consistiu na aplicação da combinação de um anestésico (levobupivacaína) com um corticosteroide (dexametasona) nos tecidos ricos em nociceptores do quadril, após a colocação dos implantes ortopédicos. No grupo controle, foi realizada infiltração de soro fisiológico 0,9% nos mesmos tecidos. Após 24 e 48 horas do procedimento, foram avaliados os quesitos de dor, amplitude de movimentos, uso de analgésicos opióides, presença de efeitos adversos, período do início da deambulação e o tempo total de hospitalização.

Resultados Trinta e quatro pacientes foram estatisticamente avaliados no estudo. Foi observada uma redução no consumo de opioides entre 24 e 48 h no grupo experimental. Uma redução maior da pontuação de dor foi observada no grupo placebo.

Conclusão A infiltração periarticular anestésica como método de analgesia pós-operatória de artroplastia total do quadril, neste estudo, reduziu as taxas de consumo de opioides quando comparamos a evolução entre 24 e 48h. Não houve benefícios quanto às taxas de dor, mobilidade, tempo de internação ou intercorrências com este método.

Palavras-chave

- artroplastia de quadril
- injeções intra-articulares
- analgesia
- reabilitação

Introduction

Total hip arthroplasty (THA) consists of the surgical treatment of patients with advanced coxarthrosis, chronic pain, significant functional limitation, and no improvement under conservative treatment.[1] Total hip arthroplasty improves pain, quality of life, and psychosocial features of these subjects.[2]

In addition, THA is the treatment of choice for displaced femoral neck fractures in patients over 60 years old who are active, healthy, and have a good life expectancy.[3]

Nevertheless, many patients present moderate-to-severe pain after the procedure, resulting in prolonged hospitalization and increased postoperative complications.[4] An ideal postoperative THA analgesia regimen should preserve early knee and hip mobility, allow early physical therapy, accelerate recovery, shorten hospital stay, reduce the risk of postoperative complications, and increase patient satisfaction.[5]

Kerr and Kohan[6] developed the local infiltration analgesia (LIA) technique in 2008. Local infiltration analgesia consists of the intraoperative intra-articular injection of a mixture of ropivacaine, ketorolac, and epinephrine for postoperative analgesia with lower rates of side effects or complications compared with other analgesic techniques.[7–12]

However, many studies observed no significant difference between groups, and there is still controversy whether periarticular infiltration provides greater analgesia and early recovery after THA.[13–15]

The technical details of periarticular infiltration vary significantly among surgeons, with little standardization. Nociceptor location in the hip determines the preferred infiltration site. The concentration of these receptors is higher at the labral base and the central round ligament (along with vascular structures). In addition, they occur diffusely, in moderate concentrations, at the joint capsule.[16,17]

There are many analgesia modalities for the postoperative period of THA, including epidural analgesia, opioid administration, and peripheral nerve blocks. Although widely used, each technique has local and systemic side effects: epidural analgesia may result in pruritus and spinal cord ischemia; opioids can cause nausea, emetic episodes, respiratory depression, and urinary retention; and peripheral blocks may lead to neurovascular injury. In addition, a greater intensity of joint pain on the date of surgery is a risk factor for chronic opioid use. Among THA patients, 4.3% of those who had never used opioids before and 34.7% of those who used them continued to take them 6 months after surgery.[18]

Methodology

This is a primary, experimental, quantitative (analytical), randomized double-blind controlled clinical study in patients with femoral neck fracture or hip osteoarthrosis who underwent a total hip arthroplasty at our institution. This study used the non-probabilistic convenience sampling method. A software-based permuted randomization process assigned patients to their groups. The exclusion criteria were scheduled surgical reintervention procedures in a previously operated hip and impossibility to undergo spinal anesthesia.

Selected patients underwent spinal anesthesia. The experimental group received a postoperative periarticular infiltration with levobupivacaine (0.75% concentration, 20 mL volume) and dexamethasone (4 mg/mL, 2.5 mL vial,

 © 2022. Sociedade Brasileira de Ortopedia e Traumatologia. All rights reserved.

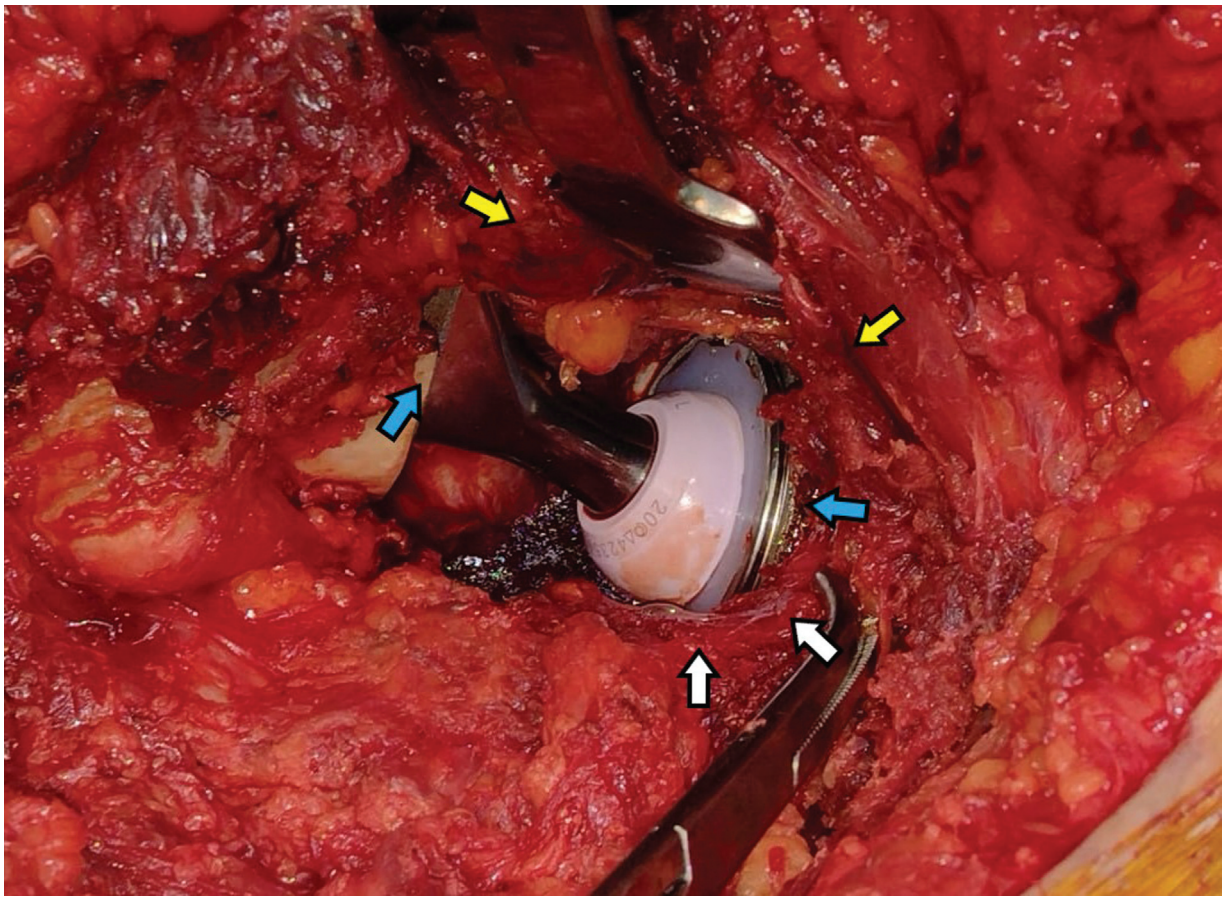

Fig. 1 Infiltration sites at the hip after prosthesis placement—joint capsule and external rotators (white arrows), periarticular gluteal muscles (yellow arrows), and periosteum adjacent to the femoral and acetabular implants (blue arrows).

totaling 10 mg) diluted in a saline solution (in a total volume of approximately 60 mL). This solution was applied after implant placement in the remaining hip joint capsule (post-capsulorrhaphy), the external rotators (after suturing them), the periarticular gluteal musculature, and the periosteum adjacent to the implants. The control group (placebo) received an infiltration of the same volume of 0.9% saline solution in the same tissues (►**Figure 1**).

Results

This study included 35 patients diagnosed with femoral neck fracture or hip osteoarthritis from October 2018 to December 2020 who underwent total hip arthroplasty. One patient developed hemodynamic complications and was excluded from the study because the assessment was not possible.

The evaluation included pain (visual analog scale [VAS]), hip range of motion, analgesic agent intake, length of hospitalization, ability to walk, and postoperative complications.

Data analysis used the statistical software Statistica version 7.0 (StatSoft, Tulsa, OK, USA). The established significance level was 5%.

The patients ages ranged from 44 to 82 years old, with a mean age of 64.15. There was no statistically significant difference between groups regarding age ($p = 0.29$).

There was no statistically significant difference between groups regarding surgical indication ($p = 0.45$). The main indication for both groups was coxarthrosis (►**Table 1**).

The experimental group presented a significant change in opioids intake between 24 and 48 hours. A significant number of patients no longer needed opioids after 48 hours (►**Table 2**).

The placebo group showed no significant change between the 24- and 48-hour period (►**Table 3**).

There was a significant difference between the groups regarding pain ($p = 0.033$). The placebo group presented a greater reduction in pain scores when comparing patients at 24 and 48 hours.

There was no significant difference between groups regarding range of motion, including flexion ($p = 0.81$),

Table 1 Indication

	Group		
Indication	Placebo	Experimental	Total
Coxarthrosis	11	13	24
%	64.71%	76.47%	
Neck fracture	6	4	10
%	35.29%	23.53%	
Total	17	17	34

 © 2022. Sociedade Brasileira de Ortopedia e Traumatologia. All rights reserved.

Table 2 Opioids use by each group in 24 and 48 hours

Placebo	48 hours			Experimental	48 hours		
24 hours	No	Yes	Total	24 hours	No	Yes	Total
No	5	0	5	No	6	0	6
%	62.50%	0.00%		%	50.00%	0.00%	
Yes	3	9	12	Yes	6	5	11
%	37.50%	100.00%		%	50.00%	100.00%	
Total	8	9	17	Total	12	5	17
P	0.0248			*P*	0.041		

Table 3 Pain in each group at 24 and 48 hours

Group	Mean	n	Standard deviation	Minimum value	Maximum value
Placebo	−2.80	15	1.93	−6	1
Experimental	−1.35	17	1.22	−3	2
Total	−2.03	32	1.73	−6	2

adduction ($p = 0.84$), abduction ($p = 0.61$), internal ($p = 0.18$) or external rotation ($p = 0.54$).

There was also no statistically significant difference between groups regarding time to resume walking ($p = 0.68$), length of hospitalization ($p = 0.45$), or postoperative complications ($p = 0.24$).

Discussion

There is little standardization regarding the therapeutic regimens for periarticular infiltration in the literature. Multiple studies have compared different drug combinations but with no precise definition of the ideal mixture. The analysis of the pharmacology of these agents should help the optimal choice and allow surgeons to use what they prefer.[19]

Infiltration in the soft tissues around the hip joint, including the joint capsule, direct and reflex heads of the rectus femoris, tensor fascia lata, and subcutaneous tissue, shows good results in postoperative analgesia.[20] The literature also describes infiltration in external rotators and gluteus, as well as the posterior capsule and gluteus medius attachment site, but with no satisfactory outcomes.[21]

In this study, although there was a higher temporal reduction (from 24–48 hours) of pain scores in the placebo group (compared to the experimental group), opioid intake decreased significantly only in the experimental group between 24 and 48 hours.

There were no differences in hip mobility between groups, including the range of motion in all analyzed planes. The length of hospitalization, early mobility (beginning to walk), or complication rates presented no significant differences.

Conclusion

Periarticular anesthetic infiltration as a method of postoperative analgesia for total hip arthroplasty reduced the rates of opioid intake from 24 to 48 hours. There were no benefits regarding pain, mobility, length of stay, or complications with this method.

Financial Support
There was no financial support from public, commercial, or non-profit sources.

Conflict of Interests
The authors have no conflict of interests to declare.

References

1 James WH, John RCJ. Arthroplasty of the hip. In: Azar FM, Beaty JH, Canale ST. Campbell's operative orthopaedics. 13th ed. Philadelphia: Elsevier; 2017:188–389
2 Balik MS, Hocaoğlu Ç, Erkut A, Güvercin Y, Keskin D. Evaluation of the Quality of Life and Psychiatric Symptoms of Patients with Primary Coxarthrosis after Total Hip Arthroplasty. Acta Chir Orthop Traumatol Cech 2017;84(06):436–440
3 Rogmark C, Leonardsson O. Hip arthroplasty for the treatment of displaced fractures of the femoral neck in elderly patients. Bone Joint J 2016;98-B(03):291–297
4 Jiang J, Teng Y, Fan Z, Khan MS, Cui Z, Xia Y. The efficacy of periarticular multimodal drug injection for postoperative pain management in total knee or hip arthroplasty. J Arthroplasty 2013;28(10):1882–1887
5 Wang Y, Gao F, Sun W, Wang B, Guo W, Li Z. The efficacy of periarticular drug infiltration for postoperative pain after total hip arthroplasty: A systematic review and meta-analysis. Medicine (Baltimore) 2017;96(12):e6401
6 Kerr DR, Kohan L. Local infiltration analgesia: a technique for the control of acute postoperative pain following knee and hip surgery: a case study of 325 patients. Acta Orthop 2008;79(02): 174–183
7 Andersen KV, Nikolajsen L, Daugaard H, Andersen NT, Haraldsted V, Søballe K. Local infiltration analgesia is not improved by postoperative intra-articular bolus injections for pain after total hip arthroplasty. Acta Orthop 2015;86(06): 647–653

 © 2022. Sociedade Brasileira de Ortopedia e Traumatologia. All rights reserved.

8 Chen DW, Hu CC, Chang YH, Lee MS, Chang CJ, Hsieh PH. Intra-articular bupivacaine reduces postoperative pain and meperidine use after total hip arthroplasty: a randomized, double-blind study. J Arthroplasty 2014;29(12):2457–2461
9 Kuchálik J, Granath B, Ljunggren A, Magnuson A, Lundin A, Gupta A. Postoperative pain relief after total hip arthroplasty: a randomized, double-blind comparison between intrathecal morphine and local infiltration analgesia. Br J Anaesth 2013;111 (05):793–799
10 Lunn TH, Husted H, Solgaard S, et al. Intraoperative local infiltration analgesia for early analgesia after total hip arthroplasty: a randomized, double-blind, placebo-controlled trial. Reg Anesth Pain Med 2011;36(05):424–429
11 Marques EM, Jones HE, Elvers KT, Pyke M, Blom AW, Beswick AD. Local anaesthetic infiltration for peri-operative pain control in total hip and knee replacement: systematic review and meta-analyses of short- and long-term effectiveness. BMC Musculoskelet Disord 2014;15:220
12 Pandazi A, Kanellopoulos I, Kalimeris K, et al. Periarticular infiltration for pain relief after total hip arthroplasty: a comparison with epidural and PCA analgesia. Arch Orthop Trauma Surg 2013; 133(11):1607–1612
13 Andersen LØ, Kehlet H. Analgesic efficacy of local infiltration analgesia in hip and knee arthroplasty: a systematic review. Br J Anaesth 2014;113(03):360–374
14 Dobie I, Bennett D, Spence DJ, Murray JM, Beverland DE. Periarticular local anesthesia does not improve pain or mobility after THA. Clin Orthop Relat Res 2012;470(07):1958–1965
15 Hofstad JK, Winther SB, Rian T, Foss OA, Husby OS, Wik TS. Perioperative local infiltration anesthesia with ropivacaine has no effect on postoperative pain after total hip arthroplasty. Acta Orthop 2015;86(06):654–658
16 Ross JA, Greenwood AC, Sasser P 3rd, Jiranek WA. Periarticular Injections in Knee and Hip Arthroplasty: Where and What to Inject. J Arthroplasty 2017;32(9S):S77–S80
17 Simons MJ, Amin NH, Cushner FD, Scuderi GR. Characterization of the Neural Anatomy in the Hip Joint to Optimize Periarticular Regional Anesthesia in Total Hip Arthroplasty. J Surg Orthop Adv 2015;24(04):221–224
18 Goesling J, Moser SE, Zaidi B, et al. Trends and predictors of opioid use after total knee and total hip arthroplasty. Pain 2016;157(06): 1259–1265
19 Fahs AM, Koueiter DM, Kurdziel MD, Huynh KA, Perry CR, Verner JJ. Psoas Compartment Block vs Periarticular Local Anesthetic Infiltration for Pain Management After Anterior Total Hip Arthroplasty: A Prospective, Randomized Study. J Arthroplasty 2018;33 (07):2192–2196
20 Ranjitkar S, Prakash R, Chookkalingam S, Prakash D. Periarticular injection of analgesia in primary total hip replacement: a prospective randomised single blind study. Nepal Med Coll J 2016;18 (1–2):32–36
21 Jules-Elysee KM, Goon AK, Westrich GH, et al. Patient-controlled epidural analgesia or multimodal pain regimen with periarticular injection after total hip arthroplasty: a randomized, double-blind, placebo-controlled study. J Bone Joint Surg Am 2015;97(10): 789–798

 © 2022. Sociedade Brasileira de Ortopedia e Traumatologia. All rights reserved.