Article published online: 2022-08-01

THIEME OPEN ACCESS

Technical Note

A Novel Method of Treatment of Small Osteolabral Avulsions Associated with Posterior Fracture Dislocation of the Hip

Um novo método de tratamento de pequenas avulsões osteolabrais associadas à luxação-fratura posterior do quadril

Sandeep Gupta[1] Rajeev Kansay[2] Anmol Sharma[1] Naveen Mittal[2]

[1] Department of Orthopaedics, Fortis Hospital, Mohali, Punjab, India
[2] Department of Orthopaedics, Govt Medical College and Hospital, Chandigarh, India

Address for correspondence Anmol Sharma, Department of Orthopaedics, Fortis Hospital, Mohali, Punjab, India (e-mail: Anmolsharma13@gmail.com).

Rev Bras Ortop

Abstract

Small osteolabral avulsions of the hip can be easily missed, and postreduction stress testing and a computed tomography (CT) scan of the hip should be done to look for these injuries. The usual modality of treatment of these unstable osteolabral avulsions is suture anchors, Herbert screws or spring plates. But when the bony avulsion is small, the use of these implants becomes a tedious job. We present a novel technique of fixing small osteochondral avulsion fractures not amenable to fixation using screws or spring plates.

A retrospective analysis of 57 cases who underwent open reduction and internal fixation for posterior fracture dislocation of the acetabulum was performed and 6 cases that had a posterior labral small osteochondral fragment leading to instability were identified. These injuries were fixed using a novel method. The mean Harris Hip Score at the final follow-up was 92.5. Fixation of osteochondral avulsions associated with posterior hip fracture dislocation can be a difficult task if the bony fragment is small. Our technique is a simple, cost-effective, and reliable way of fixing such avulsions with satisfactory outcomes.

Keywords

- acetabulum
- fracture, bone
- femoral head
- hip dislocation

Resumo

Pequenas avulsões osteolabrais do quadril podem ser não ser percebidas e, por isso, testes de estresse pós-redução e tomografia computadorizada (TC) do quadril devem ser realizados para sua detecção. O tratamento destas avulsões osteolabrais instáveis é geralmente feito com âncoras de sutura, parafusos de Herbert ou placas em mola (*spring plates*). Contudo, em avulsões ósseas pequenas, o uso destes implantes é um

The present work was developed at the Govt Medical College and Hospital, Chandigarh, India

received
December 28, 2021
accepted after revision
February 18, 2022

DOI https://doi.org/10.1055/s-0042-1750714.
ISSN 0102-3616.

© 2022. Sociedade Brasileira de Ortopedia e Traumatologia. All rights reserved.
This is an open access article published by Thieme under the terms of the Creative Commons Attribution-NonDerivative-NonCommercial-License, permitting copying and reproduction so long as the original work is given appropriate credit. Contents may not be used for commercial purposes, or adapted, remixed, transformed or built upon. (https://creativecommons.org/licenses/by-nc-nd/4.0/)

Thieme Revinter Publicações Ltda., Rua do Matoso 170, Rio de Janeiro, RJ, CEP 20270-135, Brazil

trabalho tedioso. Apresentamos uma nova técnica de fixação de pequenas fraturas com avulsões osteocondrais não passíveis de fixação com parafusos ou placas em mola. Uma análise retrospectiva de 57 casos submetidos a redução aberta e fixação interna de fratura-luxação posterior do acetábulo identificou 6 casos nos quais um pequeno fragmento osteocondral labral posterior causava instabilidade. Estas lesões foram corrigidas com um novo método. O valor médio do Harris Hip Score no último acompanhamento foi de 92,5. A fixação de avulsões osteocondrais associadas à luxação-fratura posterior do quadril pode ser difícil se o fragmento ósseo for pequeno. Nossa técnica é uma maneira simples, econômica e confiável de corrigir tais avulsões com resultados satisfatórios.

Palavras-chave
- acetábulo
- cabeça do fêmur
- fraturas ósseas
- luxação do quadril

Introduction

Post-traumatic posterior hip dislocation is usually caused by high-energy trauma in young individuals involved in road traffic accidents (RTAs). The mechanism of injury is usually a dashboard injury in which there is an axially directed force from the knee in a flexed hip and, depending on the magnitude of force and position of the hip at the time of injury, several other associated injuries can occur, such as osteochondral avulsion, posterior wall fracture, and transverse fracture with posterior wall involvement.[1] Reduction of hip dislocation should be done on an emergency basis within 12 hours to decrease the risk of avascular necrosis of the hip. Nonconcentric reduction or persistent instability after reduction are usually caused by intra-articular loose bodies, an incarcerated fragment, or posterior osteolabral avulsion.[2] Addressing these injuries is of paramount importance to achieve a stable and concentric reduction to decrease the risk of subsequent redislocation of the hip, osteoarthritis, and avascular necrosis (AVN) of the hip and allow early mobilization. Small osteolabral avulsions can be easily missed, and postreduction stress testing and computed tomography (CT) scan of the hip should be done to look for these injuries.[3] The usual modality of treatment of these unstable osteolabral avulsions is suture anchors, Herbert screws, or spring plates.[4] But when the bony avuslion is small, the use of these implants becomes a tedious job. We present a novel technique of fixing small osteochondral avuslion fractures not amenable to fixation using screws or spring plates.

Method

Our study was a retrospective analysis of 57 cases who underwent open reduction and internal fixation for posterior fracture dislocation of acetabulum by a single surgeon at a tertiary level trauma center in north India from 2012 to 2018. Approval was obtained from the ethical committee of the institution and informed written consents were obtained from all patients for inclusion in the study and publishing of data in a scientific journal without any disclosure of personal details.

Six cases with a small posterior labral osteochondral fragment leading to instability were identified and were fixed using a novel method. All 6 patients were male, with a mean age of 36.1 years old (range 21–54 years old), and the right side was involved in 5 out of 6 patients. The mechanism of injury in all six patients was RTA and all of them had a concurrent posterior dislocation at the time of injury. Three patients had a transverse acetabular fracture with associated posterior osteolabral fracture and the other three had only osteochondral fragments associated with posterior dislocation. In the latter three patients, posterior dislocation was reduced in the emergency department under sedation, but they had persistent dynamic instability. So, they were planned for surgery and dynamic instability was confirmed by stress testing in the operation theatre under C-arm in obturator view of the hip. The patients with an associated transverse fracture were planned for open reduction according to the criteria of Matta [5] and the osteochondral fragment was addressed when persistent posterior instability was noted after fixing the transverse fracture.

All patients were operated using the Kocher Langenbeck approach. Surgical dislocation of the hip was not performed in any case. Trochanteric flip osteotomy was performed in two transverse fractures and in one posterior wall injury. The osteochondral fragments were so small in all these cases that they could not be fixed using routine methods such as screw or spring plate (►**Figures 1** and **2**). The fragments were



Fig. 1 Anteroposterior view of the preoperative X ray of the left hip of a patient with small osteochondral avulsion of the posterior wall after reduction of hip dislocation.

 © 2022. Sociedade Brasileira de Ortopedia e Traumatologia. All rights reserved.

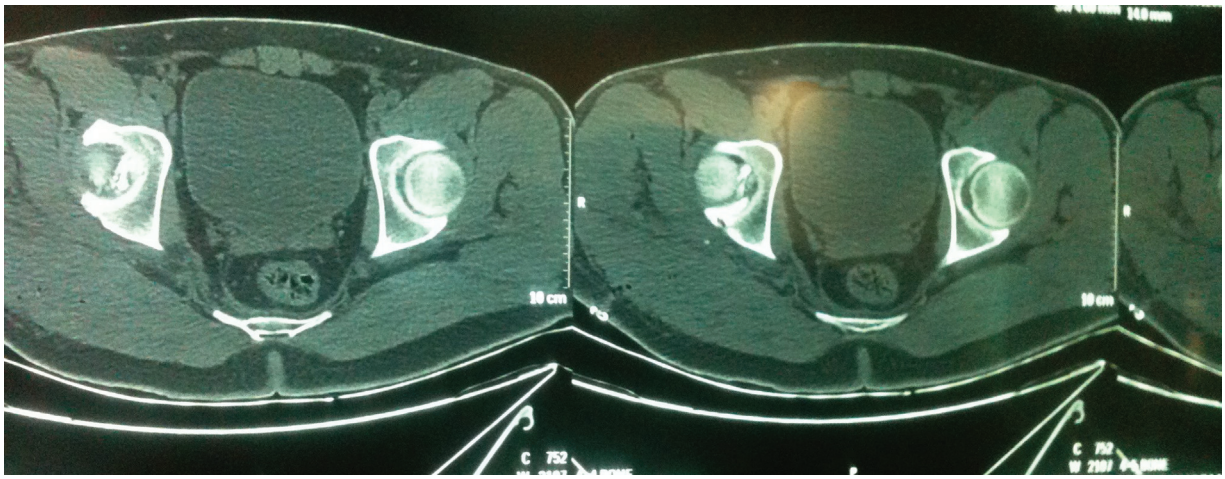

Fig. 2 Postreduction axial images from the preoperative computed tomography scan of the affected hip.

stabilized using Kirschner wires with the lateral ends bent over the retroacetabular area and a buttress plate (3.5 mm reconstruction plate) was applied over the bent and cut hair pin loop of the Kirschner wires to secure the fixation (►**Figure 3**). Intraoperative movements were assessed immediately after fixation and the concentricity of the reduction was checked under imaging after dynamic stress testing in all views. All six hips were stable and reduced while the osteochondral fragments were also securely fixed throughout the complete range of motion of the hip.

Isometric quadriceps strengthening exercises were started immediately postoperatively. The patients were kept on toe-touch weight bearing mobilization with a walker frame for $\sim$ 4 weeks followed by a gradual increase in weight bearing according to the tolerance of the patient at $\sim$ 8 to 10 weeks after surgery, depending on the degree of radiographic consolidation of the fracture. The clinical outcome was evaluated using the Harris Hip Score at 6 weeks, 3 months, 6 months, 1 year, and at final follow-up. The quality of articular reduction and joint congruency was evaluated by postoperative plain radiographs using the Matta classification (anatomic/imperfect/poor)[5] and supplemented with 3-D CT scans. The radiological evaluation at the final follow-up was performed based on the criteria of Matta[5]: Excellent (a normal appearing hip joint); good (mild changes with minimal sclerosis and joint narrowing $<$ 1 mm); fair (intermediate changes with moderate sclerosis and joint narrowing $<$ 50%); and poor (advanced osteoarthritis changes). All patients were followed-up for a minimum of 2 years (mean 44 weeks; range: 24–66 weeks). There were no surgical site infections, sciatic nerve injuries, loss of reduction, or nonunion at the trochanteric osteotomy site**.** All acetabular fractures were united at the final follow-up and the mean time to union was 6.4 months (range: 4–10 months). The mean Harris Hip Score at the final follow-up was 92.5 (range: 90.4–95.8). No patient developed features suggestive of AVN hip. The radiological outcome at the final follow-up was deemed excellent in four and good in two patients.

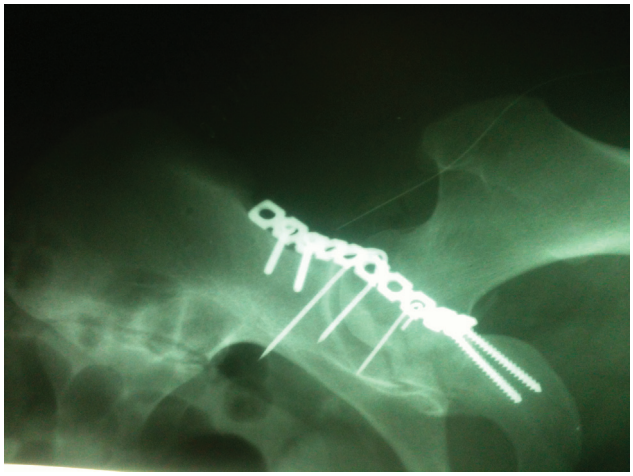

Fig. 3 Immediate anteroposterior view of the postoperative X ray of the hip of the same patient.

Final Comments

Posterior dislocation of the hip with associated wall fracture is a common injury in high energy RTAs. Persistent instability after reduction of the dislocation or fixation of the fracture should divert the attention of the orthopedist to look for any posterior osteolabral tears. Identification of a small acetabular 'fleck sign' in an X ray of the hip in oblique view near the posterior wall in the absence of any major acetabular fracture is a marker of posterior labral avuslion and should be assessed thoroughly by stress testing under imaging to look for any dynamic instabilities.[6] The choice of method of fixation in avulsions with small bony fragments remains arguable due to the fragment being not amenable to fixation with anchors, screws, or plates and lack of stability when fixed with Kirschner wires alone. In the present study, we described a novel technique of fixing these small osteochondral labral injuries using Kirschner wires and buttress plates over the bent wire ends. The buttress plates increased the stability of the Kirscnher wire fixation and prevented pullout of the wires. The hips remained stable after fixation on dynamic stress testing in the operation theatre under

 © 2022. Sociedade Brasileira de Ortopedia e Traumatologia. All rights reserved.

imaging and at all follow-ups. Our technique is a simple, cost-effective, and reliable way of fixing such avulsions with satisfactory outcomes.

Contributions of the Authors

All authors contributed to the study conception and design. Material preparation, data collection and analysis were performed by Sharma A., Gupta S., and Kansay R. The first draft of the manuscript was written by Sharma A. and all authors commented on previous versions of the manuscript. All authors read and approved the final manuscript.

Financial Support

The present research did not receive any specific grant from funding agencies in the public, commercial, or not-for-profit sectors.

Conflict of Interests

The authors have no conflict of interests to declare.

References

1 Judet R, Judet J, Letournel E. Fractures of the acetabulum: classification and surgical approaches for open reduction. preliminary report. J Bone Joint Surg Am 1964;46:1615–1646
2 Brooks RA, Ribbans WJ. Diagnosis and imaging studies of traumatic hip dislocations in the adult. Clin Orthop Relat Res 2000;(377):15–23
3 Price CT, Pyevich MT, Knapp DR, Phillips JH, Hawker JJ. Traumatic hip dislocation with spontaneous incomplete reduction: a diagnostic trap. J Orthop Trauma 2002;16(10):730–735
4 Park MS, Yoon SJ, Choi SM. Hip Arthroscopic Management for Femoral Head Fractures and Posterior Acetabular Wall Fractures (Pipkin Type IV). Arthrosc Tech 2013;2(03):e221–e225
5 Matta JM. Fractures of the acetabulum: accuracy of reduction and clinical results in patients managed operatively within three weeks after the injury. J Bone Joint Surg Am 1996;78(11):1632–1645
6 Blanchard C, Kushare I, Boyles A, Mundy A, Beebe AC, Klingele KE. Traumatic, Posterior Pediatric Hip Dislocations With Associated Posterior Labrum Osteochondral Avulsion: Recognizing the Acetabular "Fleck" Sign. J Pediatr Orthop 2016;36(06):602–607

 © 2022. Sociedade Brasileira de Ortopedia e Traumatologia. All rights reserved.