Article published online: 2022-09-26

Early Intraprosthetic Dislocation of Total Hip Arthroplasty with Double Mobility Implant: Case Report*

Luxação intraprotética precoce de artroplastia total do quadril com implante de dupla mobilidade: Relato de caso

Thiago Lopes Lima[1,2] Alexandre de Bustamante Pallottino[1] José Sérgio Franco[3,4] Sávio Manhães Chami[1] Breno Jorge Scorza[1] Brunno Benedetti de Morais[1]

[1] Casa de Saúde São José, Rio de Janeiro, RJ, Brazil
[2] Orthopedics and Traumatology Service Prof. Nova Monteiro, Miguel Couto Municipal Hospital, Rio de Janeiro (RJ), Brazil
[3] Department of Orthopedics and Traumatology, Faculdade de Medicina, Universidade Federal do Rio de Janeiro, Rio de Janeiro, RJ, Brazil
[4] Orthopedics Service, Casa de Saúde São José, Rio de Janeiro, RJ, Brazil

Address for correspondence Thiago Lopes Lima, MD, Rua Visconde de Silva, 33/406, Botafogo, 22271-091, Rio de Janeiro, RJ, Brazil (e-mail: agolima@hotmail.com).

Rev Bras Ortop

Abstract

Total hip arthroplasty (THA) is a successful surgery in the treatment of hip pain, but there are potential complications, of which dislocation is one of the most common. Dislocation management is a challenging problem that requires a multimodal approach, and the use of dual mobility implants is an option. We present a patient with a history of femoral neck fracture who underwent THA with a double mobility implant. On the 18th postoperative day, after a fall to the ground, she developed prosthesis dislocation and had a complication after closed reduction, a subsequent intraprosthetic dislocation. After a radiographic diagnosis, the patient presented mechanical signs of hip flexion caused by a disassociated double mobility implant. The revision surgery was indicated, but the patient chose not to perform the necessary surgical procedure. A careful postoperative study of the radiographs revealed an eccentric femoral head and evidence of disassociated implantation in the surrounding soft tissues. Radiographs after closed reduction of intraprosthetic dislocations should be examined thoroughly.

Keywords
- hip
- arthroplasty, replacement, hip
- hip dislocation
- periprosthetic fractures

* *Work developed at the Orthopedics Service of Casa de Saúde São José, Rio de Janeiro, RJ, Brazil.*

received
October 23, 2020
accepted after revision
December 1, 2020

DOI https://doi.org/10.1055/s-0041-1726068.
ISSN 0102-3616.

© 2022. Sociedade Brasileira de Ortopedia e Traumatologia. All rights reserved.
This is an open access article published by Thieme under the terms of the Creative Commons Attribution-NonDerivative-NonCommercial-License, permitting copying and reproduction so long as the original work is given appropriate credit. Contents may not be used for commercial purposes, or adapted, remixed, transformed or built upon. (https://creativecommons.org/licenses/by-nc-nd/4.0/)

Thieme Revinter Publicações Ltda., Rua do Matoso 170, Rio de Janeiro, RJ, CEP 20270-135, Brazil

Resumo

A artroplastia total do quadril (ATQ) é uma cirurgia bem-sucedida no tratamento da dor no quadril, mas existem complicações potenciais, das quais a luxação é uma das mais comuns. O gerenciamento das luxações é um problema desafiador que requer uma abordagem multimodal, e o uso de implantes de mobilidade dupla é uma opção. Apresentamos uma paciente com história de fratura do colo do fêmur que foi submetida a ATQ com um implante de dupla mobilidade. No 18° dia pós-operatório, após queda ao solo, a paciente evoluiu com luxação da prótese e teve uma complicação após redução fechada, uma luxação intraprotética subsequente. Após um diagnóstico radiográfico, a paciente apresentou sinais mecânicos na flexão do quadril causados por um implante de mobilidade dupla desassociado. A cirurgia de revisão foi indicada, mas a paciente optou por não realizar o procedimento cirúrgico necessário. O estudo pós-operatório cuidadoso das radiografias revelou uma cabeça femoral excêntrica e evidências do implante desassociado nos tecidos moles circundantes. As radiografias após a redução fechada das luxações intraprotéticas devem ser examinadas minunciosamente.

Palavras-chave

- quadril
- artroplastia de quadril
- luxação do quadril
- fraturas periprotéticas

Introduction

Instability is one of the most feared complications of hip arthroplasty, corresponding from between 0.2 and 7% of primary arthroplasties to 25% in review cases.[1]

In the 1970s, Giles Bousquet, aiming to reduce this index, developed the concept of double mobility. This consists of two joints, a larger one between the polyethylene liner and the metal acetabular cupula, and the other, smaller, between the femoral head and the polyethylene liner, increasing the radius between the head and the neck and the distance to impact between the neck and the acetabular edge, reducing dislocation rates in this type of prosthesis.[2]

In this implant, early intraprosthetic dislocation (dissociation between the femoral head and polyethylene) is extremely rare, with few cases described. The causes of early intraprosthetic dislocation are inadequate assembly of components and dislocation or forced reduction. Other causes are the extrinsic blockage of polyethylene coating or polyethylene wear (debris would compromise the coupling of the two bearings), which occurs years after the procedure, not being common in early dislocation.[3]

Radiographic recognition of intraprosthetic dislocation after reduction may be difficult, because the head of the femoral component may be located within the metallic acetabular cup, while the polyethylene component is displaced. Radiographic signs of an intraprosthetic dislocation include eccentricity of the femoral head inside the metallic acetabulum and the presence of a "bubble sign" on post-reduction radiography, representing polyethylene.[4] Immediate recognition is essential for planning open reduction and exchange of polyethylene liner.

Case Report

Female patient, 85 years old, with a history of fall to the ground. She was treated in the emergency room with hip pain, shortening and external rotation in the left lower limb. The radiographic examination revealed the diagnosis of fracture of the neck of the left femur, AO 31B1.1 (►**Figure 1a-b**).

The patient underwent total arthroplasty of the left hip with double mobility implant (Medacta). A 48/28 double mobility polyethylene liner, size 1 uncemented femoral stem, a 28 mm metallic femoral head, and a 48 mm non-cemented acetabular dome were used. Posterolateral access was performed with capsular repair and short rotators.

The choice of the double mobility prosthesis occurred due to risk factors for instability: age $>$ 75 years, flexibility, hypermobility, active life, female gender.[5]

The polyethylene liner was properly coupled to the metal head with specific material and tested before being deployed. Stability tests and intraoperative control radiographs were performed, confirming good implant positioning and hip stability (►**Figure 2a-b**).

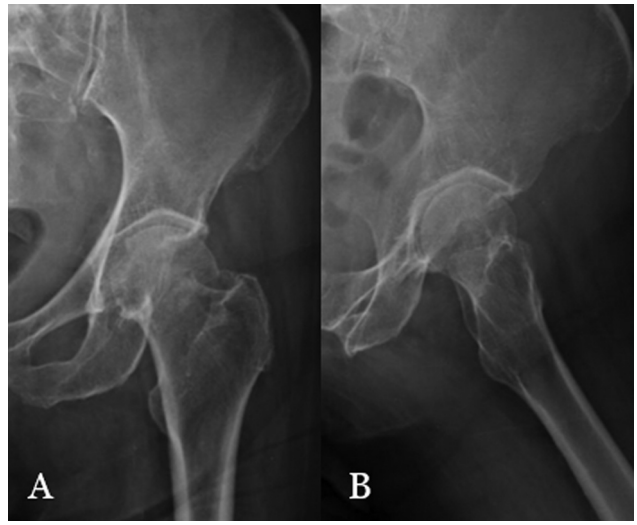

Fig. 1 Fracture of the neck of the left femur impacted in valgus, in AP (A) and profile (B).

 © 2022. Sociedade Brasileira de Ortopedia e Traumatologia. All rights reserved.

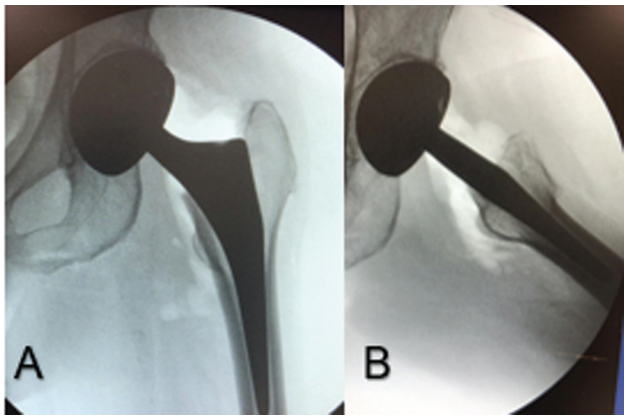

Fig. 2 Radiographic control in the immediate postoperative period showing reduction of components and concentricity of the metallic head (A) in AP and profile (B).

On the 18th postoperative day, after a fall to the ground, the patient was treated in the emergency room, complaining of pain in her left hip. Radiographs of the hip showed upper posterior dislocation of the prosthesis (►**Figure 3**).

The closed reduction was performed with sedation (propofol), using the reduction maneuver of Allis apud Waddell et al.[6] and radiographic control. She returned to the outpatient clinic on the 7th day after reduction in good general



Fig. 4 X-ray 7 days after reduction. The larger arrow shows the "bubble sign", the polyethylene displaced in the soft parts. The smaller arrows show the eccentricity of the metal head in the acetabular dome.



Fig. 3 Panoramic radiography of the basin showing posterosuperior dislocation of the left hip prosthesis.

condition, without functional limitation, complaining only of crackling in the posterior region of the left hip. Radiographs after reduction show congruence between the femoral head and the acetabular dome, but femoral head eccentricity is observed in the acetabular metallic dome (►**Figure 4**). A superolateral circular opacity (bubble sign) is also observed. Computed tomography (CT) reveals a polyethylene component in the posterosuperior aspect of the hip (►**Figure 5**).

The patient underwent outpatient follow-up. She can perform all daily activities without functional limitation. The only complaint was polyethylene crackling which improved with ~ 60 days. She did not present other episodes of dislocation. Due to the absence of symptoms and high surgical risk (chronic renal failure and severe heart disease), both the patient and the responsible physician chose not to perform revision surgery.

Discussion

In our case, the patient presented complications after a single attempt at closed reduction, in which the maneuver strength resulted in intraprosthetic displacement of the polyethylene. This complication occurs when the polyethylene coating fits into the edge of the acetabular component, and the subsequent traction of the limb results in the dissociation of the

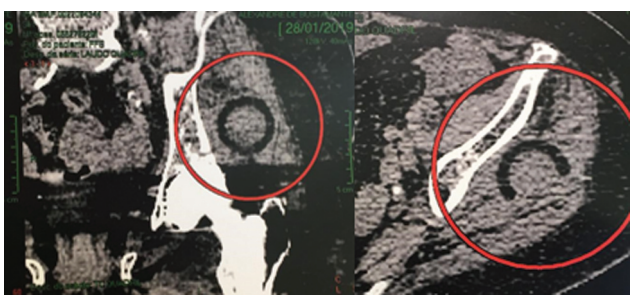

Fig. 5 (A) Coronal section of computed tomography. The red circle shows polyethylene component in soft tissues, (B) In the axial cut, a red circle evidencing polyethylene.

 © 2022. Sociedade Brasileira de Ortopedia e Traumatologia. All rights reserved.

metal head from the polyethylene coating, similar to a "bottle opener" effect, and polyethylene can migrate out of the acetabulum.

Intraprosthetic dislocation can be a diagnostic challenge, especially in postreduction radiographs, because the femoral head can give the false impression of being reduced in the dome.

When evaluating a dislocation after hip arthroplasty, it is necessary to differentiate a conventional prosthesis from a double mobility implant. The presence of crackling or noise associated with the request of the motion arc is a sign of direct contact between the head and the acetabular dome. The x-ray should be made with close attention to the eccentricity of the head in the acetabular component. The possible presence of an opaque radio halo in the periarticular region ("bubble sign"), which may represent dislocated polyethylene, should also be observed.

The reduction in these patients should be performed with general anesthesia or subarachnoid block, in order to facilitate it. The maneuver should be performed carefully and without axial traction to avoid or attenuate the "bottle opener" effect. Instead of applying direct axial traction, internal rotation should be coupled to axial traction, allowing the polyethylene coating to move away from the acetabulum, avoiding the collision of the acetabular component. Fluoroscopic imaging should be used to guide the reduction maneuver. Postreduction radiographs should be carefully evaluated for femoral head eccentricity and the presence of a bubble sign. Intraprosthetic dislocation requires surgical intervention, and anesthesia should be used for open reduction and eventual component replacement. Computed tomography may be requested in case of doubt. The suggestion would be to place a metallic marker on the polyethylene that would facilitate its detection on radiographs.

With the popularization of dual mobility prostheses in our country, training and information of orthopedists are needed in the emergency room for this possible complication that is easy to be neglected. The examining physician should question and know how to identify the implant model and evaluate the signs of this complication: femoral head eccentricity in the acetabular dome, "soft tissue bubble sign", crackling or deformity on joint palpation after reduction.

Financial Support
The present survey has not received any specific funding from public, commercial, or not-for-profit funding agencies.

Conflict of Interests
The authors have no conflict of interests to declare.

References

1 Patel PD, Potts A, Froimson MI. The dislocating hip arthroplasty: prevention and treatment. J Arthroplasty 2007;22(04, Suppl 1):86–90
2 McArthur BA, Nam D, Cross MB, Westrich GH, Sculco TP. Dual-mobility acetabular components in total hip arthroplasty. Am J Orthop 2013;42(10):473–478
3 Philippot R, Adam P, Farizon F, Fessy MH, Bousquet G. [Survival of cementless dual mobility sockets: ten-year follow-up]. Rev Chir Orthop Repar Appar Mot 2006;92(04):326–331
4 De Martino I, Triantafyllopoulos GK, Sculco PK, Sculco TP. Dual mobility cups in total hip arthroplasty. World J Orthop 2014;5 (03):180–187
5 Kaiser D, Kamath AF, Zingg P, Dora C. Double mobility cup total hip arthroplasty in patients at high risk for dislocation: a single-center analysis. Arch Orthop Trauma Surg 2015;135(12):1755–1762
6 Waddell BS, Mohamed S, Glomset JT, Meyer MS. A Detailed Review of Hip Reduction Maneuvers: A Focus on Physician Safety and Introduction of the Waddell Technique. Orthop Rev (Pavia) 2016;8(01):6253

 © 2022. Sociedade Brasileira de Ortopedia e Traumatologia. All rights reserved.