Article published online: 2022-09-28

A Rare Case of a Schwannoma on the Foot – Case Report

Um caso raro de um Schwannoma no pé – Relato de caso

José Carlos Sousa Miradouro[1] Tiago Costa[1] Nuno Silva[1] João Afonso[1]

[1] Centro Hospitalar do Tâmega e Sousa, Porto, Portugal

Rev Bras Ortop

Address for correspondence José Carlos Sousa Miradouro, Centro Hospitalar do Tâmega e Sousa, Porto, Portugal (e-mail: ze.mota17@gmail.com).

Abstract

A Schwannoma is an infrequent lesion. This tumor derives from the myelin sheath of the peripheral nerves; in most cases, it is benign and rarely presents in the foot and ankle region. Patients affected by this type of pathology are usually asymptomatic. Still, they sometimes have sensory or motor neurologic symptoms if the tumor is large enough to cause direct or indirect compression of the affected nerve. A 55-year-old male patient presented to our department with non-traumatic swelling and pain in the lateral aspect of the right foot and leg. A magnetic resonance imaging (MRI) scan of the right leg revealed a well-circumscribed lesion, measuring 2,5 by 1 cm, showing hypointensity on T1 sequences and hyperintensity on T2, compatible with a superficial peroneal nerve sheath cells tumor. Surgical excision of the lesion was performed, and the histopathological examination confirmed the initial suspicion—Schwannoma of the superficial peroneal nerve. The postoperative period was uneventful, with progressive improvement of pain and complete functional recovery without neurological deficits. Rigorous clinical examination associated to MRI scans allow adequate diagnosis as well as the exclusion of other pathologies with similar clinical presentation. Thus, the surgeon has to be aware of all the data for an effective diagnosis and treatment in this type of rare pathology that cannot be neglected.

Keywords

- schwannoma
- foot
- nerve sheath neoplasms
- peroneal nerve

Resumo

Um schwannoma é uma lesão pouco frequente, sendo um tumor que deriva da bainha de mielina dos nervos periféricos; na maioria dos casos, este tumor é benigno e raramente se apresenta na região do pé e tornozelo. Os pacientes afetados por esse tipo de patologia são geralmente assintomáticos. Ainda assim, às vezes eles têm sintomas neurológicos sensoriais ou motores se o tumor for grande o suficiente para causar a compressão direta ou indireta do nervo afetado. Um paciente do gênero masculino de 55 anos se apresentou ao nosso departamento com inchaço não

This work was conducted in the Centro Hospitalar do Tâmega e Sousa, Porto, Portugal.

received
March 16, 2022
accepted
July 7, 2022

DOI https://doi.org/10.1055/s-0042-1756150.
ISSN 0102-3616.

© 2022. Sociedade Brasileira de Ortopedia e Traumatologia. All rights reserved.
This is an open access article published by Thieme under the terms of the Creative Commons Attribution-NonDerivative-NonCommercial-License, permitting copying and reproduction so long as the original work is given appropriate credit. Contents may not be used for commercial purposes, or adapted, remixed, transformed or built upon. (https://creativecommons.org/licenses/by-nc-nd/4.0/)

Thieme Revinter Publicações Ltda., Rua do Matoso 170, Rio de Janeiro, RJ, CEP 20270-135, Brazil

traumático e dor no aspecto lateral do pé direito e da perna. A ressonância magnética (RM) da perna direita revelou uma lesão bem-circunscrita, medindo 2,5 por 1 cm, mostrando hipointensidade nas sequências T1 e hiperintensidade em T2, compatível com um tumor superficial de células do nervo peronal. Foi realizada excisão cirúrgica da lesão e o exame histopatológico confirmou a suspeita inicial – Schwannoma do nervo peroneal superficial. O pós-operatório foi tranquilo, com melhora progressiva da dor e recuperação funcional completa sem déficits neurológicos. Exame clínico rigoroso associado aos exames de RM permitem diagnóstico adequado, bem como a exclusão de outras patologias com apresentação clínica semelhante. Assim, o cirurgião tem que estar atento a todos os dados para um diagnóstico e tratamento eficazes nesse tipo de patologia rara que não pode ser negligenciada.

Palavras-chave
- schwanoma
- pé
- neoplasias da bainha neural
- nervo fibular

Introduction

Schwannomas are an infrequent lesion. This tumor derives from the myelin sheath of the peripheral nerves; in most cases, it is benign. It occurs mostly among patients between the third and fifth decades of life, and has a homogeneous distribution between females and males, as well as among different ethnicities.[1]

It is a soft tissue tumor that is rarely located in the foot and ankle, preferentially located in anatomical regions such as the head, neck, trunk, and upper limbs.[2] Patients affected by this type of pathology are, in the vast majority of cases, asymptomatic. Still, there may sometimes be sensory or motor neurologic symptoms if the tumor is large enough to cause direct or indirect compression of the affected nerve.[3]

Case Presentation

A 55-year-old male patient presented to us with a complaint of 2 months of mild pain located on the lateral aspect of the right foot and ankle, in the absence of associated trauma. Clinical examination revealed a firm mass with approximately 3 by 1 cm, on the lateral and distal surface of the right leg, with positive Tinel's sign on percussion and no neurological deficits.

Magnetic resonance imaging (MRI) scan of the right leg revealed a well-circumscribed lesion, measuring 2,5 by 1 cm, showing hypointensity on T1 sequences (►**Fig. 1**) and hyperintensity on T2 (►**Fig. 2**), compatible with a superficial peroneal nerve sheath cells tumor.

Afterwards, surgical excision of the lesion was conducted using the enucleation technique, with an anterolateral approach, exposing the tumor, followed by a perineural dissection and tumoral detachment of the nerve sheath (►**Fig. 3**). After further inspection at the end of the procedure, we concluded that the tumor was removed properly and without compromising the structure of the closest vessels and nerves.

The excised tumor was sent for a histological study which confirmed the initial suspicion—Schwannoma of the superficial peroneal nerve. Hematoxylin and eosin stain revealed the characteristic hypercellular (Antoni A) and hypocellular (Antoni B) regions of the specimen.

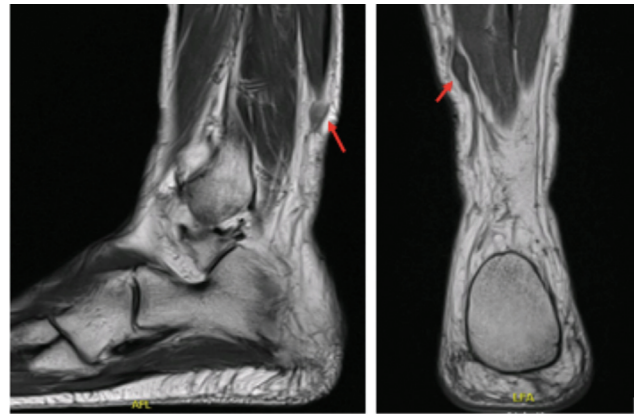

Fig. 1 Magnetic resonance imaging (MRI) scan revealed hypointensity on T1.

The postoperative period was uneventful, with progressive improvement of pain and complete functional recovery, without neurological deficits.

We currently have a 24-month follow-up, and the patient has no major complaints.

Discussion

Peripheral nerve sheath tumors, such as Schwannomas, are infrequent in the anatomical region of the foot and ankle, accounting for approximately 4 to 10% of all soft tissue tumors in this region, depending on the series.[4,5]

The authors present an unusual case of a Schwannoma affecting the lower limb. There are very sparse case reports of this tumor of the superficial peroneal nerve described in literature. Schwannomas are typically benign and indolent, and are often diagnosed incidentally due to its asymptomatic presentation. However, in a few cases it can cause localized pain and paresthesia due to compression of the surrounding nerves. Evolution to malignancy is rare, but it is of paramount importance to distinguish Schwannoma from a malignant peripheral nerve sheath tumor, though it is not always easy. The use of MRI can help to better characterize these tumors, showing hyperintense signals on T2-weighted images and isointense signals on T1-weighted images.[6,7]

 © 2022. Sociedade Brasileira de Ortopedia e Traumatologia. All rights reserved.

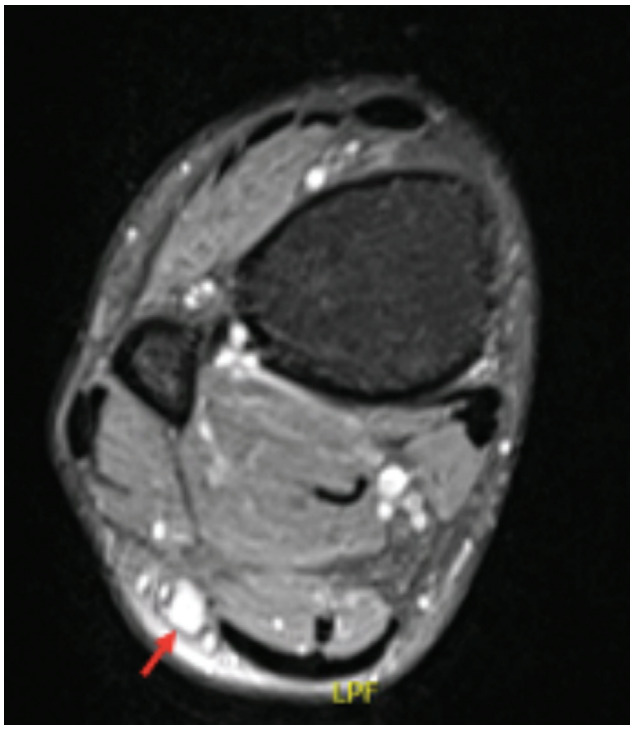

Fig. 2 Magnetic resonance imaging (MRI) scan revealed hypeintensity on T2.

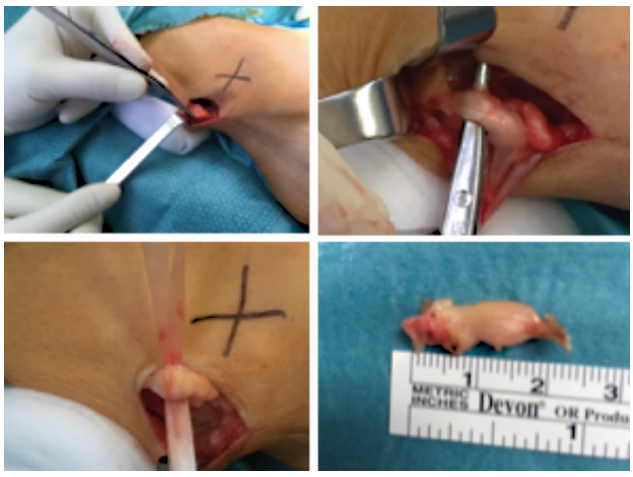

Fig. 3 Excised tumor.

Clinical examination, MRI, and surgical excision with histological evaluation can confirm the diagnosis, as well as exclude the presence of a malignant tumor. In a series by Carvajal et al., these methods allowed for accurate diagnosis in 14% of the cases.[4]

Schwannomas are well encapsulated, eventually causing displacement of nerve fascicles. For that reason, it is generally believed that enucleation from the nerve can be approached without producing neurological deficits.[8]

Surgical excision or enucleation is the gold standard when it comes to treatment, though, for smaller tumors, watchful waiting can be an option. Extreme care is vital regarding tumor dissection of the associated nerves to preserve or restore nerve function to the maximum level. Recurrence is extremely rare (less than 1%) unless tumor tissue is removed improperly.[5,8,9]

Given that the symptoms in this type of lesion are often mild or may not even exist, the delay in diagnosis is frequent in cases of lower limb schwannoma, and there are even reports of cases where it took approximately 15 years to get the proper diagnosis. Therefore, rigorous clinical examination, associated with MRI scans and histological evaluation, allow for adequate diagnosis and the exclusion of other pathologies with similar clinical presentation.[10]

Thus, the surgeon has to be aware of all the data for an effective diagnosis and treatment in this type of rare pathology that cannot be neglected.

Conflict of Interests

The authors have no conflict of interests to declare.

Financial Support

This study received no financial support from public, commercial or non-profit sources.

References

1 Merritt G IV, Ramil M, Oxios A, Rushing C. Schwannoma of the plantarmedial aspect of the foot: A case report. Foot 2019; 39:85–87
2 Knight DM, Birch R, Pringle J. Benign solitary schwannomas: a review of 234 cases. J Bone Joint Surg Br 2007;89(03):382–387
3 Angelini A, Bevoni R, Biz C, Cerchiaro MC, Girolami M, Ruggieri P. Schwannoma of the foot: report of four cases and literature review. Acta Biomed 2019;90(1-S):214–220
4 Carvajal JA, Cuartas E, Qadir R, Levi AD, Temple HT. Peripheral nerve sheath tumors of the foot and ankle. [published correction appears in Foot Ankle Int 2011;32(4):vi]Foot Ankle Int 2011;32 (02):163–167
5 Hao X, Levine D, Yim J, et al. Schwannoma of Foot and Ankle: Seven Case Reports and Literature Review. Anticancer Res 2019; 39(09):5185–5194
6 Pace S, Sacks MA, Minasian T, Hashmi A, Khan FA. Paraspinal plexiform schwannoma of unknown nerve origin: A case report. Int J Surg Case Rep 2021;79:267–270
7 Tiwari V, Dwidmuthe S, Meshram N. A Solitary Benign Schwannoma of the Medial Dorsal Cutaneous Nerve of the Foot Masquerading as a Ganglion Cyst. Cureus 2021;13(07):e16141
8 Kim SM, Seo SW, Lee JY, Sung KS. Surgical outcome of schwannomas arising from major peripheral nerves in the lower limb. Int Orthop 2012;36(08):1721–1725
9 Galbiatti JA, Milhomens GRDS, Bertozzo LG, Escames L, Milhomens Neto PA, Galbiatti MGP. Retrospective Analysis of 20 Patients Affected by Schwannomas in the Upper and Lower Limbs. Rev Bras Ortop 2020;55(05):629–636
10 Gupta PK, Acharya A, Panda SS. Rare Presentation of Schwannoma in the Ankle: A Case Report. Rev Bras Ortop 2021;56(01): 118–120

 © 2022. Sociedade Brasileira de Ortopedia e Traumatologia. All rights reserved.