OSTEOSYNTHESIS WITH INTRAMEDULLARY NAILS IN CHILDREN

Helio Jorge Alvachian Fernandes[1], Eduardo Abdalla Saad[2], Fernando Baldy dos Reis[3]

ABSTRACT

The authors present a comprehensive review of the literature emphasizing the use of flexible intramedullary nails in the treatment of fractures in children, focusing the treatment of femoral shaft and forearm fractures and emphasizing the importance of the non-surgical approach. Children's age and weight threshold are not well defined for the use of the method. The removal of implants is a controversial matter in the literature, with a trend towards keeping the implants.

Keywords – *Child; Fracture fixation/methods; Fracture fixation, Intramedullary Fracture fixation, Internal; Internal fixators; Orthopedic fixation devices; Titanium; Stainless steel.*

INTRODUCTION

Elastic intramedullary nails have been used in recent years as a method of treatment of some fractures in children. Currently, the demands of the modern world lead us to consider the difficulties of non-surgical treatment while keeping children in plaster casts. Parents work, home care is difficult, time away from school, and even issues of patient comfort are considered. Therefore, fractures, which a few years ago were treated with a bloodless approach, are treated surgically. Fractures whose treatment is performed with flexible intramedullary nails are the main indications for intramedullary nails, especially in the femoral shaft and the forearm bones; there is still controversy in the literature regarding their use in the humerus and tibia. The objective of this review is to present the current aspects regarding the use of intramedullary nails for diaphyseal fractures in children.

Consolidation and elastic intramedullary nails

The elastic intramedullary nails stabilize fractures from a distance, they do not directly address the fracture focus and allow early mobilization, decrease the time of hospitalization and allow for a faster return to school activities. The principle of treatment is relative stability. Consolidation is secondary, since the stabilization allows for small movements in the fracture region, combined with the anatomical features of children who present a thick periosteum and high osteogenic power. The stability obtained allows for painless joint mobility without compromising reduction.

Treatment principles

The flexible intramedullary nails act as tutors when they are pre-tensioned and made with three support points, providing greater stability to fractures[1,2].

STEEL OR TITANIUM NAILS?

Flexible intramedullary nails are available in both steel and titanium alloys. The choice involves the surgeon's preference and the availability of material, as well as the physical characteristics of the alloy. Comparative clinical studies show parity between them, with similar results[3]. In Brazil, Soni *et al*.[4]

1 – Associate Professor; Head, Trauma and Emergency Service, Division of Traumatology, Department of Orthopedics and Traumatology, EPM/UNIFESP.
2 – Physician; Assistant Physician, Division of Pediatric Orthopedics, Department of Orthopedics and Traumatology, EPM/UNIFESP.
3 – Lecturer; Head, Division of Traumatology, Department of Orthopedics and Traumatology, EPM/UNIFESP.

Correspondence: Rua Borges Lagoa, 783, 5º. and. – São Paulo, SP. E-mail: hfernandes.dot@epm.br

We declare no conflict of interest in this article

presented a two-dimensional computer model, simulating a fracture of the femur in children treated with flexible steel and titanium nails, comparatively assessing the stress distribution. They concluded that the biomechanical behavior was qualitatively better in the model with titanium nails. In the quantitative analysis restricted to regions of the fracture focus, the values were statistically similar. In the study of deformation, they observed more homogeneous biomechanical behavior in the model with titanium nails.

Several authors have reported similarities between the flexible steel and titanium nails, both in in vitro experiments and in clinical outcomes[5-13]. Steel has a lower modulus of elasticity, while titanium has elastic characteristics that are closer to bone, with better quality of pre-tensioning. Therefore, where greater strength is required, such as fractures in children at the end of growth, fractures where the medullary canal is narrower, extensive soft tissue injury, or in obese children, elastic steel nails have a better indication. In patients with fractures where pre-tensioning and elasticity of the implant are needed most, such as those of the distal femur, intramedullary titanium nails can be indicated.

In Brazil, Saad[14] showed clinical outcomes comparable to those found in the literature using flexible steel nails in the treatment of femoral shaft fractures in children.

Indications for elastic nails

Currently, elastic nails are used in fractures in children over five years of age, mainly in the femoral shaft[15-22] and the shaft of the forearm bones[23-26].

Preoperative planning

Anteroposterior and profile radiographs are very important to the analysis of fractures. In general, when using two flexible intramedullary nails, it is estimated that each nail should have a maximum caliber of 40% of the diameter of the narrowest portion of the fractured medullary canal[27]. In practice, the diameter of the nails is calculated to be about a third of the smaller diameter of the medullary canal, in general, the isthmus region in both incidences. These details are important, especially in femoral shaft fractures, because the nails need to curve within the medullary canal. When two nails are used, they should have the same caliber[27], with the sum of the diameter about 1 to 2 mm smaller than the diameter of the isthmus. The length of the nails is measured by the distance between the growth plates in the proximal and distal ends. The curvature of the nails, the maximum of the curve, about 40°, must match the level of the fracture in its convex portion.

We prefer the common radiolucent operating table, because it allows for reduction maneuvers to be performed more freely, for verifying the mobility of the hip, and for more easily controlling any rotational deviations.

Surgical technique for femoral fractures
(Figure 1)

The patient is positioned on a common radiolucent operating table. The fracture is reduced by gentle manipulation, if possible, with radioscopic control. The diameter of the nails is selected based on preoperative planning, and is confirmed in the affected limb before its insertion.

The essential requirement is the exact pre-tensioning of the nails, so that the apex of the curve of the nail is at the fracture site. The second nail with the same diameter is prepared to create a diametrically opposed curve at the fracture site. The diameter of the nail should be similar for steel and titanium nails and about a third of the inner diameter of the isthmus of the medullary canal. There are authors who use steel nails with a diameter 1 mm smaller than the titanium. In our experience this was not observed[14].

The distance between the proximal and distal growth plates is measured, considering a 1-2 cm margin of safety between the implant, the physis and the pre-tensioning. We attempted to leave the maximum curvature at the level of the fracture to create a tension that would be the second fulcrum of the nail. In general, the local insertion will be in the bone metaphysis. Radioscopic control is performed during the insertion of the nails. The nail selected is introduced gently in the metaphysis with the tip angled away from the cortex.

Transverse diaphyseal fractures and short oblique shaft fractures in long bones are those with the

best indication for the method, but the indications have been expanded considerably with time and experience of the surgeon.

The treatment of femoral shaft fractures in children varies with age[1,28]. However, in children over five years of age, several authors have recommended surgical treatment with flexible intramedullary nails, considering its superiority compared to treatment with plaster casts in regards to healing time, return to school activities, and complications[15-22].

The upper age limit is more difficult to determine. Recent studies have shown increased angulation at the fracture site after the use of elastic intramedullary nails, especially in older and heavier children[11]. However, there is no ideal alternative. The risk of avascular necrosis of the femoral head from the insertion of a rigid intramedullary nail in adolescents has been well described[28]. In most cases, it is possible to allow early mobilization for partial weight-bearing support with or without complementary immobilization, depending on the weight, size of the child, and the reduction achieved[29].

The results from the age of five to 14 years are clinically satisfactory[5-13]. The hospital stay is shorter, with consolidation occurring in about eight to 10 weeks[14]. Nonunion or delayed union are uncommon and when they occur, it seems to be related to the inappropriate use of surgical techniques. Complications are limited to the skin or discomfort at the site of nail insertion[1,5]. Changes in bone length due to growth disturbances appear to be minimal, with an average of overgrowth of the femur of about 1.2 mm[12]. Classically, removal of the implants is recommended in four to six months, depending on the clinical and radiographic evolution. However, some authors question the need for removal in the absence of symptoms[6,7].



Figure 1 – A: Radiographic image of a femoral shaft fracture in a 10-year-old child. B: Radiographic image of the fracture, after employing the flexible nails.

Fractures of the distal femur

The stabilization of fractures with flexible intramedullary nails can be performed antegrade, using the lateral region of the femur 2 cm below the small trochanter as the entry point. It is believed that in very distal fractures, antegrade nails would be better indicated[27].

Postoperative period

Mobilization and early mobilization with partial weight-bearing are recommended by most authors[30-40], but some recommend full weight-bearing immediately, depending upon the stability obtained[14].

Tibial fractures (Figure2)

The enlargement of the proximal end and the triangular cross-section make it difficult to place nails symmetrically and to obtain adequate stabilization. The non-surgical treatment of fractures of the tibia with a plaster cast allows for better comfort, mobility, and locomotion, indicating that non-surgical treatment is the treatment of choice. Indications are restricted to special situations such as extensive soft tissue injury, multiple trauma, nonoperative treatment failures, and surgeon preference.



Figure 2 – Radiographic image of a consolidated tibial shaft fracture treated with flexible intramedullary nails.

UPPER LIMBS

Humerus

In children, most *Humeral shaft fractures* can be treated conservatively and do not require surgical treatment.

Fractures of the *proximal humerus* involving the physis, as a rule, are Salter-Harris type II injuries and have significant remodeling potential, and we can accept some deviations that will be corrected with bone growth. In unstable fractures or those with pronounced deviation, more stability may be necessary. This can be achieved by using Kirschner wires, inserted through the deltoid, or using flexible nails. Two nails are inserted in the lateral column of the humerus, from distal to proximal. The physis is crossed and the tips of the nails are impacted on the humeral head. The holes are made in the lateral column, one above the other, 1-2 cm apart. Early mobilization can be started once the fracture is stable, since there is no muscle transfixation in the shoulder. In such cases, the removal of the nail is recommended and it is important so the growth of the physis is not hindered.

Humeral shaft fractures may require stabilization with flexible nails when conservative treatment fails or in the polytraumatized child patient with long bone fractures[8]. Stabilization is performed with two nails; the entry point depends on the level of the fracture. Fractures of the proximal and middle thirds can be stabilized with two retrograde nails. Fractures of the *distal humerus* can be stabilized with two antegrade nails. Both nails are inserted through a lateral entrance located at the level of insertion of the deltoid muscle. The holes are made in the lateral cortex, one above the other.

As for supracondylar fractures of the humerus, although flexible intramedullary nails can be used, the use of Kirschner wires is already established, which makes the use of flexible nails an alternative with questionable benefits[9].

Diaphyseal fractures of the forearm

The treatment of *forearm fractures* has been performed in recent years with flexible intramedullary nails. A wide variety of intramedullary devices has been used with elastic nails made of titanium and steel[19-24,31]. The indication is for irreducible unstable fractures when closed treatment fails or in specific circumstances, such as Monteggia injuries, fractures of the head and neck of the radius.

The intramedullary nails have the advantage of minimal dissection of soft tissue, making it easier and safer to remove[12]. A single nail is used for each bone of the forearm. Generally, nails of 2.0 to 2.5 mm in diameter are used, using the largest diameter, if possible. The insertion is made respecting the proximal radial physis and care should be taken to avoid damage to the superficial radial nerve.

Lascombes *et al*.[13] advocate that the two nails be pre-tensioned; however, we observed that even straight nails are also effective. Another issue to know is if both bones should be stabilized. Clearly, if there is only one broken bone, a nail is necessary; however, if both bones are fractured and both fractures have deviated, two nails are certainly necessary. In the cases where the fractures are of the two bones but only one has deviated, both should be reduced and stabilized[14] (Figure 3).

Fractures of the neck of the radius can be treated with flexible nails inserted into the distal end. The curved tip of the nail can be used as an aid in reducing the fracture, which is done with gentle manipulation of the fragments and the nail is used in order to reduce under scopy[15,16].

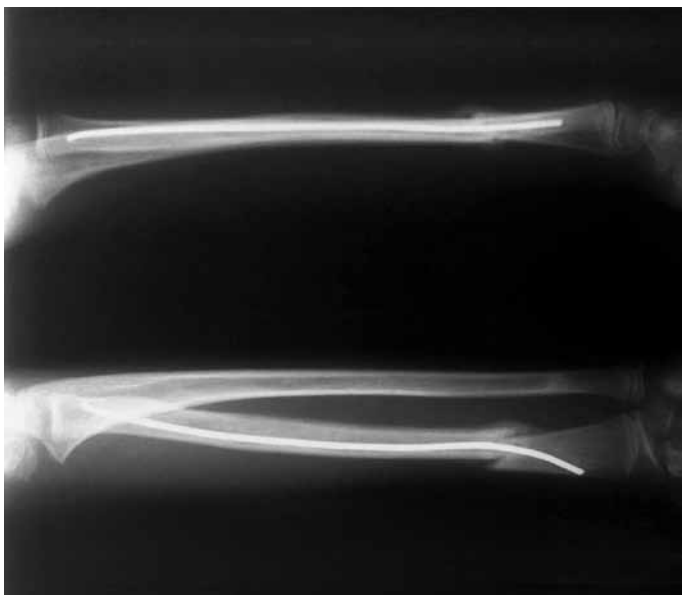

Figure 3 – Radiographic image showing reduction of Galeazzi fracture with flexible intramedullary nail that was inserted into the distal metaphysis of the radius.

The Monteggia fracture-dislocation can be treated with closed manipulation and the use of a plaster cast or plate and screw; however, in the presence of instability, the reduction of the radial head can be difficult. When this occurs, a flexible nail can be used in the ulna in order to restore the length and facilitate the reduction of the radial head.

REMOVAL OF IMPLANTS

The removal of implants in children is an orthopedic procedure that remains controversial. The tendency is to avoid a second surgical procedure, minimizing the risks of surgery and its costs and complications. Simanovsky and Tair[41] re-evaluated 143 children who underwent removal of intramedullary implants of the femur and forearm. Of these, in 16 the material was removed because of protrusion, skin irritation, and discomfort, while most were asymptomatic. Complications were observed, such as failure to remove the implant material in three children and two refractures.

There is no agreement in the literature regarding the removal of implant material. Several authors advocate for its removal[42-45], while others have questioned this decision claiming that it is only required in symptomatic patients or when the implant may compromise the physis due to its flexibility or because the transfixation of the implant was necessary to stabilize the fracture[46-49].

It is preferable to remove the implants in children. This is because, as the child grows, it may be difficult to remove them, because the implant can be buried in the medullary cavity of the diaphysis and there is the possibility of refracture, making the procedure even more difficult. Infection of the implant due to late contamination may occur and should be considered. On the other hand, leaving the implants means lower costs by avoiding a new surgical procedure and the fact that most patients are asymptomatic.

DISCUSSION

The child has a great capacity for bone remodeling and in some cases, conservative treatment results in deformity or shortening at the fracture site. In many respects, the flexible intramedullary nails are indicated. The method is safe, minimally invasive, has few complications, and does not interfere with growth. It is also associated with a short period of hospitalization and fast return to activity of daily living. Flynn and Waters[15] reported good results with flexible intramedullary nails in the treatment of long bone fractures in children; however, they stressed that most fractures can and should continue to be treated with closed reduction and immobilization. Another factor of the surgical method to be considered is performing a new intervention for the removal of the implant. Some authors have questioned the need to remove the implant material in the search for better results, because the major complications occur precisely with the tip of the protruding nails to facilitate removal, and when the choice is made not to remove them, their ends can be made less salient, reducing complaints, and therefore the need for a new surgical procedure. Obviously, such a decision must be thoroughly evaluated because we know the risks of a lost intramedullary synthesis in the event of a new fracture or even in the case of a bone infection.

Given these considerations, we emphasize the need for non-surgical treatment of most fractures in children.

Some questions remain: what is considered the age or weight limit for the use of flexible intramedullary nails? It is necessary to remove the implants and, if so, when?

It is true that flexible intramedullary nails offer advantages in treating some fractures in children. However, flexible intramedullary nails stand out to be the treatment for certain fractures of long bones in children, in particular, femoral shaft and forearm bone fractures.

Knowledge of the method, as well as the handling of its complications, should be part of the arsenal of the orthopedic traumatologist.

REFERENCES

1. Luhmann SJ, Schootman M, Schoenecker PL, Dobbs MB, Gordon JE. Complications of titanium elastic nails for pediatric femoral shaft fractures. J Pediatr Orthop; 2003;23(4):443-7.
2. Orler R, Hersche O, Helfet DL, Mayo KA, Ward T, Ganz R. Avascular femur head necrosis as severe complication after femoral intramedullary nailing in children and adolescents. Unfallchirurg. 1998;101(6):495-9.
3. Vransky P, Bourdelat D, Al Faour A. Flexible stable intramedullary pinning technique in the treatment of pediatric fractures. J Pediatr Orthop. 2000;20(1):23-7.
4. Soni JF, Santili C, Lancellotti CLP, Hecke MB, Almeida FR, Karam LZ. Análise comparativa em modelo computadorizado bidimensional com simulação do emprego de hastes flexíveis de aço e titânio, na fratura do fêmur da criança, utilizando o método dos elementos finitos. Rev Bras Ortop. 2008;43(5):183-92.
5. Bar-On E, Sagiv S, Porat S. External fixation or flexible intramedullary nailing for femoral shaft fractures in children: a prospective, randomised study. J Bone Joint Surg Br. 1997;79(6):975-8,.
6. Greisberg J, Bliss MJ, Eberson CP, Solga P, d'Amato C. Social and economic benefits of flexible intramedullary nails in the treatment of pediatric femoral shaft fractures. Orthopedics. 2002;25(10):1067-70.
7. Flynn JM, Hresko T, Reynolds RA, Blasier RD, Davidson R, Kasser J. Titanium elastic nails for pediatric femur fractures: a multicenter study of early results with analysis of complications. J Pediatr Orthop. 2001;21(1):4-8.
8. Cramer KE. The pediatric polytrauma patient. Clin Orthop Relat Res.1995.;(318):125-35.
9. Prevot J, Lascombes P, Metaizeau JP, Blanquart D. [Supracondylar fractures of the humerus in children: treatment by downward nailing]. Rev Chir Orthop Reparatrice Appar Mot. 1990;76(3):191-7.
10. Calder P, Achan P, Barry M. Diaphyseal forearm fractures in children treated with intramedullary fixation: outcome of K-wire versus elastic stable intramedullary nail. Injury. 2003;34(4):278-82.
11. Nielsen AB, Simonsen O. Displaced forearm fractures in children treated with AO plates. Injury. 1984;15(6):393-6.
12. Van der Reis WL, Otsuka NY, Moroz P, Mah J. Intramedullary nailing versus plate-fixation for unstable forearm fractures in children. J Pediatr Orthop. 1998;18(1):9-13.
13. Lascombes P, Prevot J, Ligier JN, Metaizeau JP, Poncelet T. Elastic stable intramedullary nailing in forearm shaft fractures in children: 85 cases. J Pediatr Orthop; 1990;10(2):167-71.
14. Saad EA. Avaliação clínica e radiográfica de 31 pacientes com idade entre 8 e 16 anos no tratamento de 32 fraturas do fêmur pela fixação intramedular retrógrada com hastes flexíveis de Ender [tese]. São Paulo: Universidade Federal de São Paulo, Escola Paulista de Medicina; 2003.
15. Flynn JM, Waters PM. Single-bone fixation of both-bone forearm fractures. J Pediatr Orthop;1996;16(5):655-9.
16. Gonzalez-Herranz P, Alvarez-Romera A, Burgos J, Rapariz JM, Hevia E. Displaced radial neck fractures in children treated by closed intramedullary pinning (Metaizeau technique). J Pediatr Orthop.1997;17(3):325-31.
17. Metaizeau JP, Lascombes P, Lemelle JL, Finlayson D, Prevot J. Reduction and fixation of displaced radial neck fractures by closed intramedullary pinning. J Pediatr Orthop. 1993;13(3):355-60.
18. Waseem M, Paton RW. Percutaneous intramedullary elastic wiring of displaced diaphyseal forearm fractures in children: a modified technique. Injury. 1999;20(1):21-4.
19. Richter D, Ostermann PAW, Ekkernkamp A, Muhr G, Hahn MP. Elastic intramedullary nailing: a minimally invasive concept in the treatment of unstable forearm fractures in children. J Pediatr Orthop. 1998;18(4):457-61.
20. Luhmann SJ, Gordon JE, Schoenecker PL. Intramedullary fixation of unstable both-bone forearm fractures in children. J Pediatr Orthop. 1998;18(4):451-6.
21. Shoemaker SD, Comstock CP, Mubarak SJ, Wenger DR, Chambers HG. Intramedullary Kirschner wire fixation of open or unstable forearm fractures in children. J Pediatr Orthop. 1999;19(3):329-37.
22. Yung SH, Lam CY, Choi KY, Ng KW, Maffulli N, Cheng JC. Percutaneous intramedullary Kirschner wiring for displaced diaphyseal forearm fractures in children. J Bone Joint Surg Br. 1998;80(1):91-4.
23. Pugh DMW, Galpin RD, Carey TP. Intramedullary Steinmann pin fixation of forearm fractures in children: long-term results. Clin Orthop Relat Res. 2000;(376):39-48.
24. Street DM. Intramedullary forearm nailing. Clin Orthop Relat Res. 1986;(212):219-30.
25. Vainionpää S, Böstman O, Pätiälä H, Rokkanen P. Internal fixation of forearm fractures in children. Acta Orthop Scand. 1987;58(2):121-3.
26. Langkamer VG, Ackroyd CE. Removal of forearm plates: a review of the complications. J Bone Joint Surg Br. 1990;72(4):601-4.
27. Fricka KB, Mahar AT, Lee SS, Newton PO. Biomechanical analysis of antegrade and retrograde flexible intramedullary nail fixation of pediatric femoral fractures using a synthetic bone model. J Pediatr Orthop. 2004;24(2):167-71.
28. Ahn JL, Park JS. Pathologic fractures secondary to unicameral bone cysts. Int Orthop. 1994;18(1):20-2.
29. Roposch A, Saraph V, Linhart WE. Flexible intramedullary nailing for the treatment of unicameral bone cysts in long bones. J Bone Joint Surg Am. 2000;82(10):1447-53.
30. Knorr P, Schmittenbecher PP, Dietz HG. Elastic stable intramedullary nailing for the treatment of complicated juvenile bone cysts of the humerus. Eur J Pediatr Surg. 2003;13(1):44-9.
31. Cohen J. Intramedullary nailing for the treatment of unicameral bone cysts. J Bone Joint Surg Am. 2001;83(8):1279-80.
32. Flynn JM, Skaggs DL, Sponseller PD, Ganley TJ, Kay RM, Leitch KK. The surgical management of pediatric fractures of the lower extremity. Instr Course Lect. 2003;52:647-59.
33. Bopst L, Reinberg O, Lutz N. Femur fracture in preschool children: experience with flexible intramedullary nailing in 72 children. J Pediatr Orthop. 2007;27(3):299-303.
34. Chitgopkar SD. Flexible nailing of fractures in children using stainless steel Kirschner wires. J Pediatr Orthop B. 2008;17(5):251-5.
35. Flynn JM, Hresko T, Reynolds RA, Blasier RD, Davidson R, Kasser J. Titanium elastic nails for pediatric femur fractures: a multicenter study of early results with analysis of complications. J Pediatr Orthop. 2001;21(1):4-8.
36. Flynn JM, Luedtke L, Ganley TJ, Pill SG. Titanium elastic nails for pediatric femur fractures: lessons from the learning curve. Am J Orthop. 2002;31(2):71-4.
37. Luhmann SJ, Schootman M, Schoenecker PL, Dobbs MB, Gordon JE. Complications of titanium elastic nails for pediatric femoral shaft fractures. J Pediatr Orthop. 2003;23(4):443-7.
38. Narayanan UG, Hyman JE, Wainwright AM, Rang M, Alman BA. Complications of elastic stable intramedullary nail fixation of pediatric femoral fractures, and how to avoid them. J Pediatr Orthop. 2004;24(4):363-9.
39. Mann DC, Weddington J, Davenport K. Closed Ender nailing of femoral shaft fractures in adolescents. J Pediatr Orthop. 1986;6(6):651-5.
40. Volpon JB, Porto MR, Moretto M. Tratamento conservador das fraturas diafisárias do fêmur da criança. Rev Bras Ortop. 1997;32(1):11-4.
41. Simanovsky N, Tair MA, Removal of flexible titanium nails in children. J Bone Joint Surg Br. 2004;86:947-53.
42. Schmalzried TP, Grogan TJ, Neumeier PA, Dorey FJ. Metal removal in a pediatric population: benign procedure or necessary evil? J Pediatr Orthop. 1991;11(1):72-6.
43. Alzahrani AG, Behairy YM, Alhossan MH, Arab FS, Alammari AA. Removal of internal fixation in pediatric patients. Saudi Med J. 2003;24(3):254-5.
44. Highland TR, LaMont RL. Deep, late infections associated with internal fixation in children. J Pediatr Orthop. 1985;5(1):59-64.
45. Lovell ME, Galasko CS, Wright NB. Removal of orthopedic implants in children: morbidity and postoperative radiologic changes. J Pediatr Orthop B. 1999;8(2):144-6.
46. Richards RH, Palmer JD, Clarke NMP. Observation on removal of metal implants. Injury. 1992;23(1):25-8.
47. Kahle WK. The case against routine metal removal. J Pediatr Orthop.1994; 14(2):229-37.
48. Peterson HA. Metallic implant removal in children. J Pediatr Orthop.2005; 25(1):107-15.
49. Jago RD, Hindley CJ. The removal of metalwork in children. Injury.1998; 29(6):439-41.