Article published online: 2022-10-14

Original Article

Impact of the Suspension of Elective Surgeries for Adolescent Idiopathic Scoliosis during the COVID-19 Pandemic*

Impacto da suspensão das cirurgias eletivas em pacientes com escoliose idiopática do adolescente no período da pandemia de covid-19

Matheus Neves Castanheira[1] Giovanni Salvatore Nardone[1] Rafael de Paiva Luciano[1] Márcio Squassoni Leite[1]

[1] Orthopedics and Traumatology Service, Hospital Municipal Universitário de Taubaté, Taubaté, SP, Brazil

Rev Bras Ortop

Address for correspondence Matheus Neves Castanheira, Resident doctor of Serviço de Ortopedia e Traumatologia do Hospital Municipal Universitário de Taubaté, Rua Antônio Wladimir do Prado, N 27, Quiririm, 12043-460, Taubaté, SP, Brazil (e-mail: neves_mp@hotmail.com).

Abstract

Objectives This study evaluated the radiographic progressions of scoliotic curves higher than 40° in patients with adolescent idiopathic scoliosis (AIS). These subjects waited for the surgical procedure while elective surgeries were on hold during the COVID-19 pandemic. In addition to radiographic progressions, this study described the quality of life of these patients.

Methods This study is a retrospective cohort assessing 29 AIS patients with surgical indications registered in the Brazilian public healthcare service. We compared the scoliotic radiographic measurements in two moments: at the beginning of the interruption of elective surgeries due to the COVID-19 pandemic and when these procedures resumed.

Results When comparing the radiographic measurements before and after the suspension of assessments for elective surgeries, we observed a significant increase in main curve angles ($p < 0.001$), with variations ranging from 0 to 68° and a median value of 10°. In secondary curves, we observed an increase in angles from the proximal thoracic ($p < 0.001$) and lumbar ($p = 0.001$) regions. However, the increase in the main thoracic region was not significant ($p = 0.317$).

Conclusion The suspension of elective surgeries for AIS resulted in a significant increase in the radiographic values of patients' spine deformities. This increase harmed the quality of life of these subjects and their families.

Keywords
- adolescent
- scoliosis
- elective surgical procedures
- unified health system

* *Study developed at the Orthopedics and Traumatology Service, Hospital Municipal Universitário de Taubaté, Taubaté, SP, Brazil.*

received
June 1, 2022
accepted
July 29, 2022

DOI https://doi.org/10.1055/s-0042-1756318.
ISSN 0102-3616.

© 2022. Sociedade Brasileira de Ortopedia e Traumatologia. All rights reserved.
This is an open access article published by Thieme under the terms of the Creative Commons Attribution-NonDerivative-NonCommercial-License, permitting copying and reproduction so long as the original work is given appropriate credit. Contents may not be used for commercial purposes, or adapted, remixed, transformed or built upon. (https://creativecommons.org/licenses/by-nc-nd/4.0/)

Thieme Revinter Publicações Ltda., Rua do Matoso 170, Rio de Janeiro, RJ, CEP 20270-135, Brazil

Resumo

Objetivos Neste estudo foram avaliadas as progressões radiográficas das curvas escolióticas, acima de 40 graus em pacientes com escoliose idiopática do adolescente (EIA). Os indivíduos analisados aguardavam o procedimento cirúrgico, em período de suspensão das cirurgias eletivas, durante a pandemia de covid-19. Além das progressões radiográficas, nesta pesquisa foi descrita a qualidade de vida destes pacientes.

Métodos O artigo refere-se a um estudo de coorte retrospectivo, que avaliou 29 pacientes com EIA com indicação cirúrgica, todos cadastrados no serviço público de saúde brasileiro. As medidas radiográficas escolióticas dos pacientes foram comparadas em dois momentos: no início do período da interrupção de cirurgias eletivas, devido à pandemia de covid-19, e logo após a liberação destas.

Resultados A partir da comparação das medidas radiográficas entre as avaliações pré e pós suspensão das cirurgias eletivas, observamos o aumento significativo dos valores angulares da curva principal ($p < 0{,}001$), com variações entre 0 e 68°, e mediana de 10°. Em relação às curvas secundárias, observamos um aumento dos valores angulares da região torácica proximal ($p < 0{,}001$) e lombar ($p = 0{,}001$). Entretanto, o aumento da região torácica principal não foi considerado significativo ($p = 0{,}317$).

Conclusão A suspensão das cirurgias eletivas, para a correção da EIA resultou em um aumento significativo no valor radiográfico das deformidades das colunas dos pacientes, fator que promoveu um impacto negativo na qualidade de vida de pacientes e familiares.

Palavras-chave

- adolescente
- escoliose
- procedimentos cirúrgicos eletivos
- sistema único de saúde

Introduction

Adolescent idiopathic scoliosis (AIS) is one of the most frequent spinal diseases, with an incidence ranging from 0.5 to 10% in the world population.[1] The spinal instrumentation and fusion procedure for AIS correction is performed frequently in pediatric orthopedic patients. Nevertheless, only 10% of AIS patients require surgical correction.[2]

The Brazilian Unified Health System (SUS) has difficulties meeting the demand for these major surgeries, which remain restricted to a few regional treatment centers in populous regions. Scoliotic curves higher than 40° with surgical indications constitute severe cases because they progress even after the end of skeletal maturity.[3,4]

Brazil implemented public health measures against the pandemic after the first diagnosis of covid-19 in the country. However, the lack of availability of intensive care unit (ICU) and hospital beds during this period overloaded the healthcare system, leading to restrictions. These factors resulted in the suspension of elective surgical treatments.[5–7]

The excessive delay for scoliosis surgery may require additional procedures, such as an anterior release, for satisfactory spinal curvature correction. Moreover, these subjects may need longer surgeries with a higher risk of complications (increased blood loss, neurological deficits, or unsatisfactory spinal curvature correction).[8]

This study aimed to evaluate the radiographic progression of the scoliotic curve in young patients awaiting surgery in a public hospital in the state of São Paulo, Brazil. The study occurred during the period of suspension of elective surgeries due to the covid-19 pandemic. In addition to the radiographic comparison of scoliotic curves, the patients underwent quality-of-life assessments.

Methods

This retrospective cohort study evaluated 29 patients with AIS (scoliotic curves higher than 40°) with surgical indication, all registered in the Brazilian public health service and awaiting surgery for scoliosis correction.

We evaluated the radiographic evolution of the scoliotic curves from the beginning of elective procedures interruption due to the COVID-19 pandemic until their resumption. In addition, we analyzed the epidemiological data of the sample and other factors associated with the progression of their scoliotic curves. The Research Ethics Committee approved this study under the number 5039.

The scoliotic curve progression evaluation used anteroposterior (AP) and panoramic (P) total spine radiographs in orthostasis. We measured the curve according to the Cobb method[9] before the beginning of the pandemic in Brazil in March 2020. We compared these data with radiographs from the same patients shortly after the return of the elective surgery service in December 2021. The quality-of-life assessment employed the questionnaire proposed by the Scoliosis Research Society (SRS), that is, the Brazilian version of the SRSr-22 questionnaire for AIS.[10,11]

We described categorical variables as absolute frequencies and percentages and numerical variables as mean, standard deviation (SD), median, quartiles, and minimum and maximum values. The Wilcoxon nonparametric tests for paired data compared radiographic measurements. The

 © 2022. Sociedade Brasileira de Ortopedia e Traumatologia. All rights reserved.

Table 1 Data from patients with severe adolescent idiopathic scoliosis awaiting surgical correction (n = 29)

Gender	
Female	25 (86.2%)
Male	4 (13.8%)
Age (years old)	
Mean (SD)	15.8 (2.8)
Median (Q1; Q3)	15.0 (14.0; 17.0)
Minimum and maximum values	11.0; 23.0
Age at menarche (years old) (n = 25)	
Mean (SD)	12.2 (1.3)
Median (Q1; Q3)	12.0 (11.0; 13.0)
Minimum and maximum values	10.0; 15.0
Family member with AIS	
No	23 (79.3%)
Yes	6 (20.7%)
Time between evaluations (months)	
Mean (SD)	23.6 (7.1)
Median (Q1; Q3)	22.0 (18.0; 25.0)
Minimum and maximum values	15.0; 39.0

Abbreviations: AIS, Adolescent idiopathic scoliosis; Q1, first quartile; Q3, third quartile; SD, standard deviation.

analyses were performed using the IBM SPSS Statistics for Windows, Version 24.0 statistical software (IBM Corp., Armonk, NY, USA) considering a significance level of 5%.

Results

The patients' age ranged from 11 to 23 years, with a mean value of 15.8 years (SD = 2.8 years). Twenty-five (86.2%) subjects were female, and 4 (13.8%) were male. A total of 6 (20.7%) patients had a family history of AIS (►**Table 1**).

The interval between radiographic evaluations ranged from 15 to 39 months, with a median time of 22 months (►**Table 1**). The Risser index defined the degree of skeletal maturity of the spine based on an AP pelvic radiograph. Before the elective surgery interruption, we observed the following Risser indices: 0 in 4 (13.8%) patients, 3 in 6 (20.7%) subjects, 4 in 7 (24.1%) patients, and 5 in 12 (41.4%) patients. After resuming elective surgeries, skeletal maturity was as follows: 2 (6.9%) subjects were Risser 3, 6 (20.7%) patients were Risser 4, and 21 (72.4%) patients were Risser 5. ►**Table 2** shows these analyses.

We used the Lenke classification to determine the type of scoliotic curve.[4] The main curve was thoracic (apex = T2–T11/T12 disc) in 24 (82.8%) patients, thoracolumbar (apex = T12–L1) in 2 (6.9%) subjects, and lumbar (apex = L1–L2 disc-L4) in 3 (10.3%) patients.

According to Lenke classification, 9 (31.0%) patients were in the main thoracic type (LENKE 1), 5 (17.2%) were in the double thoracic type (LENKE 2), 11 (37.9%) were in the main double type (LENKE 3), 1 (3.4%) had a triple curve (LENKE 4), and 3 (10.3%) had a rigid lumbar and main thoracic curve (LENKE 6). This sample had no LENKE 5 patients (►**Table 2**).

Table 2 Radiographic features from patients with severe adolescent idiopathic scoliosis awaiting surgical correction (n = 29)

Previous Risser index	
0	4 (13.8%)
3	6 (20.7%)
4	7 (24.1%)
5	12 (41.4%)
Current Risser index	
3	2 (6.9%)
4	6 (20.7%)
5	21 (72.4%)
Curve type/Main curve	
Thoracic (Apex = T2–T11/T12 disc)	24 (82.8%)
Thoracolumbar (Apex = T12-L1)	2 (6.9%)
Lumbar (Apex = L1–L2 disc-L4)	3 (10.3%)
Lenke classification	
Main thoracic	9 (31.0%)
Double thoracic	5 (17.2%)
Main double	11 (37.9%)
Triple curve	1 (3.4%)
Lumbar curve with rigid main thoracic curve	3 (10.3%)
Lumbar modifier	
Type A	7 (24.1%)
Type B	7 (24.1%)
Type C	15 (51.7%)
Sagittal modifier	
Negative	1 (3.4%)
Neutral	25 (86.2%)
Positive	3 (10.3%)
Treatment	
No	24 (82.8%)
Brace	3 (10.3%)
Brace (irregularly used)	2 (6.9%)

Regarding lumbar modifiers, 7 (24.1%) patients were typed A (median vertical sacral line [LSVM] passing between the pedicles of the lumbar apical vertebra), 7 (24.1%) patients were typed B (LSVM touching the pedicle of the apical vertebra), and 15 (51.7%) patients were typed C (LSVM medial to the pedicles of the lumbar apical vertebra).

Regarding the thoracic sagittal modifier, 1 (3.4%) patient had hypokyphosis, 25 (86.2%) subjects had a neutral spine, and 3 (10.3%) patients had thoracic hyperkyphosis (►**Table 2**).

 © 2022. Sociedade Brasileira de Ortopedia e Traumatologia. All rights reserved.

Table 3 Angles from patients with severe adolescent idiopathic scoliosis awaiting surgical correction (n = 29)

Angles	Time		Range	*p* value
	1st evaluation	2nd evaluation	(2nd – 1st evaluation)	
Main curve				
Mean (SD)	60.9 (12.8)	75.0 (18.8)	14.1 (16.4)	< 0.001
Median (Q1; Q3)	60.0 (52.0; 68.0)	75.0 (60.0; 87.0)	10.0 (2.0; 20.0)	
Minimum and maximum values	40.0; 95.0	44.0; 126.0	0.0; 68.0	
Proximal thoracic				
Mean (SD)	25.5 (8.0)	29.6 (10.7)	4.0 (5.4)	< 0.001
Median (Q1; Q3)	28.0 (20.0; 30.0)	30.0 (23.0; 35.0)	3.0 (0.0; 5.0)	
Minimum and maximum values	14.0; 41.0	14.0; 60.0	0.0; 20.0	
Main thoracic (n = 4)				
Mean (SD)	37.5 (12.6)	42.0 (19.7)	4.5 (9.0)	0.317
Median (Q1; Q3)	40.0 (30.0; 45.0)	40.0 (30.0; 54.0)	0.0 (0.0; 9.0)	
Minimum and maximum values	20.0; 50.0	20.0; 68.0	0.0; 18.0	
Lumbar (n = 25)				
Mean (SD)	39.5 (16.3)	46.8 (17.2)	7.3 (9.9)	0.001
Median (Q1; Q3)	30.0 (28.0; 55.0)	45.0 (30.0; 60.0)	5.0 (0.0; 8.0)	
Minimum and maximum values	20.0; 70.0	24.0; 75.0	0.0; 38.0	

Abbreviations: Q1, first quartile; Q3, third quartile; SD, Standard deviation.

In this study, 24 (82.8%) patients had not undergone previous treatment. Three (10.3%) subjects used a brace correctly, and 2 (6.9%) patients used it irregularly (►**Table 2**).

When comparing the radiographic measurements in both evaluations (►**Table 3**, ►**Figure 1**), we observed a significant increase in the main curve angles ($p < 0.001$), ranging from 0 to 68°, with a median value of 10°. Regarding secondary curves, there was an increase in angles from the proximal thoracic ($p < 0.001$) and lumbar ($p = 0.001$) regions. However, in these cases, the increase in the main thoracic region was not significant ($p = 0.317$). The proximal thoracic region angles ranged from 0 to 20°, with a median value of 3° (1st quartile, 0°, and 3rd quartile, 5°). For the lumbar region, angles ranged from 0 to 38°, with a median value of 5° (1st quartile, 0°, and 3rd quartile, 8°). ►**Table 4** shows individual curves for each patient at both time points.

At the quality of life assessment, the average SRS scores were 16.4 (SD = 4.5) in the function/activity domain, 16.2 (SD = 5.2) in the pain domain, 11.1 (SD = 4.0) in the self--image/appearance domain, 15.1 (SD = 4.5) in the mental health domain, and 7.4 (SD = 1.6) in the treatment satisfaction domain, with a subtotal score of 58.8 (SD = 15.1) and a total score of 66.2 (SD = 15.9). ►**Table 5** shows the information on the quality of life of AIS patients.

Discussion

The main motivation for this study was the concern with the high number of patients waiting for elective surgeries and the potential increase in the angle of their scoliosis curve during the covid-19 pandemic. Our service suspended surgeries requiring postoperative care in intensive care unit (ICU) from March 2020 to December 2021.

Other studies had this same concern since the reduction in the number of elective orthopedic surgeries ranged from 48.5 to 79%.[6,7] However, until now, no study has addressed the interruption of surgeries for deformity corrections, specifically AIS.

This study evaluated patients awaiting AIS correction surgery in a public hospital. The epidemiological data obtained were similar to other Brazilian research of the same nature, consisting of adolescents (11–23 years old), mostly female.[3,12]

In contrast with Lima Junior et al.,[3] the most prevalent Lenke classification was 3, with double main curves predominance. In addition, there were no Lenke 5 curves. The thoracic sagittal and lumbar modifiers were consistent with the literature.[3]

We detected significant increases in the main curve angles, ranging from 0 to 68°, with an average of 14.1°. Similarly, Bressan-Neto et al.[12] observed differences in radiographic parameters, indicating a progression of the scoliotic deformity, when comparing the evaluations at the time of surgical indication and the procedure date. These authors reported an average increase of 18.6° in the Cobb angle of the main deformity.[12]

The excessive delay for scoliosis surgery, especially in public services, was a cause for concern by other authors. Ahn et al.[9] demonstrated that a delay greater than 4 months resulted in the need for additional surgeries, such as anterior release to obtain satisfactory correction of

 © 2022. Sociedade Brasileira de Ortopedia e Traumatologia. All rights reserved.

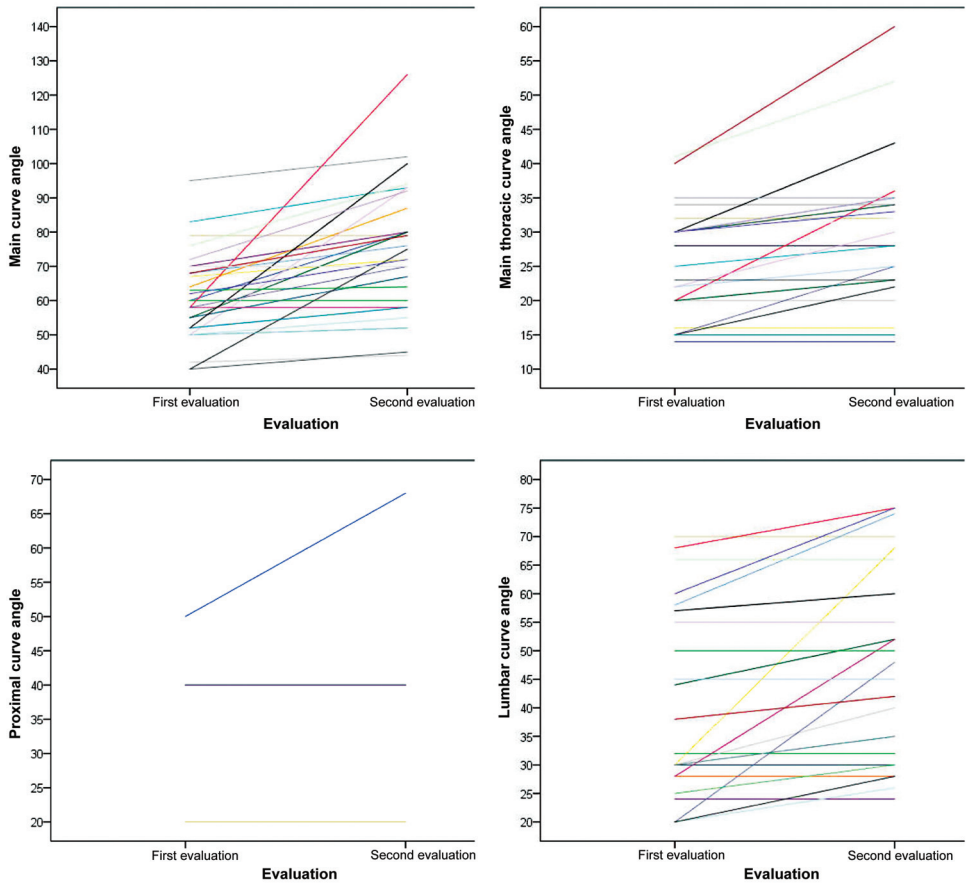

Fig. 1 Angle measurements in both evaluations of patients with severe adolescent idiopathic scoliosis awaiting surgical correction (n = 29).

Table 4 Individual data from the sample

Awaiting list of scoliosis patients									
Number	Gender	Age	Time between evaluations	Curve type/ Main curve	Lenke classifications	Difference in main curve angle	Difference in secondary curve angle	Current Risser index	Previous Risser index
1	F	15	3 years, 3 months	Left lumbar	6CN	T11–L3 = 20°	C7–T4 = 0 / T4–T10 = 18°	5	3
2	F	21	1 year, 10 months	Right thoracic	1C–	T5–T11 = 0	T1–T5 = 0 / T12–L4 = 0	5	5
3	F	16	1 year, 3 months	Right thoracic	1CN	T5–T12 = 0	C7–T5 = 0/ T12–L4 = 0	5	5
4	M	20	2 years	Right thoracic	3CN	T7–T12 = 10°	T2–T7 = 0 / T12–L4 = 0	5	4
5	F	23	2 years, 11 months	Right thoracic	1CN	T6–T12 = 5°	T1–T5 = 0 / T12–L4 = 0	5	5
6	F	13	2 years, 10 months	Right thoracic	4C+	T5–T12 = 68°	T1–T5 = 16° / L1–L5 = 38°	5	0
7	F	15	1 year, 6 months	Right thoracic	3CN	T5–T11= 10°	T1–T5 = 3° / T11–L4= 7°	4	4
8	F	21	2 years, 11 months	Left lumbar	6BN	T12–L4 = 2°	T2–T5 = 0 / T5–T12 = 0	5	5
9	F	15	2 years, 5 months	Right thoracic	1BN	T5–L1 = 8°	T2–T5 = 5° / L1–L5 = 5°	5	4
10	M	15	2 years, 1 month	Right thoracic	1BN	T5–T12 = 25°	T2–T5 = 3° / T12–L5 = 10°	4	0
11	F	15	1 year, 5 months	Right thoracic	3CN	T5–T11 = 23°	T2–T5 = 4° / T11–L4 = 16°	4	3
12	F	11	1 year, 10 months	Right thoracic	3A+	T4–T10 = 43°	T2–T4 = 8° / T10–L5 = 8°	4	3
13	M	17	1 year, 4 months	Right thoracic	2AN	T7–L2 = 12°	T2–T7 = 4° / L2–L5 = 0	5	5
14	M	15	1 year, 9 months	Right thoracic	2BN	T5–T12 = 18°	T1–T5 = 11° / T12–L4 = 0	4	5
15	F	15	1 year, 5 months	Right thoracic	1BN	T9–L3 = 0	T4–T9 = 0 / L3–L5 = 0	5	4
16	F	17	1 year, 11 months	Right thoracic	3CN	T4–T11 = 7°	T1–T4 = 0 / T12–L5 = 0	5	5
17	F	14	2 years, 11 months	Right thoracic	2BN	T6–L2 = 48°	T2–T7 = 13° / L2–L5 = 24°	4	3
18	F	17	1 year, 10 months	Right thoracic	1AN	T6–L1 = 5°	T1– T7 = 0 / L1–L5: 5°	5	5

(*Continued*)

 © 2022. Sociedade Brasileira de Ortopedia e Traumatologia. All rights reserved.

Table 4 (*Continued*)

Awaiting list of scoliosis patients									
Number	Gender	Age	Time between evaluations	Curve type/ Main curve	Lenke classifications	Difference in main curve angle	Difference in secondary curve angle	Current Risser index	Previous Risser index
19	F	14	1 year, 6 months	Right thoracic	3CN	T6–T11: 1°	T1– T5 = 2°/T12–L4 =3°	5	4
20	F	13	1 year, 11 months	Right thoracic	1AN	T6–L1 = 12°	T1–T6 = 10° / T11–L4 = 6°	5	3
21	F	13	1 year, 4 months	Right thoracic	3CN	T3–T10 = 2°	C7–T3 = 0 / T10–L4 = 0	5	4
22	F	13	2 years	Right thoracic	3AN	T4–T12 = 35°	C7–T4 = 7°/ T12–L5 = 28°	3	0
23	F	14	1 year, 6 months	Right thoracic	1AN	T6–T12 = 2°	T1–T6 = 3° / T12–L4 = 5°	5	5
24	F	17	1 year, 8 months	Right thoracic	2AN	T5–T12 = 11°	T2–T6 = 20° / L1–L5 = 8°	5	4
25	F	19	3 years, 1 month	Right thoracic	3BN	T5–T11 = 10°	T1–T5 = 3° / T11–L4 = 0°	5	5
26	F	16	1 year, 7 months	Right thoracic	3CN	T4–T11 = 0	T1–T4 = 0 / T11–L4 = 4°	5	5
27	F	15	1 year ,7 months	Right thoracic	2CN	T10–L3 = 6°	T1–T6= 0 / T6–T10 = 0	5	5
28	F	13	1 year, 7 months	Right thoracic	3C+	T7–T12 = 20°	T1–T7= 5° / T12–L5 = 15°	3	0
29	F	15	1 year, 9 months	Left lumbar	6CN	T12–L3 = 5°	T1–T6= 0 / T6–T12 = 0	5	3

Abbreviations: F, Female; M, male.

Table 5 Scoliosis Research Society (SRS) questionnaire scores for evaluation of the current quality of life of patients with severe adolescent idiopathic scoliosis awaiting surgical correction (n = 27)

Function/activity	
Mean (SD)	16.4 (4.5)
Median (Q1; Q3)	16.0 (14.0; 19.0)
Minimum and maximum values	8.0; 25.0
Pain	
Mean (SD)	16.2 (5.2)
Median (Q1; Q3)	16.0 (11.0; 21.0)
Minimum and maximum values	8.0; 25.0
Self-image/appearance	
Mean (SD)	11.1 (4.0)
Median (Q1; Q3)	9.0 (8.0; 14.0)
Minimum and maximum values	5.0; 21.0
Mental health	
Mean (SD)	15.1 (4.5)
Median (Q1; Q3)	15.0 (12.0; 19.0)
Minimum and maximum values	6.0; 22.0
Subtotal	
Mean (SD)	58.8 (15.1)
Median (Q1; Q3)	60.0 (46.0; 65.0)
Minimum and maximum values	28.0; 89.0
Treatment satisfaction	
Mean (SD)	7.4 (1.6)
Median (Q1; Q3)	8.0 (6.0; 8.0)
Minimum and maximum values	4.0; 10.0
Total	
Mean (SD)	66.2 (15.9)
Median (Q1; Q3)	68.0 (52.0; 73.0)
Minimum and maximum values	32.0; 97.0

Abbreviations: Q1, first quartile; Q3, third quartile; SD, standard deviation.

the curvature of the spine. Moreover, surgeries were longer and had a higher risk of complications. According to this research, the scoliotic curve increased, on average, 14.1° during the surgery suspension period. This increase must be followed-up until the surgical procedure because of the reported complications. In our study, the time between radiographic evaluations ranged from 15 to 40 months, with a median of 22 months. This interval occurred because of health restrictions leading to the suspension of elective surgeries and the decreased availability of hospital beds.

The literature showed a significant drop in the number of referrals of patients to reference services in deformity treatment during the covid-19 pandemic.[13] The restrictions promoted by the public health services result in anxiety and prolonged suffering for patients and families, negatively impacting their quality of life.[8] In our sample, we observed a lower quality of life, with the worst scores related to the self-image and mental health domains.

Conclusions

This study concludes that, during the pandemic, the suspension of surgeries in AIS patients resulted in a significant increase in spine deformities and a negative impact on quality of life. Therefore, it is critical to consider these findings, especially in the current post-covid-19 pandemic period, to improve public health strategies and optimize elective surgeries for AIS correction.

Financial Support
This study received no financial support from public, commercial, or non-profit sources.

Conflict of Interests
The authors declare that there is no conflict of interests.

References

1 Wajchenberg M, Luciano R de P, Araújo RC, Martins DE, Puertas EB, Almeida SS. Polymorphism of the ace gene and the α-actinin-3 gene in adolescent idiopathic scoliosis. Acta Ortop Bras 2013;21 (03):170–174

2 Berry JG, Lieu TA, Forbes PW, Goldmann DA. Hospital volumes for common pediatric specialty operations. Arch Pediatr Adolesc Med 2007;161(01):38–43

3 Lima Júnior PC, Pellegrino L, Caffaro MFS, Meves R, Landim E, Avanzi O. Adolescent idiopathic scoliosis (ais): clinical and radiographic profile of waiting list for surgical treatment in tertiary hospitals of high complexity of Brazilian Public Health System. Coluna/Columna 2011;10(02):111–115

4 Lenke LG. The Lenke classification system of operative adolescent idiopathic scoliosis. Neurosurg Clin N Am 2007;18(02):199–206

5 Motta Filho GR, Leal AC, Amaral MVG, Maia PAV, Duarte MEL, Bähr GL. Impacto das estratégias adotadas para enfrentar a pandemia de COVID 19 em um Instituto Brasileiro de referência em cirurgia de alta complexidade em Ortopedia e Traumatologia. Rev Bras Ortop 2021;56(02):161–167

6 Dias RG, Hernandes MPF, Ferreira R, et al. Impacto da pandemia pelo Covid 19 nos procedimentos de artroplastia total do joelho primária no sistema único de saúde. Braz J Develop 2021;7(11): 107723–107729

7 Sterzo MCS, Rosan RAC, Oliveira HS, Fornari JV, Nonose N, Ninomiya AF. Impacto da quarentena decorrente da pandemia de Covid 19 na rotina de cirurgias de diáfise da tíbia. Int J Health Manag Rev 2020;6(02):1–6

8 Ahn H, Kreder H, Mahomed N, Beaton D, Wright JG. Empirically derived maximal acceptable wait time for surgery to treat adolescent idiopathic scoliosis. CMAJ 2011;183(09):E565–E570 (CMAJ)

9 Cobb JR. Outline for the study of scoliosis. Instr Course Lect 1948; 5:261–275

10 Asher M, Min Lai S, Burton D, Manna B. The reliability and concurrent validity of the scoliosis research society-22 patient questionnaire for idiopathic scoliosis. Spine 2003;28(01): 63–69

11 Camarini PM, Rosanova GC, Gabriel BS, Gianini PE, Oliveira AS. The Brazilian version of the SRS-22r questionnaire for idiopathic scoliosis. Braz J Phys Ther 2013;17(05):494–505

12 Bressan-Neto M, Filezio MR, Ferri-de-Barros F, Defino HLA. Unmet Needs of Surgical Care for Children: A Case Study in the Brazilian Publicly-Financed Health System. Rev Bras Ortop 2021;56(03): 360–367

13 Dermott JA, Kim DJ, Lebel DE. The impact of COVID-19 on idiopathic scoliosis referrals: cause for concern. Spine Deform 2021;9(06):1501–1507

 © 2022. Sociedade Brasileira de Ortopedia e Traumatologia. All rights reserved.