Is it Important to Know Where to Place the Spherical Marker for Hip Replacement Digital Planning?*

É importante saber onde posicionar o marcador esférico para o planejamento digital de artroplastia de quadril?

Giancarlo Cavalli Polesello[1] Thiago Tronco Salerno[1] João Hélio Zucarelli Rezende[1] Marcelo Cavalheiro de Queiroz[1] Nayra Deise Rabelo[1,2] Walter Ricioli Junior[1]

[1] Hip Group, Orthopedics and Traumatology Department, Faculdade de Ciências Médicas da Santa Casa de São Paulo (FCMSCSP), Irmandade Santa Casa de Misericórdia, São Paulo, SP, Brazil
[2] Human Motion Analysis Laboratory, Rehabilitation Sciences Departament, Universidade Nove de Julho - UNINOVE, São Paulo, SP, Brazil

Address for correspondence Giancarlo Cavalli Polesello, MD, PhD, Rua Dr. Cesário Mota Júnior, 112, Bairro Vila Buarque, São Paulo, SP, 01221-020, Brazil (e-mail: dot.quadril@hotmail.com).

Rev Bras Ortop 2020;55(3):353–359.

Abstract

Objective The present paper aims to evaluate the influences of individual characteristics in radiographic magnification and to identify the most accurate method for radiographic calibration.

Methods During radiographical exam of 50 patients with hip prosthesis, anthropometric data was collected and 4 spherical metal markers with 25 mm diameters were positioned: at the greater trochanter level and lateral to it, over the pubic symphysis, between the thighs at the greater trochanter level, and over the exam table. Since the prosthesis head is the best internal radiographic marker for hip arthroplasty, it was our calibration parameter. Two examiners measured the markers' image for further analysis.

Results The sample consisted of 50 participants, 19 of whom were male. A difference in pubic symphysis magnification was found. Other individual characteristics (weight, height and body mass index) had weak correlation. The higher accuracy of the markers was at the greater trochanter, between 68.4 and 78.9%, visualized in only19 radiographs. The marker positioned between the thighs was visualized in all radiographs, with an accuracy ranging from 30 to 46%.

Conclusions Of all individual characteristics, only gender influences magnification at the pubic symphysis. We suggest the use of two spherical markers: at the greater trochanter, due the best accuracy, and between the thighs, considered the best positioning for better visibility.

Keywords

- arthroplasty, replacement, hip
- hip prosthesis
- radiography
- pelvis
- radiographic magnification

* *Work performed at the Grupo de Quadril do Departamento de Ortopedia e Traumatologia da Faculdade de Ciências Médicas Santa Casa de Misericórdia de São Paulo (FCMSCSP), São Paulo, SP, Brasil*

received
March 7, 2018
accepted
January 22, 2019

DOI https://doi.org/10.1055/s-0039-1693052.
ISSN 0102-3616.

Copyright © 2020 by Sociedade Brasileira de Ortopedia e Traumatologia. Published by Thieme Revnter Publicações Ltda, Rio de Janeiro, Brazil

License terms

Resumo

Objetivo Os objetivos desse artigo são avaliar as influências das características pessoais na magnificação radiográfica e identificar o método de maior acurácia e o mais adequado.

Métodos Durante o exame radiográfico em 50 pacientes com prótese de quadril, foram coletados dados antropométricos e posicionados quatro marcadores metálicos esféricos: ao nível e lateral ao trocânter maior, na sínfise púbica, ao nível do trocânter maior entre as coxas, sobre a mesa do exame. A cabeça da prótese é o melhor marcador radiográfico interno e foio nosso parâmetro de calibragem. Dois avaliadores mediram as imagens desses marcadores para análise de resultados.

Resultados Foram selecionados 50 participantes, sendo 19 do sexo masculino. Houve diferença de magnificação entre os sexos na posição sínfise púbica. As outras características pessoais avaliadas (peso, altura e índice de massa corpórea) tiveram correlação fraca. A maior acurácia do marcador foi no trocânter maior, entre 68,4 e 78,9%, visualizado em apenas 19 radiografias. O marcador entre as coxas obteve acurácia entre 30 e 46% e foi visualizado em todas radiografias.

Conclusão Das características pessoais, apenas o sexo influencia a magnificação e somente na posição da sínfise púbica. Sugerimos padronizar o uso de duas esferas: no trocanter maior, pela maior acurácia, e entre as coxas, por ser o mais adequado com melhor visibilidade em todas radiografias.

Palavras-chave

- artroplastia de quadril
- prótese de quadril
- radiografia
- pelve
- ampliação radiográfica

Introduction

Digital medical records, as well as imaging, are increasingly common in hospitals and clinics, sometimes replacing printed documentation altogether. In the professional practice of the orthopedist, both at the office and the hospital, the absence of printed exams is becoming more frequent. Radiological exams are usually stored electronically at a picture archiving and communication system (PACS) or recorded on compact disc (CD). This creates difficulties in preoperative planning, which can be solved by digital planning.

Preoperative planning is consolidated as the first step in predicting surgical procedure difficulties, component sizes and implant positioning for hip arthroplasty.[1–7] An adequate surgical planning reduces the number of complications associated with limb discrepancies, poor positioning, early implant release, instability, periprosthetic fracture and bone loss.[1–7] The use of transparencies provided by the prosthesis manufacturer with magnification, often ranging from 100 to 130%, is the best known and consolidated approach, but the reproducibility of the digital method is already confirmed, and it can be very useful when a printed test is lacking. The literature regarding the calibration procedure for the scanned radiographic examination in order to correct the magnification for proper templating, is controversial.

The most commonly used radiographic marker in scientific studies is the metal sphere,[9–12] but there are divergences regarding the ideal positioning for digital radiography calibration for hip arthroplasty planning. This study aims to identify the sphere positioning method with greater accuracy, to evaluate the influences of individual characteristics over outcomes, and to determine the most suitable method for practical use in order to minimize calibration errors.

Materials and Methods

This is a prospective cross-sectional study developed in Santa Casa de São Paulo Ortopaedic Department and approved by the institution research ethics committee (number 58564916.1.0000.5479).

To perform the study, a sample of 50 patients of both genders with total and/or partial hip prosthesis, both primary and revision, was established. These patients were invited to return to the service to perform a hip radiography as part of the postsurgery follow-up in October 2016. Images in which the prosthesis head diameter was not reported in the hospital records or which did not comply with radiographic standards were excluded from the study.[13]

Procedures

All included patients were submitted to a hip radiography in anteroposterior view and dorsal recumbency, with medial hip rotation between 15 and 20° and the incident ray over the median line, just above the pubic symphysis.[13] As standardization, the distance between the x-ray tube and the film was 100 cm, checked with tape measurement and the luminous indicator of the equipment Optimus 50 (Philips, Model Bucky Diagnost - Hamburg, Germany). For radiographic analysis, the alignment of the coccyx to the pubic symphysis was standardized with a distance of 2.5 cm between them in females, and 1.5 cm in males. The obturator foramina symmetry was also standardized for the same purpose.[13]

Prior to the radiographic examination, a single physician collected the anthropometric data and placed 4 25-mm steel spheres in 4 regions around the hip. The diameter of these spheres was confirmed with an analog caliper p-06, BE027249 (Suzano, São Paulo, Brazil) and a digital caliper

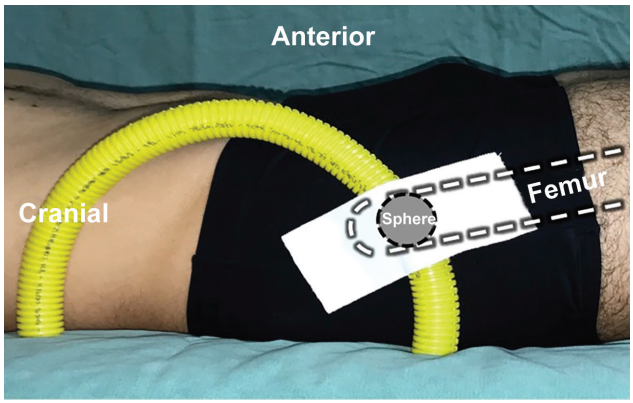

Fig. 1 Sphere positioning on the greater trochanter level, seen in lateral.

WesternPRO Model DC6, both certified by the Brazilian Institute of Metrology, Standardization and Industrial Quality (INMETRO, in the Portuguese acronym). Markers were positioned using a transparent, ¾ inch polyvinyl chloride (PVC) hose, as shown by Blake et al,[14] and a flexible, ¾ inch PVC electric plastic conduit. A longitudinal slit was created in the hose and the conduit for controlled sliding of the spheres. The markers were positioned at the following sites: 1 - right greater trochanter, next to the skin, with the sphere placed in the electric conduit (►**Figure 1**); 2 - between the patient's thighs, at the greater trochanter level, with the sphere in the hose as proximal as possible (►**Figure 2**); 3 - at the level of the anterior superior border of the pubic symphysis, fixed with adhesive tape (►**Figure 3**); 4 - at the examination table, 4 cm distal to the greater trochanter, fixed with adhesive tape (►**Figure 3**).

Imaging Analysis

The weight and height of each patient were recorded, as well as the gender, and record number to locate the radiographic examination and the size of the hip prosthesis head in the hospital data storage system. Digital imaging analysis was performed in IMPAX Orthopedic Tools planning software (AGFA HealthCare GmbH, Canton, MA, EUA) on a single HP Pavilion DV7 computer (Hewlett-Packard Company, Palo Alto, CA, EUA) .

Radiographs allowing the measurement of the prosthetic component head and at least two markers were considered. The evaluation was performed by two orthopedists, who received the same training in the correct use of the software. The first examiner performed two measurements, with a week interval between them. The second examiner performed only one measurement.

The image was calibrated with the identification of three peripheral points of the prosthesis head, whose diameter was known, at a joint-centered location and confirmed by the formation of a circle around the head.[9,15] After calibration, the measurement of the markers was performed with the identification of the three peripheral points and confirmed with a circle around each marker.

The software used in this study was not able to detect decimal millimeter values in marker measurements. In some images, the markers were visible, but analysis was impaired due to loss of circumference, as demonstrated by a previous study.[14] Partially visible or elongated markers were considered deformed. Spheres that were not seen within the limits of radiography were not calculated.

Statistical Analysis

The confidence intervals (CIs) from this study were constructed with 95% statistical confidence. The sample, with N greater than 30 participants, guarantees a trend to normal distribution through the central limit theorem; in addition, the sample power was verified. The anthropometric characteristics of the sample were described using means and standard deviations (SDs), as well as absolute and relative frequencies.

The equality of two proportions test was applied to characterize the distribution of the relative frequency of qualitative variables. The two-tailed Student t-test was used (when the

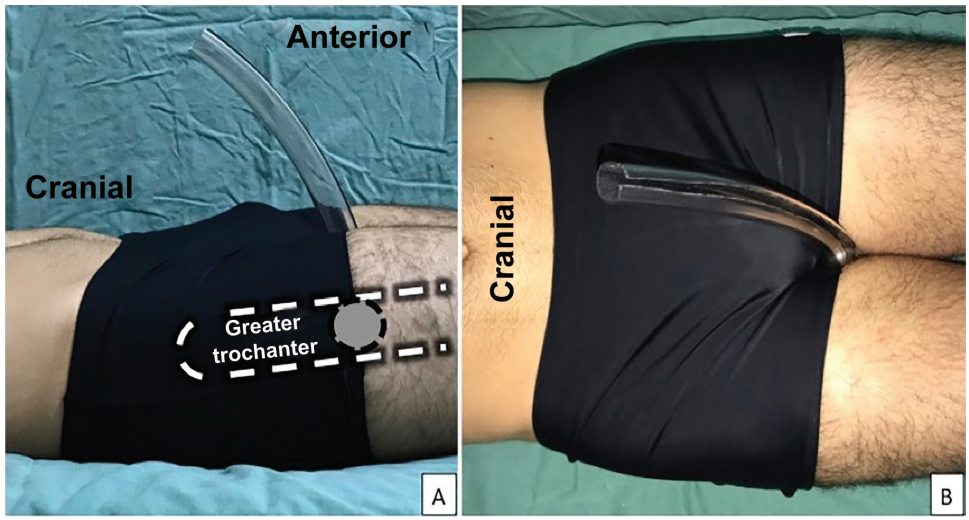

Fig. 2 Sphere positioning between the thighs, at the greater trochanter level, seen in lateral (A) and anterior view (B).

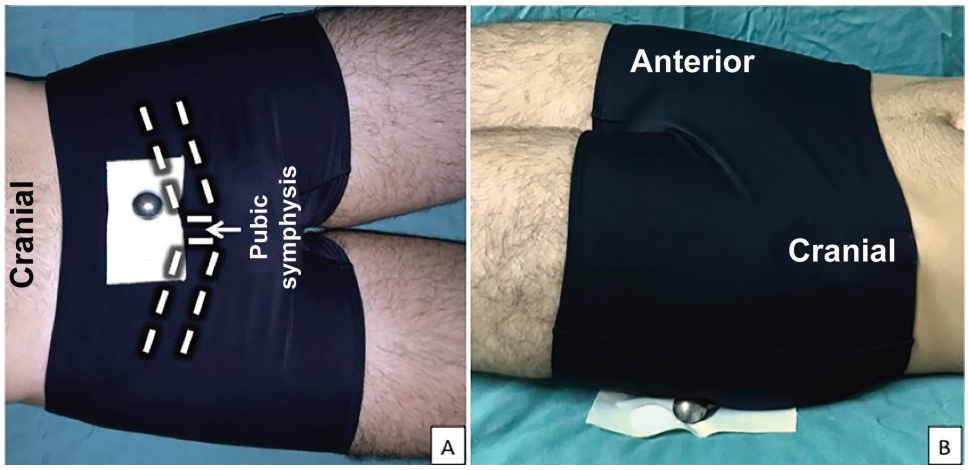

Fig. 3 Sphere positioning in the pubic symphysis (A); Sphere positioning on the examination table, at the left side of the patient (B).

subject is both a research item and its control) to compare the first and second evaluation of examiner 1 in each position. Means, SDs, coefficients of variation (CVs) (which evaluates the variability of the mean), and minimum and maximum values of each evaluation were calculated. The t-Student one-sample test was used to compare the mean at each position for each examiner's assessment to the 25-mm reference value. The accuracy of mean values at each position in each evaluation was calculated using a reference value of exactly 25 mm.

Analysis of variance (ANOVA), Pearson, Chi-Square, and correlation tests were used to compare the results, and a statistical model predicted the appearance of the marker in the greater trochanter site, which was confirmed with logistic regression tests.

The analyses were performed with the SPSS Windows software version 20.0 (IBM Corp., Armonk, NY, USA), Minitab 16 (Minitab, LLC, State College, PA, EUA), and Microsoft Excel 2010 (Microsoft Corp., Redmond, WA, USA); according to the literature, tests were performed with a significance level of 5%.[16–19]

Results

►**Table 1** shows the anthropometric variables of the sample, which was considered homogeneous since the coefficient of variation (CV) values were lower than 50%, indicating low variability.

►**Table 2** presents the Pearson correlation data between placements and the anthropometric variables in the sample. These correlations were considered bad and can be virtually disregarded.

The deformation of visible markers was observed: 68.4% (4 men and 9 women) in the "greater trochanter" position, 38% (9 men and 10 women) between the thighs and only 10% (2 men and 3 women) at the examination table. There was no deformation in the pubic symphysis position. The marker in the greater trochanter was the only one with losses, as it was not viewed in 31 radiographs (62%), 21 of which were from female patients (67.7%) and 10 from male patients (52.6%). ►**Table 3** presents the comparison between the sphere visualization in the greater trochanter and the anthropometric variables of the sample.

In total, the sample consisted in 31 female participants (62%) and 19 male participants (38%), with a statistical significance ($p = 0.016$). A difference between genders was found by examiner 1 in the pubic symphysis position ($p = 0.011$), in which the female and male mean values were, respectively, 27.7 mm and 28.3 mm.

Table 1 Complete description of anthropometric variables

	Mean	Standard deviation	CV	Minimum–Maximum	CI
Weight (Kg)	72.1	15.2	21%	45–110	4.2
Height (m)	1.61	0.10	6%	1.38–1.92	4.2
BMI (Kg/m^2)	27.7	5.0	18%	16.1–43.0	1.4

Abbreviations: Kg, kilogram; m, meter; BMI, body mass index; CI, confidence interval; CV, coefficient of variation.

Table 2 Correlation of anthropometric variables according to the findings of examiner 1 in the 1st evaluation

Examiner 1		Weight	Height	BMI
Greater trochanter	Corr (r)	-15.2%	12.0%	-18.6%
	P-value	0.535	0.624	0.446
Between the thighs	Corr (r)	29.2%	22.4%	18.0%
	P-value	0.039	0.119	0.211
Pubic symphysis	Corr (r)	38.7%	22.6%	28.2%
	P-value	0.005	0.114	0.048
Examination table	Corr (r)	-20.3%	-13.3%	-15.7%
	P-value	0.157	0.358	0.277

Abbreviations: Corr (r), correlation; BMI, body mass index; kg, kilogram; m, meter.

Table 3 Comparison between the visualization of the marker in the greater trochanter position with the anthropometric variables

Right trochanter		Mean	Standard deviation	CV	Minimum	Maximum	n	CI	*P*-value
Weight (Kg)	Visible	62.4	12.1	19%	45	86	19	5.4	< 0.001
	Not visible	78.1	14.0	18%	56	110	31	4.9	
Height (m)	Visible	1.59	0.08	5%	1.45	1.70	19	0.04	0.185
	Not visible	1.63	0.11	7%	1.38	1.92	31	0.04	
BMI (Kg/m^2)	Visible	24.8	4.7	19%	16.1	33.3	19	2.1	0.001
	Not visible	29.5	4.3	15%	23.2	43.0	31	1.5	

Abbreviations: Kg, kilogram; m, meter; BMI, body mass index; CI, confidence interval; CV, coefficient of variation; n, sample.

Table 4 Comparison between position/evaluation and the actual size (25 mm)

Position		Mean (mm)	Standard deviation	CV	Minimum (mm)	Maximum (mm)	n	CI	*P*-value
Examiner 1 at the 1st evaluation	Greater trochanter	25.00	0.58	2%	24	26	19	0.26	1.000
	Between the thighs	25.40	0.67	3%	23	26	50	0.19	< 0.001
	Pubic symphysis	27.96	0.67	2%	26	29	50	0.19	< 0.001
	Examination table	23.18	0.52	2%	21	24	50	0.14	< 0.001
Examiner 1 at the 2nd evaluation	Greater trochanter	25.05	0.52	2%	24	26	19	0.24	0.667
	Between the thighs	25.46	0.65	3%	23	26	50	0.18	<0.001
	Pubic symphysis	28.02	0.62	2%	26	29	50	0.17	< 0.001
	Examination table	23.14	0.50	2%	21	24	50	0.14	< 0.001
Examiner 2 at the single evaluation	Greater trochanter	24.95	0.62	2%	23	26	19	0.28	0.716
	Between the thighs	25.62	0.75	3%	24	27	50	0.21	< 0.001
	Pubic symphysis	27.98	0.65	2%	26	29	50	0.18	< 0.001
	Examination table	23.36	0.53	2%	22	24	50	0.15	< 0.001

Abbreviations: mm, millimeter; CV, coefficient of variation; IC, confidence interval; n, sample; p value, significance.

There was no statistical difference comparing examiner evaluations with the two-tailed Student t-test, indicating that the measurements were reliable. The comparison of the examiners' evaluations in relation to the actual size is showed in ►**Table 4**.

The position with greater accuracy in identifying the real value (25 mm) was in the greater trochanter in all evaluations, but with a large sample loss, visible in only 19 radiographs, as shown in ►**Table 5**. The position between the thighs has a smaller accuracy, but with no sample loss.

The marker in the examination table position reached a precision between 76 and 80% for the 23-mm value; meanwhile, in the pubic symphysis, accuracy ranged from 62 to 68% for the 28-mm value. Both markers were visualized on all radiographs (n = 50).

The only significant variable ($p = 0.03$) in predicting the presence of the sphere in the greater trochanter position was the female gender. This variable was analyzed with logistic regression and considered good by the adhesion test, with a concordance percentage of 84.6% in the logistic regression test.

Table 5 Accuracy of 25 mm in the positions per evaluation

Accuracy in position	Examiner 1 at the 1st evaluation		Examiner 1 at the 2nd evaluation		Examiner 2		Total
	n25	Accuracy	n25	Accuracy	n25	Accuracy	n
Greater trochanter	13	68.4%	14	73.7%	15	78.9%	19
Between the thighs	23	46.0%	22	44.0%	15	30.0%	50
Pubic symphysis	0	0.0%	0	0.0%	0	0.0%	50
Examination table	0	0.0%	0	0.0%	0	0.0%	50

Abbreviations: n25, sample with exact measurement of 25 millimeters; n, sample number.

Discussion

The most accurate method was greater trochanter positioning, whereas the second most accurate method was positioning between the thighs. Because there is a 62% loss of images in the greater trochanter, we suggest using these two markers at the same time. According to the results, the positioning between the patient's thighs may be considered the most appropriate technique for practical use, since, despite deformation in 38% of the cases, the image was visible in 100% of the radiographs, and the mean measurement was close to the actual size, within the acceptable range of + 3% and - 3%.[20]

The female gender was considered the only significant variable to predict the presence of a greater trochanter marker image. This may be due to the difference of the sample with no greater trochanter marker image because, from a total of 31 radiographs (62%), 21 patients were female (67.7%) and 10 were male (52.6%). The pattern of posterolateral fat accumulation of the female hip may be related to this result.

Studies that analyze radiographs for arthroplasty planning use different positioning methods and markers without justifying the choice for positioning between the thighs or at the greater trochanter level.[6,11,14,15,21] Gamble et al[8] did not specify the technique, only indicating the region. Kosashvili et al[22] did not use any marker and only standardized the magnification at 115% for practical purposes, with little interference in the final result. This exemplifies the lack of standardization in the magnification correction method and marker positioning.

Knowing that the cone of x-ray emission starts from the central point of the image and acts in a similar way bilaterally, therefore without any difference between the sides of the patient,[21] we decided to place the sphere at the right greater trochanter to standardize the examination, minimizing possible errors of confusion between this positioning and the sphere placed on the examination table.

The sphere placed in the greater trochanter presented difficulty factors for the examination. When visible, it was close to its full size, with an average of 25 mm, but it was not visible in 62% (31) of the radiographs; this may indicate technical difficulty with such positioning, already noted by other authors.[12] The high deformation rate of 68.4% of the images visible in this position (13 out of 19 radiographs) appeared to be a difficulty factor during the measurement phase, but it was not statistically identified. These difficulties may imply the need to perform multiple radiographs to fit the examination, and may influence the calibration: decentralization of the radiographic beam to the side of the marker or its placement above or below the greater trochanter level to avoid it being pushed laterally by the fatty cushion of the posterolateral thigh. Some authors[8,10–12,21] analyzed the relationship between weight and/or body mass index (BMI) with radiographic magnification, without identifying significant results; however, in this study, there was a correlation, deemed poor, of these factors with the absence of the marker at the greater trochanter, which can be virtually disregarded.

The sphere positioned between the thighs was visualized on all radiographs. The measurements were, on average, very close to the actual size, within the range of acceptable error, between + 3% and - 3%[12] with accuracy between 30 and 46%. The 38% deformation rate (19 radiographs), considered in this study as a difficulty factor for measurement, was lower than in the greater trochanter position. This method uses low-cost, readily available materials to radiology services.[13] The positioning technique is simple and commonly used, but it also has bias. In addition to the discomfort of positioning in the genital region, the image is more distal in male patients compared to female patients, which increased deformation; deformation rates were 47.4% (9 out of 19) in men and 32.3% (10 out of 31) in women. In addition, the radiographic analysis showed that the artifact generated by the PVC tube was also a deforming factor for the spheres.

The sphere positioned at the pubic symphysis is used by some orthopedists, but this is not a consolidated technique in the literature. This sphere was visualized on all radiographs, with no deformation. The positioning is simple but suffers measurement variation with gender and it has poor correlation with weight and BMI. Another negative point of this positioning is the average of the measurements, 28 mm, therefore enlarged compared to the actual size and with 0% accuracy compared to the actual size.

The sphere placed on the examination table is another technique that is not addressed in the main studies on radiographic markers. This sphere was visualized on all radiographs, and only 10% of the images were deformed. It reached the lowest statistical variation among measurements, evidenced by a CI value of 0.14; as such, it is deemed a stable method. The mean value of the measurements is lower than 25 mm, with a 0% accuracy when compared to the actual size. Eventually, the image of this sphere overlaps the femoral stem and may impair the careful radiographic evaluation at this level, which does not occur in other positions.

Conclusion

For the preoperative calibration of hip arthroplasty with a spherical marker, the most accurate positioning method is next to the greater trochanter, whereas the most appropriate method is between the thighs (both at the hip joint level). We suggest using these two markers simultaneously to avoid repetition of the radiographic examination and to allow accurate calibration.

There is a poor relation of weight and BMI with the absence of the marker at the greater trochanter position, while height has no relation to its absence. The female gender was identified as the only significant variable of preference for the radiographic appearance of the marker at the greater trochanter

Conflict of Interests
The authors declare that have no conflict of interests.

References

1 Muller ME. Total hip replacement: planning, technique and complications. In: Cruess RL, Mitchell NS. Surgical management of degenerative arthritis of the lower limb. Philadelphia: Lea and Faber; 1975:90–113
2 Müller ME. Lessons of 30 years of total hip arthroplasty. Clin Orthop Relat Res 1992;(274):12–21
3 Knight JL, Atwater RD. Preoperative planning for total hip arthroplasty. Quantitating its utility and precision. J Arthroplasty 1992; 7(Suppl):403–409
4 Hoikka V, Paavilainen T, Lindholm TS, Turula KB, Ylikoski M. Measurement and restoration of equality in length of the lower limbs in total hip replacement. Skeletal Radiol 1987;16(06): 442–446
5 Eggli S, Pisan M, Müller ME. The value of preoperative planning for total hip arthroplasty. J Bone Joint Surg Br 1998;80(03): 382–390
6 Baghdadi YM, Larson AN, Sierra RJ. Restoration of the hip center during THA performed for protrusio acetabuli is associated with better implant survival. Clin Orthop Relat Res 2013;471(10): 3251–3259
7 Miashiro EH, Fujiki EN, Yamaguchi EN, et al. Preoperative planning of primary total hip arthroplasty using conventional radiographs. Rev Bras Ortop 2014;49(02):140–148
8 Gamble P, de Beer J, Petruccelli D, Winemaker M. The accuracy of digital templating in uncemented total hip arthroplasty. J Arthroplasty 2010;25(04):529–532
9 The B, Verdonschot N, van Horn JR, van Ooijen PM, Diercks RL. Digital versus analogue preoperative planning of total hip arthroplasties: a randomized clinical trial of 210 total hip arthroplasties. J Arthroplasty 2007;22(06):866–870
10 Heep H, Xu J, Löchteken C, Wedemeyer C. A simple and convenient method guide to determine the magnification of digital X-rays for preoperative planning in total hip arthroplasty. Orthop Rev (Pavia) 2012;4(01):e12
11 Archibeck MJ, Cummins T, Tripuraneni KR, et al. Inaccuracies in the use of magnification markers in digital hip radiographs. Clin Orthop Relat Res 2016;474(08):1812–1817
12 Franken M, Grimm B, Heyligers I. A comparison of four systems for calibration when templating for total hip replacement with digital radiography. J Bone Joint Surg Br 2010;92(01):136–141
13 Polesello GC, Nakao TS, Queiroz MC, et al. Proposta de padronização do estudo radiográfico do quadril e da pelve. Rev Bras Ortop 2011; 46(06):634–642
14 Blake CA, van der Merwe J, Raubenheimer JE. A practical way to calibrate digital radiographs in hip arthroplasty. SA Orthop J 2013; 12(04):33–7. Disponível em: http://www.scielo.org.za/scielo.php?script=sci_arttext&pid=S1681-150×2013000500006&lng=en
15 Heinert G, Hendricks J, Loeffler MD. Digital templating in hip replacement with and without radiological markers. J Bone Joint Surg Br 2009;91(04):459–462
16 Altman DG, Bland JM. Measurement in medicine: the analysis of method comparison studies. Statistician 1983;32(03):307–317
17 Fleiss JL. The design and analysis of clinical experiments. New York: Wiley; 1986
18 Kirkwood BR, Sterne JA. Essential medical statistics. 2nd ed. Massachusetts: Blackwell Science; 2006
19 Streiner DL, Norman GR. Health measurement scales: a practical guide to their development and use. 2nd Ed. New York: Oxford University Press Inc.; 1995
20 The B, Diercks RL, Stewart RE, van Ooijen PM, van Horn JR. Digital correction of magnification in pelvic x rays for preoperative planning of hip joint replacements: theoretical development and clinical results of a new protocol. Med Phys 2005;32(08):2580–2589
21 Wimsey S, Pickard R, Shaw G. Accurate scaling of digital radiographs of the pelvis. A prospective trial of two methods. J Bone Joint Surg Br 2006;88(11):1508–1512
22 Kosashvili Y, Shasha N, Olschewski E, et al. Digital versus conventional templating techniques in preoperative planning for total hip arthroplasty. Can J Surg 2009;52(01):6–11