Comparative Evaluation of Cross-table and Ducroquet Incidences for Measurement of the Hip Alpha Angle*

Avaliação comparativa das incidências radiográficas cross-table e Ducroquet para a medição do ângulo alfa do quadril

Giancarlo Cavalli Polesello[1] Marcelo Cavalheiro Queiroz[1] Walter Ricioli Junior[1] Marco Rudelli[1] Marcus Aurelius Araújo Nunes[1] Denise Tokechi Amaral[2]

[1] Hip Group, Orthopedics and Traumatology Department, Faculdade de Ciências Médicas da Santa Casa de São Paulo (FCMSCSP), Irmandade Santa Casa de Misericórdia, São Paulo, SP, Brazil
[2] Radiology Service, Hospital Sírio Libanês, São Paulo, SP, Brazil

Address for correspondence Giancarlo Cavalli Polesello, MD, PhD, Rua Dr. Cesário Mota Júnior, 112, Bairro Vila Buarque, São Paulo, SP, 01221-020, Brazil (e-mail: dot.quadril@hotmail.com).

Rev Bras Ortop 2019;54:428–433.

Abstract

Objective The purpose of the present paper is to compare the equivalence of the measurement of the alpha angle using the Ducroquet and cross-table lateral views.

Methods We have recruited 90 patients, resulting in 95 hips. We have standardized the realization of the radiographic views. The incidence of the lateral cross-table views were taken with 15° of internal rotation with the patient in the supine position, and the incidence of the Ducroquet views was standardized with the patient in the supine position, with 90° of flexion and 45° of abduction of the hip. The alpha angle was measured in both lateral views, by two musculoskeletal radiologists. The measurements were performed in 2 different times: an initial evaluation and another 4 weeks afterwards. The t Student test was used and calculated the intraclass correlation coefficient (ICC).

Results We have found a good intraobserver correlation for both views in different times; there was no statistically significant difference between the measurements performed by the two views. However, the interobserver correlation was low.

Conclusion In conclusion, the Ducroquet profile view is a good choice for the α angle measurement and can be used instead of the cross-table view.

Keywords
- femoroacetabular impingement
- hip/abnormalities
- hip/diagnostic imaging
- radiography

Resumo

Objetivo O objetivo do presente trabalho é comparar a equivalência da medida do ângulo alfa do quadril usando as incidências laterais de Ducroquet e de cross-table.

Método Estudamos 90 pacientes, com um total de 95 quadris, e padronizamos a realização das radiografias conhecidas como "Ducroquet" e "cross-table." A incidência de perfil de cross-table foi realizada em 15° de rotação interna com o paciente em

* Work performed at the Hip Group, Orthopedics and Traumatology Department, Irmandade Santa Casa de Misericórdia, Faculdade de Ciências Médicas da Santa Casa de São Paulo (FCMSCSP), São Paulo, SP, Brazil.

Giancarlo Cavalli Polesello's ORCID is https://orcid.org/0000-0002-95248871.

received
March 5, 2019
accepted
January 22, 2019

DOI https://doi.org/10.1055/s-0039-1693044.
ISSN 0102-3616.

Copyright © 2019 by Sociedade Brasileira de Ortopedia e Traumatologia. Published by Thieme Revnter Publicações Ltda, Rio de Janeiro, Brazil

License terms

posição supina, e a incidência de perfil de Ducroquet foi padronizada com o paciente posicionado em decúbito dorsal, em 90° de flexão e 45° de abdução do quadril. O ângulo alfa foi medido em ambas as radiografias de perfil, por dois radiologistas especializados em afecções musculoesqueléticas. As medidas foram realizadas em 2 épocas diferentes: uma avaliação inicial e outra após 4 semanas. O teste t de Student foi utilizado e calculou o coeficiente de correlação intraclasse (CCI).

Resultados Encontramos boa correlação intraobservador para ambas as incidências radiográficas em diferentes momentos. Não houve diferença estatisticamente significante entre as medidas feitas pelas duas visualizações. No entanto, a correlação interobservadores foi baixa.

Conclusão A incidência radiográfica de perfil de Ducroquet é uma boa opção para a medida do ângulo alfa e pode ser usada ao invés da incidência radiográfica de perfil cross-table.

Palavras-chave
- impacto femoroacetabular
- quadril/anormalidades
- quadril/diagnóstico por imagem
- radiografia

Introduction

Femoroacetabular impingement (FAI) is a well-established entity in world orthopedics.[1–6] It is considered one of the main mechanically originated processes resulting in hip arthrosis.[1,3,4,6–9] Its diagnosis is aided by well-defined radiographic parameters.[2,4,10] Most of the morphological alterations of this condition are not visible in anteroposterior hip radiographies.[2–4] Profile views demonstrate better the nonspherical portion of the femoral neck and the deformities caused by FAI.[8,9,11–13]

This nonspherical portion of the femoral head-neck joint can be measured with the alpha angle (Nötzli angle).[8,12] The alpha angle is formed by a line drawn through the center of the femoral head, following the femoral neck axis, and another line connecting the center of the femoral head to the point where the femoral head protrudes beyond a circle drawn around the femoral head (the point where the femoral head sphericity ends).[8,12] In its original description, the angle was measured on oblique axial magnetic resonance imaging (MRI).

Several profile views were described to investigate femoral neck abnormalities, but the most commonly used is the cross-table view.[5,6,14] The Ducroquet profile view is another option, easy to perform regardless of the table and requiring only 90° flexion and 30° to 45° abduction.[12] Since it is technically easy, including intraoperatively during hip arthroscopy, it is our imaging of choice to evaluate the alpha angle.

The present study aims to compare the equivalence of the measurement of the alpha angle using the Ducroquet and cross-table views.

Materials and Methods

This is a prospective study performed at the Department of Orthopedics and Traumatology of at Santa Casa de Misericórdia de São Paulo Medical School from January 2008 to April 2010. A total of 90 patients were recruited, resulting in 95 hips, which were voluntarily selected and radiographed in the Ducroquet and cross-table views. Informed consent was obtained from all of the patients, and the study was approved by the Institutional Review Board under the number 240/09.

Radiographies

The radiographic views were standardized. All of the views were performed by the same technicians, using the same technique, and were supervised by an orthopedist. The cross-table view (►**Figs. 1A** and **1B**) was obtained with the patient in the supine position, with the studied lower limb in 15° internal rotation and the contralateral limb in 90° flexion to avoid image interposition, as recommended by the technique, whereas the Ducroquet view (►**Figs. 1C** and **1D**) was standardized with the patient in dorsal recumbency, 90° flexion, and 45° abduction of the affected hip, in neutral rotation.

Radiographic Measurement

The alpha angle (Nötzli angle)[8,12] was determined on both profile views by two musculoskeletal radiologists using the same measurement techniques.[8,13] The angle was measured digitally with the Image software, version 1.37 (National Institutes of Health, Bethesda, MD, USA).

The measurements were performed at two different time points: at the initial evaluation (referred as "pre") and 4 weeks afterwards (referred as "post"). The statistical analysis was performed with a summary of variables, boxplot graphs, and scatter diagrams. The Student t-test was used, and the intraclass correlation coefficient (ICC) was calculated with PASW Statistics for Windows, Version 10.0 (SPSS Inc., Chicago, IL, USA). The level of significance was determined at 0.05 (5%).

Results

The measurements of the alpha angle were similar for both observers at the two time points, that is, at baseline and after 4 weeks (►**Fig. 2** and ►**Table 1**).

The following analysis was performed:

A) To compare the results from observers 1 and 2 for each radiographic view in the 1st and 2nd evaluation (pre and post).

Regarding the analysis among observers:

A.1) Cross-table: there was a disparity between the observers 1 and 2 at the pre-evaluation (►**Table 2** and ►**Fig. 3A**) and at the postevaluation (►**Table 2** and ►**Fig. 3B**).

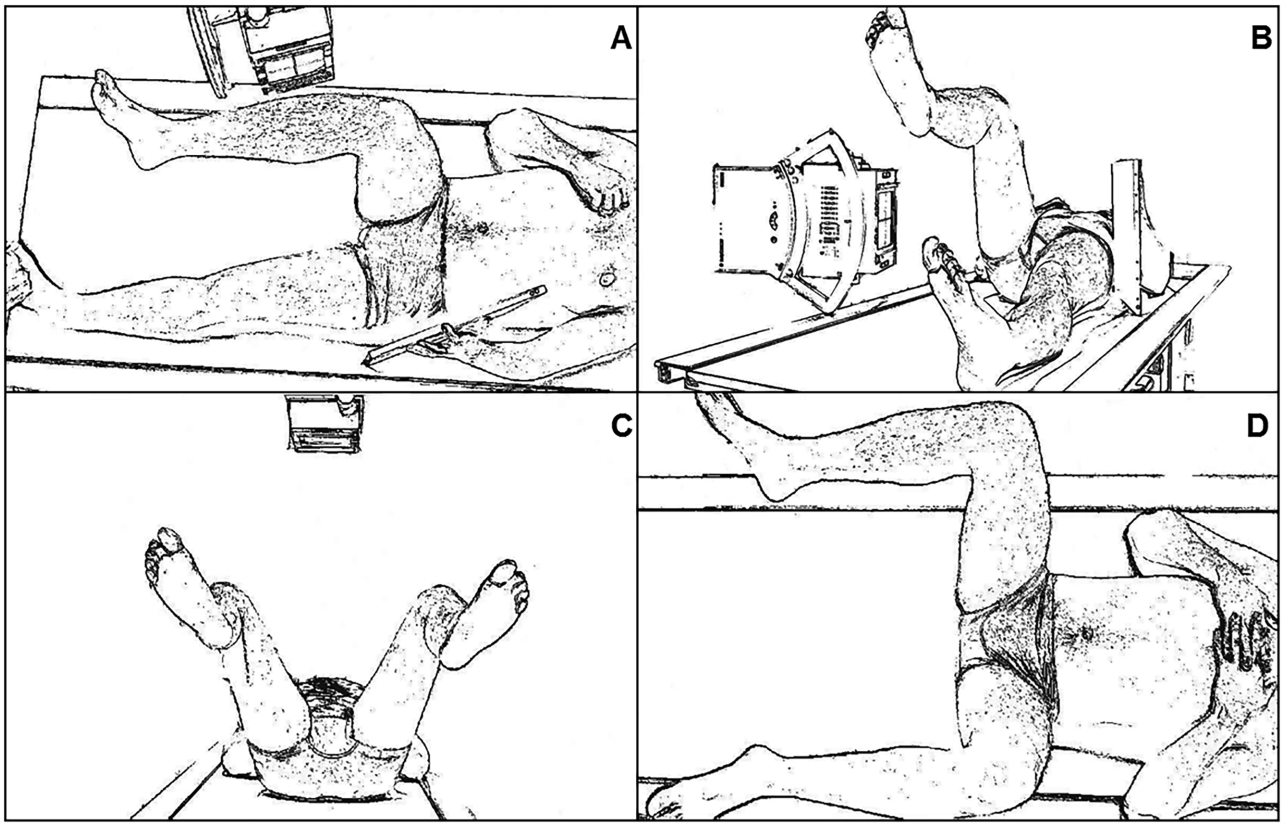

Fig. 1 (A and B). Cross-table view positioning; (C and D). Ducroquet view positioning.

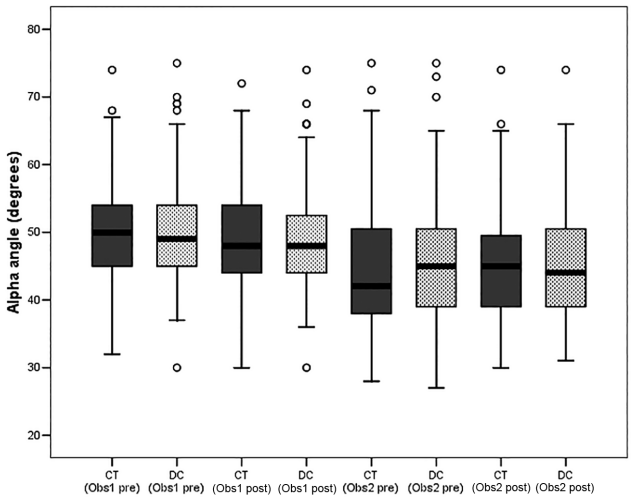

Fig. 2 Boxplot graph of hip angle measurements made by two different observers in two different views (Ducroquet and Cross-table) and two different time points (pre and post). Pre: Initial measurements. Post: measurements after 4 weeks. CT: Cross-Table view. DC: Ducroquet view. Obs1: Observer 1. Obs2: Observer 2.

A.2) Ducroquet: there was disparity between observers 1 and 2 at the pre-evaluation (►**Table 2** and ►**Fig. 3C**) and at the postevaluation (►**Table 2** and ►**Fig. 3D**). There was a statistically significant difference ($p = 0.000$) between measurements between observers for both incidences at both time points.

Table 1 Radiographic measurements of the alpha angle of the hip by two different observers with two different views (Ducroquet and cross-table) and two different times (pre and post).

Observer	Radiographic View	Time	Mean (°) ± SD	Median (°)
1	Cross-Table	pre	49.8 ± 7.43	50.1
		post	49 ± 7.31	48.5
1	Ducroquet	pre	50.2 ± 8.32	49.8
		post	48 ± 7.89	48.2
2	Cross-Table	pre	44.9 ± 9.77	42.3
		post	45.4 ± 8.68	45.5
2	Ducroquet	pre	45.2 ± 9.22	45.2
		post	44.9 ± 7.88	44.4

Abbreviations: post, measurements after 4 weeks; pre, initial measurements; SD, standard deviation.

B) To compare the correlation of the measurements of the cross-table and Ducroquet views for each observer at both time points.

B.1) There was little disparity between observers 1 and 2 in the measurements of the hip angles in both views at the same time (►**Table 2** and ►**Fig. 4A**): observer 1, 1st measurement; ►**Table 2** and ►**Fig. 4B**: observer 1, 2nd measurement; ►**Table 2** and ►**Fig. 4C**: observer 2, 1st measurement; ►**Table 2** and ►**Fig. 4D**: observer 2, 2nd measurement.

Table 2 Intraclass correlation coefficients of the measurements the alpha angle of the hip by two observers at the cross-table and Ducroquet views.

Analysis	Intraclass Correlation Coefficients	95%CI
CT Obs1 (pre) x CT Obs2 (pre)	0.588	0.381–0.726
CT Obs1 (post) x CT Obs2 (post)	0.653	0.397–0.790
DC Obs1 (pre) x DC Obs2 (pre)	0.578	0.226–0.754
DC Obs1 (post) x DC Obs2 (post)	0.718	0.405–0.847
CT Obs1 (pre) x DC Obs1 (pre)	0.938	0.907–0.959
CT Obs1 (post) x DC Obs1 (post)	0.969	0.954–0.979
CT Obs2 (pre) x DC Obs2 (pre)	0.862	0.793–0.908
CT Obs2 (post) x DC Obs2 (post)	0.945	0.918–0.964

Abbreviations: CI, confidence interval; CT, cross-table; DC, Ducroquet; post, measurements after 4 weeks; pre, initial measurements; Obs1, Observer 1; Obs2, Observer 2.

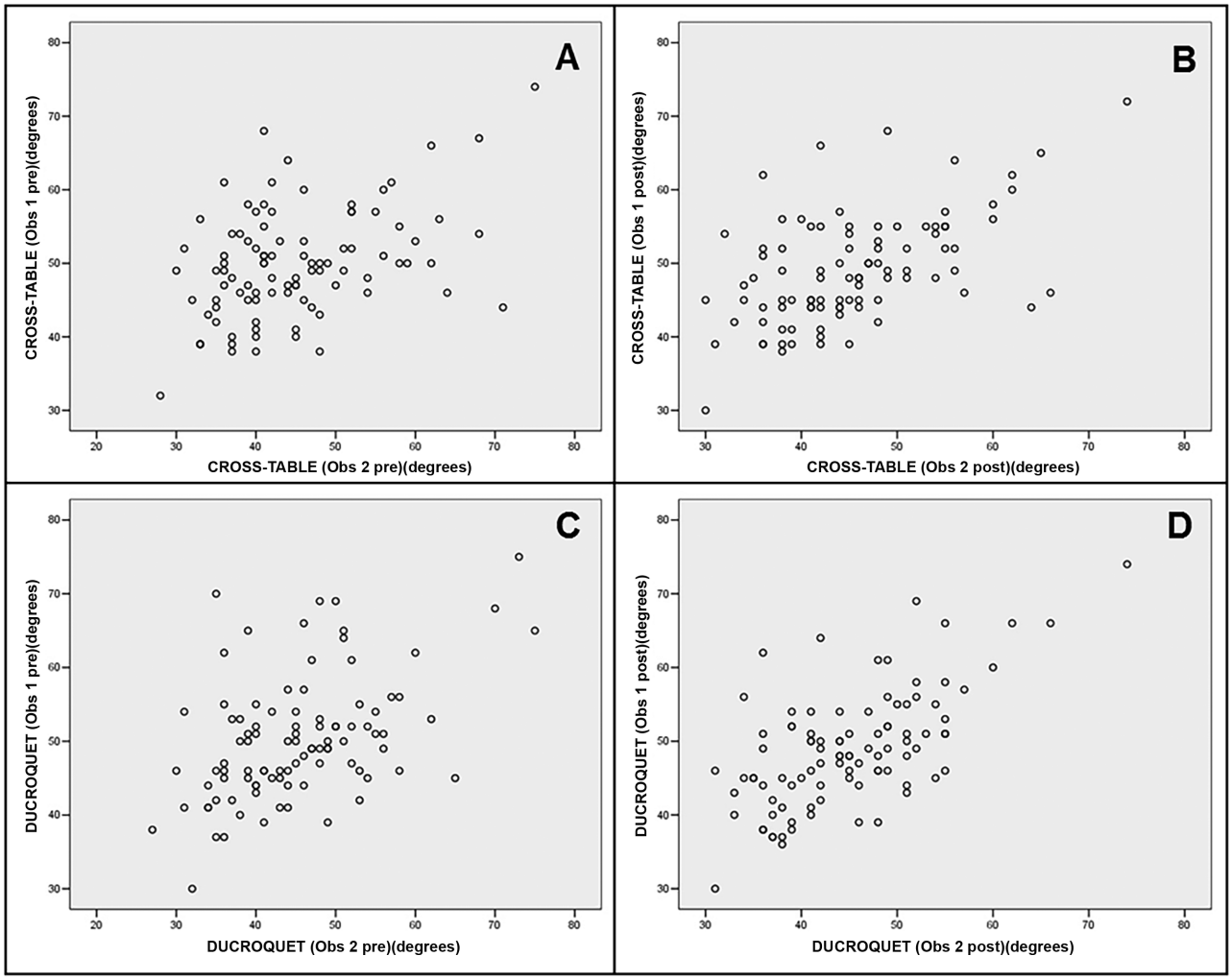

Fig. 3 (**A**) Correlation of the initial measurements of the alpha angle of the hip made by two different observers with the cross-table view. Pre: initial measurements; (**B**) Correlation of the 2nd measurements of the alpha angle of the hip made by 2 different observers with the cross-table view. Post: measurements after four weeks; (**C**) Correlation of the initial measurements of the alpha angle of the hip made by two different observers with the Ducroquet view. Pre: initial measurements; (**D**) Correlation of the 2nd measurements of the alpha angle of the hip made by 2 different observers with the Ducroquet view. Post: measurements after 4 weeks.

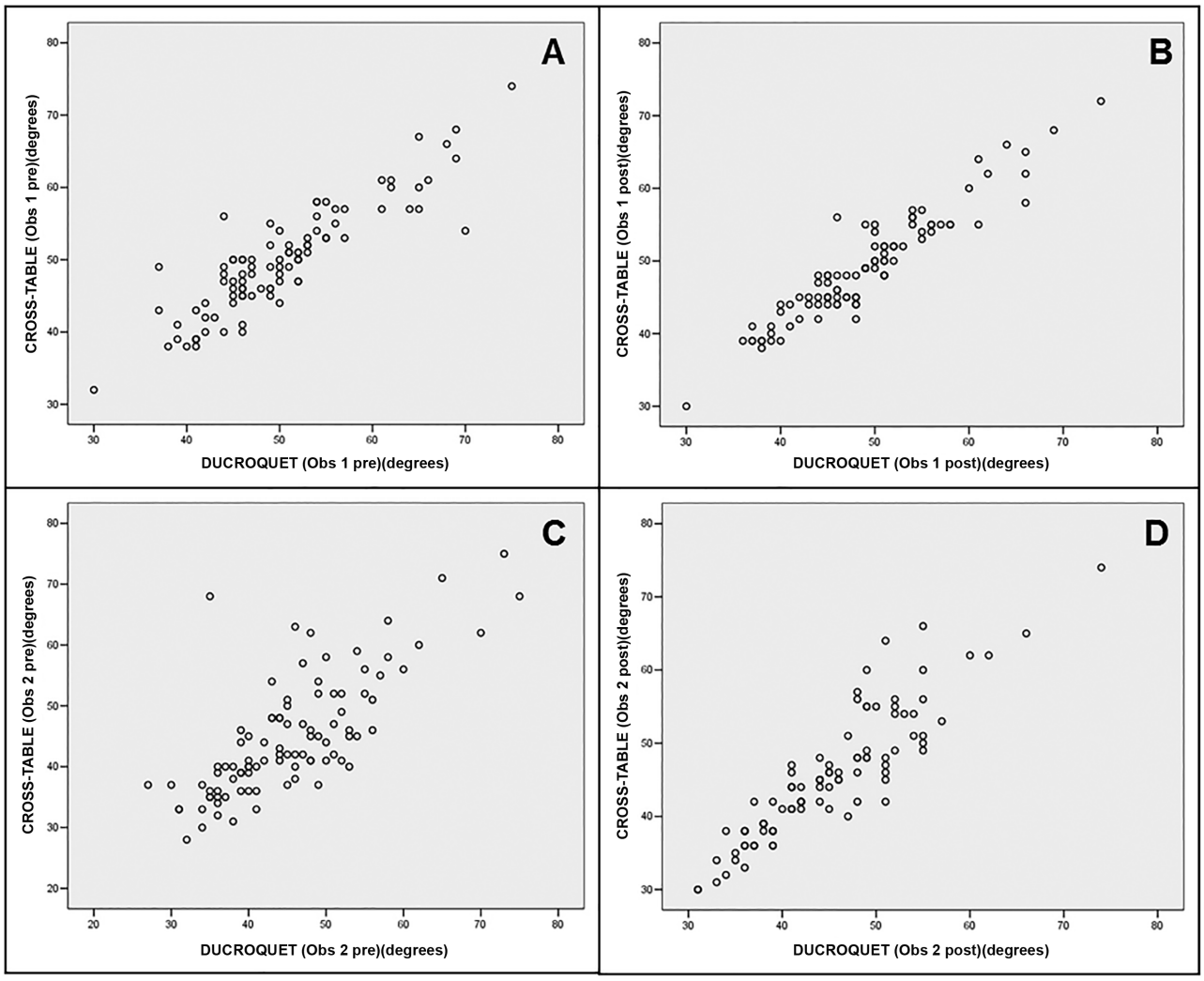

Fig. 4 (A) Correlation of the initial measurements of the alpha angle of the hip made by observer 1 with the cross-table and Ducroquet views. Pre: Initial measurements. Obs1: observer 1; (B) Correlation of the 2nd measurements of the alpha angle of the hip made by observer 1 with the cross-table and Ducroquet views. Post: measurements after 4 weeks. Obs1: observer 1; (C) Correlation of the initial measurements of the alpha angle of the hip made by the observer 2 with the cross-table and Ducroquet views. Pre: Initial measurements. Obs2: observer 2; (D) Correlation of the 2nd measurements of the alpha angle of th hip made by the observer 2 with the cross-table and Ducroquet views. Post: measurements after 4 weeks. Obs2: Observer 2.

Table 3 Intraobserver analysis of the measurements of the alpha angle of the hip at two different views (Ducroquet and cross-table) and two different times (pre and post).

Analysis		*p-value*
1	Cross-table (Obs1 pre) – Ducrocquet (Obs1 pre)	0.309
2	Cross-table (Obs2 pre) – Ducrocquet (Obs2 pre)	0.611
3	Cross-table (Obs1 post) – Ducrocquet (Obs1 post)	0.699
4	Cross-table (Obs2 post) – Ducrocquet (Obs2 post)	0.223

Abbreviations: post, measurements after 4 weeks; pre, initial measurements; Obs1, Observer 1; Obs2, Observer 2.

There was no statistically significant difference ($p > 0.05$) in the alpha angle measured on both radiographic views by the same observer at the same time (►**Table 3**).

Discussion

Comparing the measurement of the alpha angle by two observers using the Ducroquet and cross-table radiographic views, we observed good intraobserver correlation, but low interobserver correlation.

The diagnosis of the subtle changes that may cause early hip coxarthrosis is evolving in the last few years.[15] Radiographs are valuable for the detection of femoral and acetabular morphological changes.[4,11,12]

The alpha angle (Nötzli angle) is often used to diagnose pathological deformities of the femoral neck.[6,8,12,13,16]

There are controversies as to the ideal view for alpha angle measurement. Meyer et al[13] compared 6 radiographic views (anteroposterior, Dunn, Dunn with 45° of flexion, cross-table with 15° of internal rotation, cross-table in neutral rotation, and cross-table with 15° of external rotation). They concluded that the Dunn view at 45° or 90° of flexion or the cross-table view with internal rotation are better at detecting changes in

the sphericity of the femoral head-to-neck transition; in addition, the authors noted that the anteroposterior and cross-table views with external rotation are not able to detect these changes.

The Ducroquet view is easy to perform and represents the true profile of the proximal femoral end, perfectly showing the transition between the neck and the femoral head.[11,12] Moreover, this view is useful for intraoperative control during femoral osteoplasty, since it allows obtaining profile images without moving the fluoroscopy arm.

The cross-table profile technique also provides a true view of the femoral neck; in addition, it allows the visualization of the accessory acetabulum. However, it is technically more demanding because the imaging tube must be mobile. It also requires an orthopedic table that does not interfere with the height of the tube.[11,12] Many orthopedic centers in Brazil do not have the mobile X-ray equipment or a suitable orthopedic table required for this view.

There was a statistically significant difference ($p = 0.00$) for the interobserver measurements with both views and at both time points.

The mean measurements of observer 2 were lower compared with all of the measurements from observer 1; this finding may be due to subtle differences in the measurement techniques from both observers.

There was a good intraobserver correlation for both incidences at the 2 time points; moreover, there was no statistically significant difference ($p = 0.309$, $p = 0.611$, $p = 0.699$, $p = 0.223$) between the measurements obtained in both views.

The analysis of radiographic parameters obtained at different moments has already been reported in the literature.[1,13] Meyer et al[13] showed that the use of cross-table and Dunn views by positioning limbs at 45° and 90° (similar to the Ducroquet view) resulted in a better reproduction of alpha angle measurements.

In our study, the measurement of the alpha angle was dependent on the observer. However, this disparity usually does not exist when the same observer performs different measures over a given time.

One of the limitations of our work was the difficulty in obtaining cross-table views in obese patients, since, at that time, we only had conventional X-ray equipment. The recent availability of digital X-ray equipment made it easier to obtain these images in these patients. The difficulty in obtaining cross-table views may be due to the standardization of the Ducroquet view in our hospital as the radiographic incidence of choice to visualize the hip profile. Another limitation was the analysis by only two radiologists as observers.

Given these results, we believe that the Ducroquet radiographic view is a good option for alpha angle measurement, and that it can be the profile of choice since it is easily performed during hip arthroscopies without moving the fluoroscopy arm.

Conclusion

We conclude that the measurement of the alpha angle using the cross-table or Ducroquet view is equivalent.

Conflicts of Interests
The authors have no conflicts of interests to declare.

Acknowledgment
We are grateful to Prof. Daniel K. Scheffer for providing the statistical analysis.

References

1 Clohisy JC, Carlisle JC, Trousdale R, Kim YJ, Beaule PE, Morgan P, et al. Radiographic evaluation of the hip has limited reliability. Clin Orthop Relat Res 2009;467(03):666–675
2 Fadul DA, Carrino JA. Imaging of femoroacetabular impingement. J Bone Joint Surg Am 2009;91(Suppl 1):138–143
3 Dudda M, Albers C, Mamisch TC, Werlen S, Beck M. Do normal radiographs exclude asphericity of the femoral head-neck junction? Clin Orthop Relat Res 2009;467(03):651–659
4 Tannast M, Siebenrock KA, Anderson SE. Femoroacetabular impingement: radiographic diagnosis–what the radiologist should know. AJR Am J Roentgenol 2007;188(06):1540–1552
5 Eijer H, Leunig M, Mahomed MN, Ganz R. Cross- table lateral radiographs for screening of anterior femoral head- neck offset in patients with femoro- acetabular impingement. Hip Int 2001;11(01):37–41
6 Neumann M, Cui Q, Siebenrock KA, Beck M. Impingement-free hip motion: the 'normal' angle alpha after osteochondroplasty. Clin Orthop Relat Res 2009;467(03):699–703
7 Fraitzl CR, Käfer W, Nelitz M, Reichel H. Radiological evidence of femoroacetabular impingement in mild slipped capital femoral epiphysis: a mean follow-up of 14.4 years after pinning in situ. J Bone Joint Surg Br 2007;89(12):1592–1596
8 Nötzli HP, Wyss TF, Stoecklin CH, Schmid MR, Treiber K, Hodler J. The contour of the femoral head-neck junction as a predictor for the risk of anterior impingement. J Bone Joint Surg Br 2002;84 (04):556–560
9 Clohisy JC, Nunley RM, Otto RJ, Schoenecker PL. The frog-leg lateral radiograph accurately visualized hip cam impingement abnormalities. Clin Orthop Relat Res 2007;462(462):115–121
10 Ito K, Minka MA II, Leunig M, Werlen S, Ganz R. Femoroacetabular impingement and the cam-effect. A MRI-based quantitative anatomical study of the femoral head-neck offset. J Bone Joint Surg Br 2001;83(02):171–176
11 Godefroy D, Chevrot A, Morvan G, Rousselin B, Sarazin L. [Plain films of pelvis]. J Radiol 2008;89(5 Pt 2):679–690, quiz 691
12 Chrétien J. -Lateral views of the hip-. Ann Radiol (Paris) 1997;40 (01):5–10
13 Meyer DC, Beck M, Ellis T, Ganz R, Leunig M. Comparison of six radiographic projections to assess femoral head/neck asphericity. Clin Orthop Relat Res 2006;445(445):181–185
14 Loder RT. Effect of femur position on the angular measurement of slipped capital femoral epiphysis. J Pediatr Orthop 2001;21(04): 488–494
15 Gosvig KK, Jacobsen S, Palm H, Sonne-Holm S, Magnusson E. A new radiological index for assessing asphericity of the femoral head in cam impingement. J Bone Joint Surg Br 2007;89(10):1309–1316
16 Rakhra KS, Sheikh AM, Allen D, Beaulé PE. Comparison of MRI alpha angle measurement planes in femoroacetabular impingement. Clin Orthop Relat Res 2009;467(03):660–665