SOCIEDADE BRASILEIRA DE ORTOPEDIA E TRAUMATOLOGIA

RBO REVISTA BRASILEIRA DE ORTOPEDIA

www.rbo.org.br



Technical Note

# Articular reconstruction of the humeral head with autogenous allograft in the treatment of the osteonecrosis☆

*Alberto Naoki Miyazaki, Luciana Andrade Silva, Guilherme do Val Sella*, Caio Santos Checchia, Marcos Cazer Simionato, Sergio Luiz Checchia*

*Departamento de Ortopedia e Traumatologia, Faculdade de Ciências Médicas da Santa Casa de São Paulo, São Paulo, SP, Brazil*

ARTICLE INFO

*Article history:*
Received 24 November 2016
Accepted 15 December 2016
Available online 6 December 2017

*Keywords:*
Osteonecrosis/surgery
Bone transplantation
Graft survival

ABSTRACT

The authors describe a surgical biological reconstruction of the humeral head with frozen autogenous allograft technique for the treatment of young patients with focal osteonecrosis of the humeral head. This represents a possible alternative, maybe even definitive for some patients, when compared to hemiarthroplasty or total shoulder arthroplasty. The technique consists of the fixation of a frozen autogenous allograft with previously-molded articular cartilage from the humeral head, after cleansing the osteonecrotic focus. Five patients under 50 years of age were treated, with three very satisfactory results, one patient was lost to follow-up, and one patient had an unsatisfactory result (converted to hemiarthroplasty). The study describes the technique in detail and the three cases with a longer follow-up time.

© 2017 Sociedade Brasileira de Ortopedia e Traumatologia. Published by Elsevier Editora Ltda. This is an open access article under the CC BY-NC-ND license (http://creativecommons.org/licenses/by-nc-nd/4.0/).

*Palavras-chave:*
Osteonecrose/cirurgia
Transplante ósseo
Sobrevivência de enxerto

## Reconstrução da superfície articular da cabeça umeral com enxerto homólogo no tratamento da osteonecrose

RESUMO

Os autores descrevem a técnica cirúrgica de reconstrução biológica da cabeça umeral com enxerto ósseo homólogo congelado usada no tratamento da osteonecrose segmentar da cabeça umeral em pacientes jovens e destacam a abordagem como uma possibilidade opcional e talvez definitiva à hemiartroplastia ou artroplastia total do ombro. Resumidamente, a técnica consiste em reconstruir a falha encontrada na região necrótica da cabeça

☆ Study conducted at the Grupo de Cirurgia de Ombro e Cotovelo, Departamento de Ortopedia e Traumatologia, Faculdade de Ciências Médicas da Santa Casa de São Paulo, São Paulo, SP, Brazil.

* *Corresponding author.*
E-mail: gvsella@gmail.com (G.V. Sella).

https://doi.org/10.1016/j.rboe.2017.11.011

2255-4971/© 2017 Sociedade Brasileira de Ortopedia e Traumatologia. Published by Elsevier Editora Ltda. This is an open access article under the CC BY-NC-ND license (http://creativecommons.org/licenses/by-nc-nd/4.0/).

umeral com o uso de enxerto ósseo congelado com cartilagem para refazer a superfície articular comprometida. No total, cinco pacientes com menos de 50 anos foram tratados com essa técnica, conseguiram-se resultados muito satisfatórios em três deles, uma perda de seguimento e um resultado negativo, convertido para hemiartroplastia. O estudo descreve a técnica usada com detalhes, bem como os três casos com maior tempo de seguimento.

© 2017 Sociedade Brasileira de Ortopedia e Traumatologia. Publicado por Elsevier Editora Ltda. Este é um artigo Open Access sob uma licença CC BY-NC-ND (http://creativecommons.org/licenses/by-nc-nd/4.0/).

## Introduction

Segmental osteonecrosis of the humeral head has been the subject of few scientific publications, despite the fact that it is a classically expected complication in some fractures and/or fracture-dislocations of the shoulder, representing the second most common site of non-traumatic osteonecrosis.[1]

Initially described by Heimann and Freiberger,[2] several treatments for osteonecrosis of the humeral head are available. The classic conservative treatment in the pre-collapse phase consists of limiting the use of the joint.[3] With the failure of this approach, or in cases of a more advanced disease, the treatment of choice is partial or total arthroplasty.[2] Thus, patients younger than 50 years who undergo shoulder arthroplasty suffer a large number of revisions.[4,5] Bartelt et al.[4] reassessed a series of total and partial arthroplasties performed in patients under 55 years of age and found a lifespan of 72% for partial arthroplasties and 92% for total arthroplasties in a minimum follow-up of 10 years. Johnson et al.[5] published a review article in which they also questioned the longevity of arthroplasties performed in patients younger than 50 years.

Other surgical options, such as humeral head decompression, surface arthroplasty, arthroscopic debridement, and vascularized bone grafting have been described; however, due to their small sample sizes, the results were inconclusive.[1] Procedures involving articular biological reconstruction using fresh homologous graft have been described by Görtz et al.[6] in the treatment of femoral condyle osteonecrosis, with good results. This type of treatment has also been used to fill in the defects of the humeral head resulting from posterior instability of the shoulder[7,8]; chondral defects in the knee, femoral head, and talus; or even for the treatment of ankle osteoarthrosis.

In this context, the authors describe a surgical technique with the use of frozen homologous graft with cartilage for the treatment of segmental osteonecrosis of the humeral head in patients under 50 years of age as an alternative to arthroplasties, since no reports in the literature of this type of approach for osteonecrosis of the humeral head were retrieved in the literature. It is worth noting that until the time these procedures were performed, fresh homologous grafts were not available in our tissue bank. The authors also describe the results of the three patients with longest follow-up.

## Surgical technique

The surgery is performed under general anesthesia, with the patient in a supine "beach chair" position through the deltopectoral access route. After disinsertion of the subscapularis muscle tendon, the humeral epiphysis is exposed and the focus of necrosis is resected (Fig. 1). The articular defect resulting from necrosis resection is filled with a frozen homologous graft of cartilage from a humeral head (obtained from the tissue bank of our institution), which is sculptured intraoperatively according to each case (Fig. 2). The graft is then secured with two 4.0 mm partial thread cancellous screws (in four cases) or with two headless compression screws (in one case), depending on material availability in each situation.

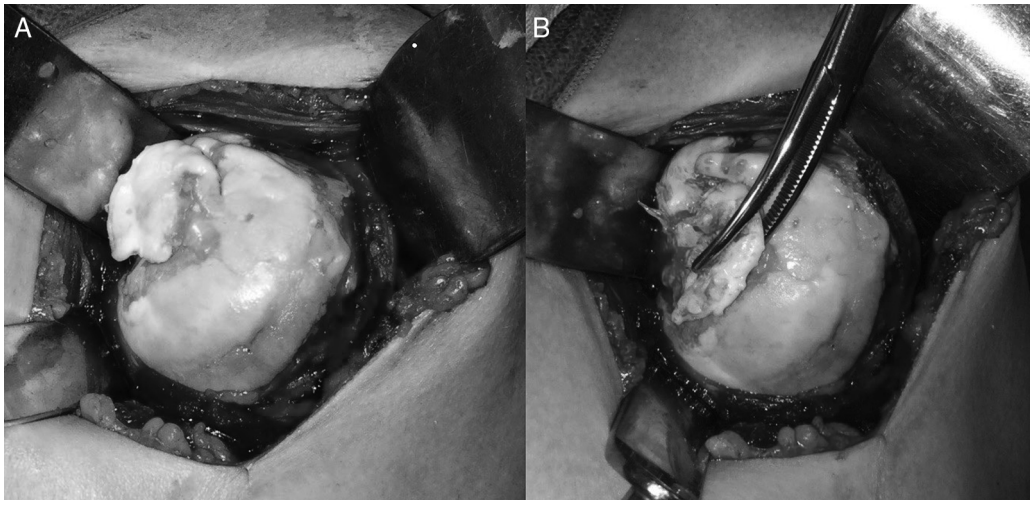


**Fig. 1 – (A) Exposure of the humeral epiphysis, focusing on the evident necrosis; (B) removal of the necrosis focus.**

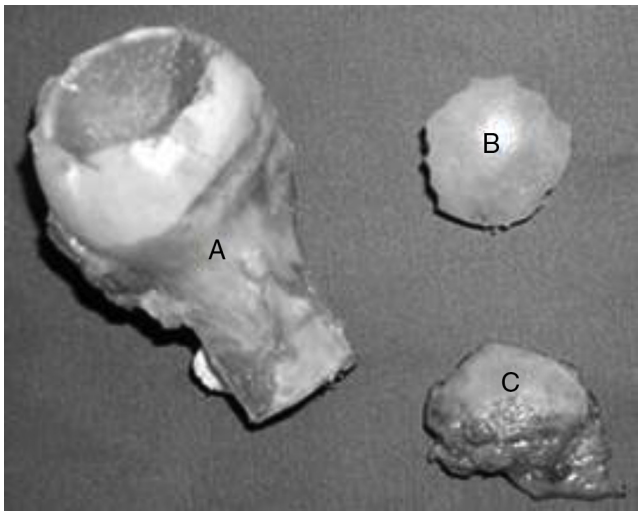


**Fig. 2 – (A) Frozen humeral head graft; (B) graft fragment carved in accordance with the size of the affected area; (C) necrotic articular fragment.**

The heads of the conventional screws are buried to avoid prominence at the joint surface. Before the end of surgery, the disinserted portion of the subscapularis is reinserted with non-absorbable transosseous sutures.

For those patients who underwent graft fixation with screws with heads, a second surgery (through the same access route) was scheduled six months after the primary one to remove the screws, as they could protrude through the joint surface. Three cases are described below.

## Case 1

A 40-year-old male patient, handyman, with a diagnosis of recurrent anterior dislocation of the shoulder in the dominant limb after a fall to the ground. The patient persisted with episodes of pain and instability associated with the appearance of a focus of segmental necrosis on the humeral head, six months after the fall. One year after the initial trauma, the patient underwent a biological reconstruction of the humeral head with frozen homologous bone graft with the use of two conventional screws, together with open repair of the Bankart lesion using two anchors. After screw removal and with over 14 years of follow-up, the patient has evolved without pain, without new episodes of dislocation, and has maintained a good range of motion (140° of elevation, 50° of lateral rotation, and medial rotation corresponding up to T7 level), scoring 35 points on the University of California at Los Angeles (UCLA) Score and 92 points on the Constant Score. The current radiographic images show graft integration (Fig. 3).

## Case 2

A 19-year-old male patient, student, with pain in the non-dominant shoulder for one year. After clinical and radiographic examination indicating subchondral joint collapse of the humeral head, with no antecedents to justify its onset, idiopathic osteonecrosis of the right humeral head was diagnosed. The patient underwent biological reconstruction of the humeral head with frozen homologous bone graft with cartilage using two conventional screws, which were removed after six months. Currently, in a follow-up of over 15 years, the patient remains pain-free, with 140° of elevation, 80° of lateral rotation, and medial rotation corresponding up to T5 level, with 35 points on the UCLA score and 95 points on the Constant Score. Magnetic resonance imaging and radiographic images indicate complete graft integration, with no signs of osteoarthrosis (Fig. 4).

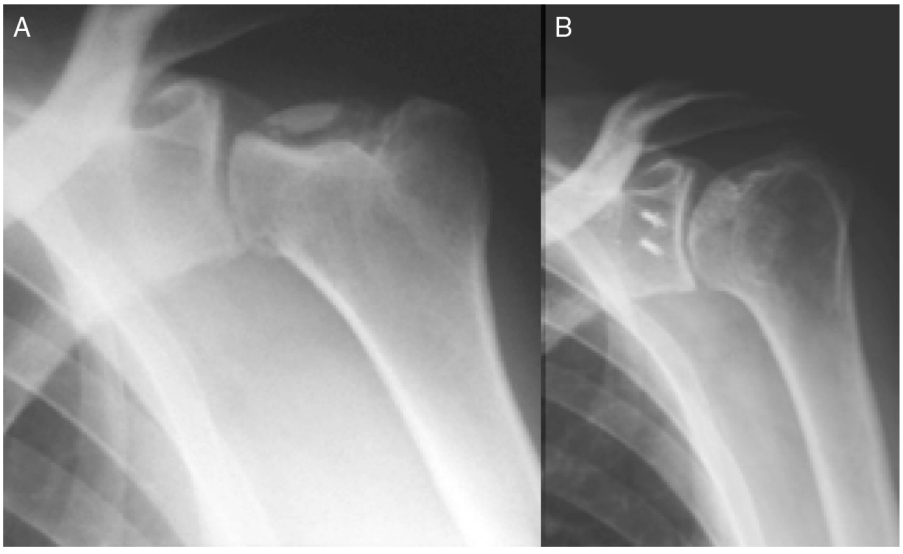


**Fig. 3 – (A) Preoperative radiographic image of the left shoulder in anteroposterior view, showing segmental necrosis of the humeral head; (B) radiographic image of the same patient 14 years after surgery, showing the integrated graft.**




**Fig. 4 – (A) Radiographic images in anteroposterior view and coronal T1-weighted enhanced magnetic resonance imaging of the right shoulder of case 3 in the preoperative period, demonstrating the area of necrosis (see arrows); (B) radiographic images in anteroposterior and coronal T1-weighted enhanced magnetic resonance imaging of the right shoulder of the same case, demonstrating total graft integration after 15 years follow-up.**

## Case 3

A 25-year-old male patient, self-employed, had suffered a traumatic dislocation of the non-dominant shoulder, and underwent arthroscopic repair of a Bankart lesion and superior labrum injury one month after the last episode of anterior glenohumeral dislocation. Just over one month after the labrum repair surgery, the patient reported constant pain. Radiographic exams indicated focal necrosis of the humeral head of the shoulder. Six months after symptom onset, the patient underwent biological reconstruction of the humeral head with frozen homologous bone graft, with the use of two headless compression screws. The patient presented pain recurrence six months after the reconstruction of the humeral head, with signs of graft resorption and subchondral joint collapse (Fig. 5). One year and six months after the homologous graft surgery, a conversion was made to partial hemiarthroplasty of the left humerus.

## Final considerations

Arthroplasty is not a definitive solution for the treatment of osteonecrosis of the humeral head in young patients.

Biological reconstruction of the humeral head with frozen homologous bone graft is a viable option that may delay a future arthroplasty, as observed in case 3.

In cases of complete graft integration, the authors believe that this technique can provide a definitive solution for the patient, as seen in cases 1 and 2.

## Conflicts of interest

The authors declare no conflicts of interest.

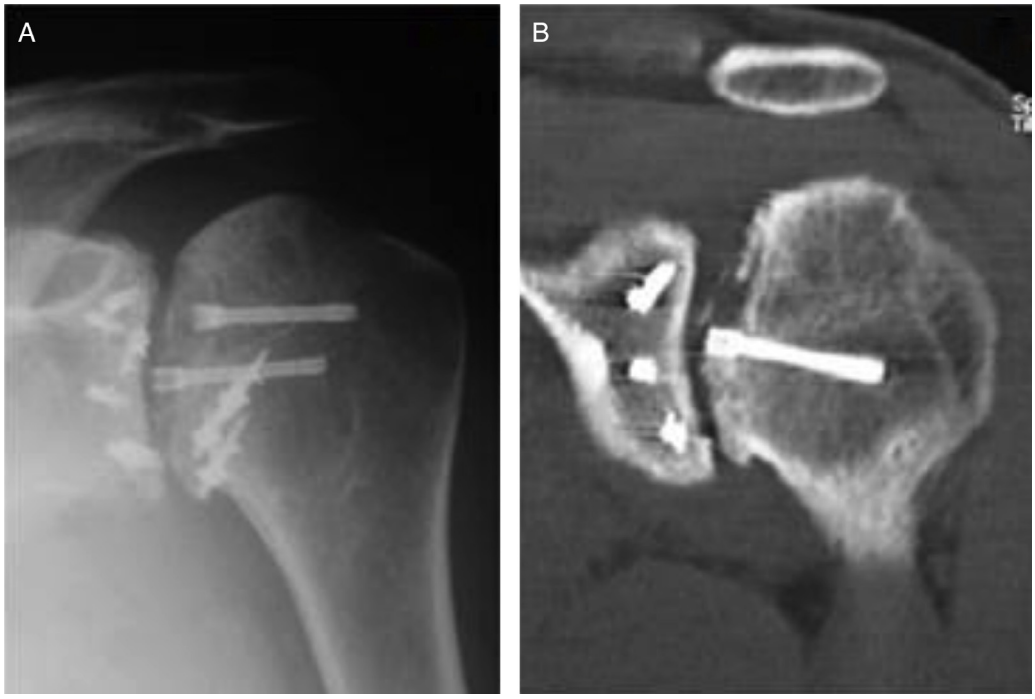


**Fig. 5 – (A) Radiographic image of the left shoulder in anteroposterior view, showing graft resorption and subchondral collapse, with protrusion of one of the screws, six months after articular reconstruction surgery of the humeral head; (B) coronal computed tomography image (bone window) of the same shoulder, demonstrating the articular protrusion of the screw in greater detail.**

## REFERENCES

1. Hasan SS, Romeo AA. Nontraumatic osteonecrosis of the humeral head. J Shoulder Elbow Surg. 2002;11(3):281–98.
2. Heimann WG, Freiberger RH. Avascular necrosis of the femoral and humeral heads after high-dosage corticosteroid therapy. N Engl J Med. 1960;263:672–5.
3. Cruess RL. Experience with steroid-induced avascular necrosis of the shoulder and etiologic considerations regarding osteonecrosis of the hip. Clin Orthop Relat Res. 1978;(130):86–93.
4. Bartelt R, Sperling JW, Schleck CD, Cofield RH. Shoulder arthroplasty in patients aged fifty-five years or younger with osteoarthritis. J Shoulder Elbow Surg. 2011;20(1):123–30.
5. Johnson MH, Paxton ES, Green A. Shoulder arthroplasty options in young (<50 years old) patients: review of current concepts. J Shoulder Elbow Surg. 2015;24(2):317–25.
6. Görtz S, De Young AJ, Bugbee WD. Fresh osteochondral allografting for steroid-associated osteonecrosis of the femoral condyles. Clin Orthop Relat Res. 2010;468(5):1269–78.
7. Diklic ID, Ganic ZD, Blagojevic ZD, Nho SJ, Romeo AA. Treatment of locked chronic posterior dislocation of the shoulder by reconstruction of the defect in the humeral head with an allograft. J Bone Joint Surg Br. 2010;92(1):71–6.
8. Gerber C, Catanzaro S, Jundt-Ecker M, Farshad M. Long-term outcome of segmental reconstruction of the humeral head for the treatment of locked posterior dislocation of the shoulder. J Shoulder Elbow Surg. 2014;23(11):1682–90.