LONG-TERM RESULTS OF BODY AND NECK TALUS FRACTURES

Ricardo Jorge Gomes de Sousa[1], Marta Maria Teixeira de Oliveira Massada[1], Manuel Alexandre Negrais Pinho Gonçalves Pereira[1], Isabel Maria Gonçalves Costa[2], José Fernando Souzellas da Costa e Castro[3]

ABSTRACT

Objectives: Talar neck and body fractures are unusual fractures. The purpose of this study is to determine the prevalence of long term results. Material and Methods: A retrospective analysis was carried out including 11 patients that underwent surgical treatment for body or neck talus fractures between January 1997 and December 2005. Final follow-up examination included a clinical evaluation (AOFAS score) and standard radiographs. Results: The mean follow-up time was 58.5 months. The prevalence of associated fractures was 60% (6/10). Overall AOFAS score averaged 72 [19-100]. Avascular necrosis and posttraumatic arthritis were present in half of the patients. Quality of surgical reduction, body fractures and absence of degenerative changes were correlated with better functional results. Neck fractures, osteonecrosis and posttraumatic arthritis led to inferior results. Conclusion*:* There is a great potential for long term functional impairment due to posttraumatic arthritis and chronic pain in this kind of fracture. Anatomic surgical reduction is the best chance to avoid them but it is not infallible. The avascular necrosis rate correlates with initial fracture displacement, but its occurrence in each specific case is unpredictable.

Keywords - *Fractures, Bone/complications; Astragalus; Osteonecrosis; Osteoarthritis*

INTRODUCTION

Fractures of the body and neck of the talus are rare, but have potential for serious long-term complications. Historically, they have been associated with avascular necrosis rates ranging between 12% and 53%[1-7].

Post-traumatic arthritis can be an even more frequent sequela. However, the large variability in follow-up intervals between the different studies makes it difficult to accurately quantify. The prevalence of degenerative changes described ranges from 16 to 100%[1-7].

Typically, these fractures occur in the context of high-energy trauma and, as such, have a high prevalence of associated fractures. This may obscure the true impact of talar injury on the final clinical outcome. In any case, it seems clear that in most cases some degree of functional compromise should be expected.

We decided to evaluate these two types of fracture (body and neck) together because we think they share many aspects of biomechanics, treatment, complications, and possible functional implications.

The main objective of this study was to determine the long-term functional impact of fractures of the body and neck of the talus treated surgically at our hospital. In addition, we were interested in evaluating the relationship (or lack thereof) of avascular necrosis, presence of degenerative joint changes and the final clinical outcome. A secondary objective was to describe the differences that may exist between fractures of the neck and body.

1 – Complementary Intern, Orthopedic Clinic, Hospital de Santo António, Porto, Portugal.
2 – Graduate Hospital Assistant, Orthopedic Clinic, Hospital de Santo António, Porto, Portugal.
3 – Head, Orthopedic Clinic, Hospital de Santo António, Porto, Portugal.

Study conducted at the Orthopedic Clinic, Hospital de Santo António – Centro Hospitalar do Porto, Portugal.
Correspondence: Serviço de Ortopedia, Hospital de Santo António – Centro Hospitalar do Porto – Largo Professor Abel Salazar – 4099-001 Porto, Portugal
E-mail: ricardojgsousa@gmail.com

We declare no conflict of interest in this article

METHODS

We identified all patients undergoing surgery for fractures of the body or neck of the talus in our hospital over a period of nine years, between January 1997 and December 2005, using the surgical activity registration books. Retrospective analysis was made of their clinical and radiological processes.

All patients were called and evaluated clinically using the Kitaoka ankle and hindfoot scale of the American Orthopaedic Foot and Ankle Society (AOFAS), which assesses pain, function, and alignment. A radiological study of the ankle was also performed.

The initial radiographs were evaluated in order to classify the fractures. For this we used the Hawkins classification modified by Canale and Kelly[1] for fractures of the neck and Marti classification[7] for fractures of the body (Figure 1). The quality of reduction was determined by analyzing the control radiographs of the early postoperative period. For this we used the criteria proposed by Lindvall *et al*.[3], which defined anatomic reduction to be a lack of deviation or angulation of the fracture, almost anatomic reduction to be a deviation of 1-3 mm or mild varus angle ($\leq 5°$), and poor reduction for higher values (Figure 2).



Figure 1 – Example of a Marti Type II fracture of the talar body. In this case, the patient had associated fracture of the calcaneus.



Figure 2 – Hawkins type III almost anatomic postoperative reduction.

The presence or absence of osteonecrosis was based on the observation of X-rays belonging to the process and the signs of arthritis were surveyed in the images taken in the review consultation. These criteria were determined by a senior independent observer (CC) who was unaware of the clinical status of each patient.

No statistical correlations were sought in interpreting these results, because the small sample size does not allow for significant inferences.

RESULTS

Of the 19 patients that were initially identified, only 11 could be assessed. The average age at the time of initial injury was 38.5 (14-63) years. Only one patient was female. The elapsed time between surgery and follow-up consultation was on average 58.5 months, ranging between 14 months and 10 years.

The initial classification of the fracture was only possible in eight of 11 patients for lack of initial radiographs in three cases. Of these, four were (Marti) type II fractures of the body, and three were neck fractures (two Hawkins type II and one Hawkins type III). A posterior osteochondral fracture of the body was also found, which was excluded from the study because we consider it distinct from the rest. The three cases in which it was not possible to obtain initial radiographs were still included in the study because the medical records and postoperative radiographs indicated that the fractures were in the body (n = 1) or the neck (n = 2) of the talus. A total of ten cases was therefore studied.

The high prevalence of associated bone lesions de-

tected (6/10) allows us to perceive the violence of the trauma usually associated with such fractures. The most common were the fracture of the acetabulum, the distal tibia (pestle and malleolus) and the ipsilateral calcaneus.

The scale used (AOFAS) defines excellent results to be those between 90 and 100 points, good to be between 80 and 89, fair to be between 70 and 79 points, and poor results to be below 70. The average value was 72 (19-100).

Osteonecrosis of the talar dome appeared in five patients (three fractures of the neck and two fractures of the body). Its presence strongly influenced the final outcome, with an AOFAS average of 50 points versus an average of 93 in cases without necrosis. Also the development of osteoarthritis appears to be closely linked to the progression to osteonecrosis. Four of these five patients had late degenerative joint changes.

Five of the ten patients showed signs of osteoarthritis in the subtalar joint. Of these, only one affected the subtalar joint in isolation, the remaining four also showed radiological signs of osteoarthritis of the ankle. We did not observe any cases with isolated degenerative changes of the tibiotalar joint. Only two of the ten patients showed talar-scaphoid osteoarthritis. No significant differences were found between the presence of osteoarthritis between the two subgroups (three of five neck fractures vs. two of five fractures of the body).

The relationship between a high score and the absence of degenerative changes was evident. In patients with osteoarthritis the average value was 51 versus 93 in patients without radiographic changes. Considering only the pain criterion, we also noted that its presence correlates with the presence of arthritis (Figure 3).

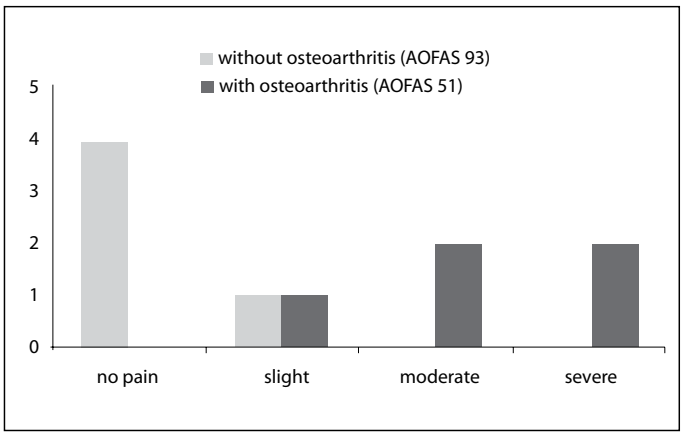

Figure 3 – Relationship between the presence osteoarthritis and the prevalence of pain.

The quality of reduction achieved also correlated positively with the final clinical and radiological outcome (Table 1). Of the ten patients studied, the postoperative radiographs for three patients could not be found. Of the remaining seven, four were classified as anatomic reduction, two were classified as almost anatomic, and one was considered a poor reduction.

Table 1 – Relationship between quality of reduction and final clinical and radiographic outcome.

Quality of reduction	Presence of osteoarthritis	AOFAS
Anatomic (n = 4)	*25% (1/4)*	*89*
Almost anatomic (n = 2)	*50% (1/2)*	*55*
Poor reduction (n = 1)	*100% (1/1)*	*60*

A curious finding was the difference between the results of neck (mean AOFAS: 61) and body fractures (mean AOFAS: 82). Reviewing the results in greater detail, we find that four of the five body fractures identified had good or excellent results, while three of the five neck fractures were classified as having a poor result. Only one case of fracture of the body showed signs of late degenerative changes.

DISCUSSION

Long-term functional impact

We can see that this type of fracture can cause a significant functional impact. The mean value obtained [72] is at the lower end of fair. However, the functional outcome was excellent in four cases, good in two, and poor in the remaining four patients. Recently, Ebraheim *et al*.[8] described a similar proportion (nine out of 16) of fair/poor outcomes in fractures of the body. Lindvall *et al*.[3] in their study of 26 fractures of the neck or body also describe a large proportion of fair/poor results. Other studies using different clinical rating scales that prevent a direct comparison, confirm a proportion that is generally around 50% unsatisfactory results[4-6,9].

Osteonecrosis and degenerative changes

Avascular necrosis of the talar dome represents a specific complication of this type of fracture and is due to the interruption of arterial blood from the tarsal sinus and the canal at the neck of the talus.

Its occurrence in the literature varies considerably, but it seems evident that it correlates with the degree of initial deviation of the fracture. Hawkins type I fractures of the neck develop osteonecrosis in 0-24% of cases, type II in 0-50% and types III and IV in 33-100%[7]. Fractures without body deviation (Marti type I) may develop avascular necrosis in 5-44% of cases, while in deviated fractures (Marti type III and IV) it is around 50%[7].

In his original report in 1970[10], Hawkins described a radiographic sign consisting of the appearance of radiolucency in the subchondral region of the talar dome around the 6th week. This osteopenia translates bone remodeling and is highly predictive of bone regeneration of the body. Even if the radiolucency is only partial (Figure 4), the prognosis remains favorable[11,12]. However, as we note in our study, its absence does not imply the occurrence of avascular necrosis[11]. We can thus conclude that it has good specificity but low sensitivity.

Theoretically, the ultimate prognosis of the ankle and other adjacent joints to the talus appears to be closely related to the possible extent of avascular necrosis. In our study, the proportion of osteoarthritis and the functional and clinical outcomes was higher in cases in which there was the appearance of osteonecrosis. However, other published studies do not reveal a clear association between post-traumatic arthritis and the presence of avascular necrosis of the talus[3,4,7].



Figure 4 – Partial Hawkins sign at eight weeks of development.

The prevalence of osteoarthritis was 50% in our study. The rates found in the literature vary widely (Table 2) and depend mainly on the longer time elapsed and the defining criterion used. Lindvall *et al*. study[3] was the only one to include evaluation by computerized tomography and that can justify the 100% rate of degenerative subtalar changes.

Table 2 – Comparison of the prevalence of arthritis by joint and different studies.

	HSA	Lindvall[3]	Vallier[4]	Vallier[12]	Schulze[5]
Absent	*50%*	*0%*	*46%*	*31.6%*	*31.2%*
Subtalar	*50%*	*100%*	*-*	*34.6%*	*52.5%*
Subtalar isolated	*10%*	*38.5%*	*-*		*17.5%*
Ankle isolated	*0%*	*0%*	*-*	*65.4%*	*16.20%*
Subtalar and ankle	*40%*	*57.7%*	*54%*		*35%*
Subtalar and talar-scaphoid	*20%*	*3.8%*	*-*		*-*

It seems clear that the mere radiological appearance of osteoarthritis is not sufficient nor necessary to cause clinical and/or functional effects. Several studies[3,4,7,13,14] have shown that the presence of radiopaque regions (indicating focal areas of necrosis) or radiological signs of post-traumatic osteoarthritis do not preclude the possibility of a good clinical outcome. However, the total involvement with collapse of the talar dome and extensive degenerative changes invariably lead to worse results.

There are many negative prognostic factors that are outside the surgeon's control, such as the severity of the initial injury, the initial deviation of the fracture, the extent of cartilaginous damage or bone comminution, and even the severity of soft tissue injury[7].

In our study, the quality and stability of the reduction achieved seem to have been a major factor for achieving better long-term results. Other studies have reached the same conclusion[3,7]. In

the absence of dislocation, the timing of internal fixation does not seem to affect the rates of avascular necrosis or the final outcome[3,4,13,14]. Thus, it becomes evident that an anatomic reduction is the best chance to avoid late sequelae.

Fractures of the body versus neck fractures

In our series, fractures of the body seem more "benign" in terms of their functional impact in the long run than the neck fractures. This finding should be interpreted with caution, since it is an analysis with few cases. In addition, fractures of the body generally have a less severe classification than those of the neck. In a direct comparison of fractures of the body and neck, Lindvall *et al*.[3] found no statistically significant difference between the AOFAS score, rates of osteonecrosis, or prevalence of posttraumatic osteoarthritis.

CONCLUSION

Similar to most studies on this topic, our study has several limitations. The series analyzed is small and therefore statistically fragile. The retrospective nature of the study made it difficult to obtain more detailed clinical information and even some X-rays that were important.

Nevertheless, the long time elapsed (on average, almost five years) achieved allows us to conclude that these fractures have great potential for late sequelae, especially when a stable anatomic reduction is not obtained.

The progression to avascular necrosis is a major complication and its occurrence is somewhat unpredictable. Patients should be informed that post-traumatic arthritis and chronic pain can arise in spite of adequate surgical treatment and even in the absence of radiological signs of osteonecrosis.

REFERENCES

1. Canale ST, Kelly FB Jr. Fractures of the neck talus. Long-term evaluation of seventy-one cases. J Bone Joint Surg Am. 1978;60(2):143-56.
2. Inokuchi S, Ogawa K, Usami N, Hashimoto T. Long term follow-up of talus fractures. Orthopedics 1996;199(1):88-96.
3. Lindvall E, Haidukewych G, DiPasquale T, Herscovici D, Sanders R. Open reduction and stable fixation of isolated, displaced talar neck and body fractures. J Bone Joint Surg Am. 2004;86(10): 2229-34.
4. Vallier HA, Nork SE, Benirschke SK, Sangeorzan BJ. Talar neck fractures: results and outcomes. J Bone Joint Surg Am. 2004;86(8):1616-24.
5. Schulze W, Richter J, Russe O, Ingelfinger P, Muhr G. Surgical treatment of talus fractures – a retrospective study of 80 cases followed for 1-15 years. Acta Orthop Scand. 2002;73(3):344-51.
6. Pajenda G, Vécsei V, Reddy B, Heinz T. Treatment of talar neck fractures: clinical results of 50 patients. J Foot Ankle Surg. 2000;39(6):365-75.
7. Rammelt S, Zwipp H. Talar neck and body fractures. Injury. 2009;40(2):120-35.
8. Ebraheim NA, Patil V, Owens C, Kandimalla Y. Clinical outcome of fractures of the talar body. Int Orthop. 2008;32(6):773-7.
9. Sanders DW, Busam M, Hattwick E, Edwards JR, McAndrew MP, Johnson KD. Functional outcomes following displaced talar neck fractures. J Orthop Trauma. 2004;18(5):265-70.
10. Hawkins LG. Fractures of the neck of the talus. J Bone Joint Surg Am. 1970;52(5):991-1002.
11. Tezval M, Dumont C, Sturmer KM. Prognostic reliability of the Hawkins sign in fractures of the talus. J Orthop Trauma. 2007;21(8):538-43.
12. Tehranzadeh J, Stuffman E, Ross SDK. Partial Hawkins sign in fractures of the talus: a report of three cases. Am J Roentgenol. 2003;181(6):1559-63.
13. Vallier HA, Nork SE, Benirschke SK, Sangeorzan BJ. Surgical treatment of talar body fracture. J Bone Joint Surg Am. 2003;85(9):1716-24.
14. Comfort TH, Behrens F, Gaither DW. Long term results of displaced talar neck fractures. Clin Orthop Relat Res;1985;(199):81-7.