THE ROLE OF FIBRIN GLUE AND SUTURE ON THE FIXATION OF ULTRA FROZEN PRESERVED MENISCUS TRANSPLANTATION IN RABBITS

Leandro José Reckers[1], Djalma José Fagundes[2], José Luiz Pozo Raymundo[3], Geraldo Sérgio de Mello Granata Júnior[4], Márcia Bento Moreira[5], Vanessa Carla Paiva[6], Anna Luiza Negrini Fagundes[7], Moises Cohen[8]

ABSTRACT

Objective: To evaluate the ability of fibrin adhesive in promoting the meniscus fixation within two, four and eight weeks compared to the conventional soft-tissue suture technique. Materials and Methods: 36 right medial menisci of rabbits preserved at negative 73° Celsius for 30 days were transplanted to animals of the same sample and fixed with soft-tissue suture or fibrin glue. After 2, 4 or 8 weeks, the appearance of the menisci and the quality of fixation were macroscopically checked and evaluated by a scoring system. The findings were subjected to the statistical study of variance analysis ($p \leq 0.05\%$). Results: The deep-frozen meniscus preservation maintained the integrity of the meniscus transplant, and, macroscopically, there was no significant reduction of the length of the meniscus in all post-transplant periods ($p = 0.015$). The menisci fixed with fibrin showed slight changes in color and surface roughness. There were no signs of rejection or infection in both groups. Suture fixation scoring was superior ($p = 0.015$) in all periods (80% of total fixation) as compared to the setting promoted by fibrin (20% of total fixation). Conclusion: The homologous transplantation of the meniscus of rabbits experienced various degrees of integration to the knee according to the fixation method; the surgical soft tissues suturing technique was shown to be superior in the evaluation of scores compared to the fixation with fibrin adhesive.

Keywords – *Meniscus; Transplantation; Rabbits; Fibrin tissue adhesive*

INTRODUCTION

Lesions of the meniscus, which require partial or total meniscectomy, are related to a greater or lesser extent, in short or long-term, with degeneration of the knee joint represented by the various degrees of osteoarthritis[1-9].

The meniscus transplant is one option among the various treatments available. The replacement of the damaged meniscus by another homologous meniscus is a proposition that has been tested for decades, yet some aspects of the procedure are still controversial and deserve the attention of researchers. The fixation of the meniscus presents a degree of technical difficulty that is an important limiting factor for the procedure, especially after the advent of video-assisted surgery[10-20].

In this context, the use of an adhesive that can fix the meniscus transplant would be a breakthrough in

1 – Doctor's degree in Science, Universidade Federal de São Paulo (UNIFESP), São Paulo, Brazil.
2 – Associate Professor and Lecturer, Department of Surgery, Universidade Federal de São Paulo (UNIFESP), São Paulo, Brazil.
3 – Doctor's degree in Science, Universidade Federal de São Paulo (UNIFESP); Associate Professor, Department of Orthopedics, Universidade Federal de of Pelotas, Brazil.
4 – Master's degree in Science, Universidade Federal de São Paulo (UNIFESP), São Paulo, Brazil.
5 – Veterinarian, Doctor's degree in Science, Universidade Federal de São Paulo (UNIFESP), São Paulo, Brazil.
6 – Veterinarian, Master's degree in Science, Universidade Federal de São Paulo (UNIFESP), São Paulo, Brazil.
7 – Medical Student, Universidade de Santo Amaro (UNISA), São Paulo, Brazil.
8 – Associate Professor and Lecturer, Department of Orthopedics, Universidade Federal de São Paulo (UNIFESP), São Paulo, Brazil.

Correspondence: Rua Gonçalves Chaves, 3500, ap. 302 – 96015-560 – Pelotas – Brazil. E-mail: leandroreckers@uol.com.br

We declare no conflict of interest in this article

reducing the procedure time, in the ease of performing the procedure, and the recovery of the patient[21].

Fibrin is a substance with adhesive properties that has been dedicated application in other tissues and organs. It is a product derived from human plasma that has been increasingly used as a biodegradable tissue adhesive. Its use in various surgical situations attempts to decrease or prevent bleeding in parenchymal structures or provide the continent approximation of tubular structures[22-23].

The mechanism of action of this adhesive is explained by a cross-reaction with the coagulation factor XIII, with calcium as a catalyst, which makes the thrombin converts fibrinogen into a firm fibrin network that is mechanically stable and with significant adhesive properties[24-27].

The rabbit is often reported in the literature as an animal model for experimentation in meniscus transplantation[8,9,13,14,27]. In this project, we established the procedure of using deep-frozen homologous rabbit menisci that were transplanted into different animals after 30 days of preservation, simulating the conditions that may be encountered in human clinical cases.

The purpose of this study was to evaluate the ability of fibrin adhesive in promoting the fixation of the meniscus over time (two, four, and eight weeks) compared with the conventional technique for suture fixation.

METHODS

The experiment was submitted for the approval of the Ethics Committee of the Universidade Federal de São Paulo (UNIFESP-EPM) (Protocol number 238/03). All procedures strictly adhered to the rules of the Brazilian College of Animal Experimentation (COBEA).

SAMPLE

We used 36 New Zealand white male rabbits (Oryctolagus cuniculus), aged between six and eight months and with an average weight of 3,250 grams.

The rabbits were housed in the vivarium of the Division of Operative Technique and Experimental Surgery, UNIFESP-EPM, housed in individual cages in temperature conditions controlled by air-conditioning, 12 hours light-dark cycle and feeding with species-specifc rations and water ad libitum. The study was divided into three phases that took place over a period of 12 months.

Anesthesia

The animals were weighed on a precision balance, immediately before pre-anesthetic medication to calculate the doses of anesthetics.

Prior to anesthesia, antimicrobial prophylaxis was performed with procaine penicillin (Ariston® Laboratory, São Paulo, SP) at a dose of 40,000 U/kg day, maintaining a daily dose for two more days after the procedure.

In the operating room, the rabbits received 2.4 mg/kg of acepromazine (Acepran®, Univet, São Paulo, SP) to 1% and 4 mg/kg xylazine hydrochloride (Anasedan®, Vetbrands, São Paulo, SP) combined in the same syringe and administered intramuscularly (posterior thigh – belly of the semitendinosus and semimembranosus muscles).

Venous access was made possible through a puncture of the marginal auricular vein for the infusion of sodium chloride saline solution and 0.9% of the drugs required for anesthesia induction, such as ketamine hydrochloride (Ketalar®, Parke-Davis, São Paulo, SP) and xylazine (Rompun®, Bayer, São Paulo, SP) in a 1:1 ratio, by administering 0.5 ml of this solution.

The animals were kept in a supine position in the surgical trough and intubated with a 2.5 endotracheal tube without a balloon. Anesthetic maintenance was performed with 1.5% isoflurane (AstraZeneca, São Paulo, SP) in a constant flow of 2L per minute and a respiratory rate of ten breaths per minute, cycled using the Takaoka® device (model KT12 Sansei).

Donor operative procedure

With the animal anesthetized, trichotomy was performed around the right hind limb from the groin to the foot of the animal, without including it. Antisepsis was performed with polyvinylpyrrolidone solution (Povidine®, São Paulo, SP) and sterile cloths were placed to delimit the operative field. A 4 cm medial parapatellar longitudinal incision of the skin and subcutaneous tissue was made; the patellar ligament was identified and the medial

joint capsule was exposed. Valgus exertion and knee flexion were enough to access the medial meniscus. Total meniscectomy was performed with a No. 15 scalpel blade and 10 cm straight scissors. The joint capsule and skin were closed with polyamide thread 5.0 (Mononylon®, Ethicon) sutures. After the surgery, the animal was taken to the recovery room and observed for a post-anesthesia period until full recovery of consciousness and spontaneous ambulation and subsequently returned to vivarium housing.

Preservation of the menisci

After their removal, the menisci were measured in their long axes and placed in small sterile plastic bags (4 x 3 cm) and sealed with sterile tape. Each set was placed into a hard plastic cylindrical shell (5 cm diameter) previously sterilized with ethylene oxide. The meniscus was labeled and taken to the freezer (temperature of -73°C), where it remained for 30 days.

Preparation procedure for meniscus implant

The menisci were removed from the freezer and the shells in which they had been stored and placed in a container filled with 0.9% sodium chloride saline solution at room temperature, and thawing occurred in 15 minutes on average.

Operative procedure in the recipient

Steps similar to the first surgical procedure were reproduced (anesthesia, antimicrobial, aseptic, and antiseptic prophylaxis). The medial parapatellar longitudinal incision measuring 4 cm was made on the previous scar. The subcutaneous tissue was divulsed until the medial joint capsule was exposed. After randomly assigning one of the two techniques, the thawed meniscus was implanted in the recipient rabbit.

Surgical suturing technique

There were three points of fixation with polyamide 5.0 monofilament (Mononylon®, Ethicon): the first in the region of the posterior horn, in the point of insertion of the anterior cruciate ligament in the tibia; the second point of fixation was performed in the region of the anterior horn along the anterior capsule; and the third fixation point was in the body of the meniscus, where it was performed in a U, with the tibial collateral ligament.

Surgical technique with fibrin adhesive

Fixation of the meniscus was performed by placing 0.4 ml of fibrin glue in the tibial portion of the medial meniscus. Manual compression was performed on the meniscus in the region of the tibial plateau for two minutes to complete polymerization of the adhesive.

Criteria for macroscopic evaluation

After opening the knee joint, the meniscus was exposed and evaluated in its macroscopic appearance regarding color, luster, and the presence of secretion. Next, the quality of fixation was determined using a scoring system (Table 1).

Table 1 – Scores and criteria establishment for the macroscopic meniscus evaluation at the different periods of observation.

Score	Fixation	Criteria
0	*Total*	*Total fixation of the meniscus to the synovial membrane: anterior horn, body, and posterior horn*
1	*Partial*	*Partial fixation of the meniscus to the synovial membrane: fixation of only one of the horns: anterior horn, body, or posterior horn*
2	*No fixation*	*No horns fixed to the synovial membrane*

Statistical study

The variables were represented by mean and standard deviation (SD). A significance level of 0.05 ($\alpha \leq 5\%$) was adopted; (p) levels below this value were considered significant and represented by an asterisk.

Groups of the different fixation methods were compared within each experiment, defined by the time of euthanasia at two, four, and eight weeks of the experiment. Dunn's multiple comparison, Kruskal-Wallis, and Fisher's exact test were the statistical tests that were applied. The Bonferroni correction was made to the significance level when a test was used several times, to ensure an overall significance level of 5% for each group comparison.

RESULTS

The meniscus fixed by suture presented a pearly-white appearance with a smooth and shiny surface with no signs to indicate any pain of rejection or inflammation in all of the times studied. There was no presence of any type of secretion (Figures 1, 2, and 3).



Figure 1 – Sutured meniscus after two weeks (left). Note the pearly-white shiny surface and the absence of secretion. Although there slight changes at the edges, its appearance is very similar to the normal lateral meniscus (right).

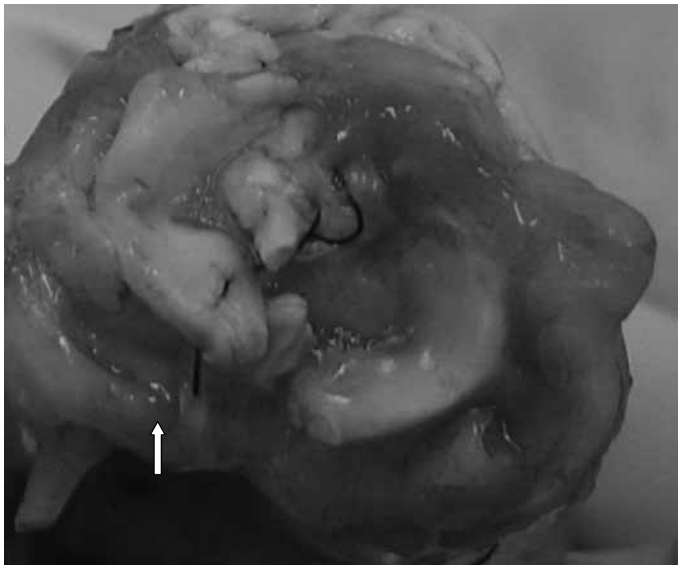

Figure 2 – Sutured meniscus after four weeks (left). Note the pearly-white shiny surface and the absence of secretion. The edge of the anterior horn is detached from the tibial plateau, indicating partial fixation (arrow).

The menisci that were fixed by fibrin revealed an irregular surface, slightly yellowish color, covered by a thin layer of light yellow and cloudy secretion. There were no signs consistent with rejection or necrosis (Figures 4, 5, and 6).

The distribution of the meniscus according to the percentage of partial (Figure 7) and total fixation (Figure 8) showed significant differences from the statistical point of view ($p \leq 0.015$), both for comparisons within groups (suture x fibrin), and between groups (2nd, 4th and 8th week). The suture was more effective in promoting fixation at all times observed. Fibrin glue is practically ineffective in promoting fixation, since a large percentage of the menisci were partially or totally not fixed.

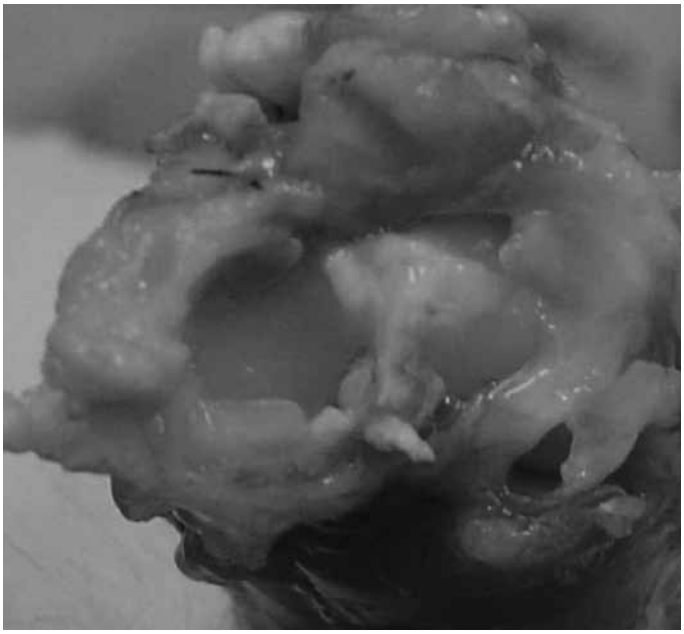

Figure 3 – Sutured meniscus after eight weeks (left). Note the pearly-white shiny surface and the absence of secretion. The surface and edges show slight irregularities, but the meniscus is firmly fixed to the tibial plateau.



Figure 4 – Meniscus fixed with fibrin after two weeks (left). Note the opaque surface with an irregular surface and changes in the edges. Its appearance is different from that of the normal lateral meniscus (right).



Figure 5 – Meniscus fixed with fibrin after four weeks (left). The edge of the anterior horn is detached from the tibial plateau, affecting more than half of the body of the meniscus, indicating non-fixation.



Figure 6 – Meniscus fixed with fibrin after eight weeks (left). The meniscus is loose and displaced.

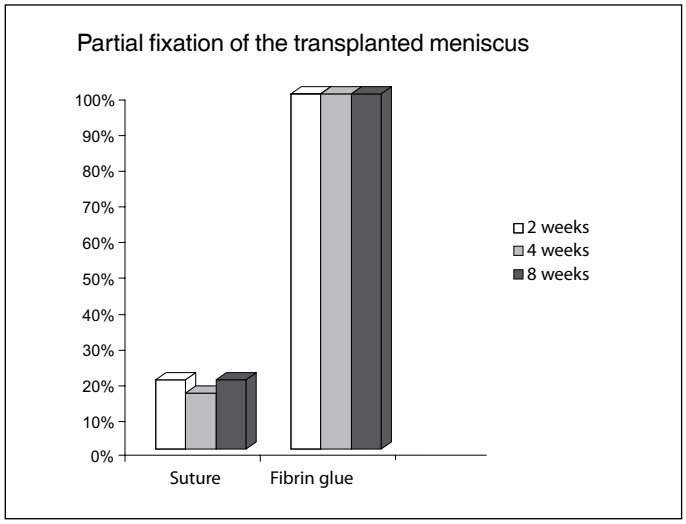

Figure 7 – Distribution of percentages of the menisci in the second, fourth, and eighth weeks of observation, according to the criteria of partial fixation.

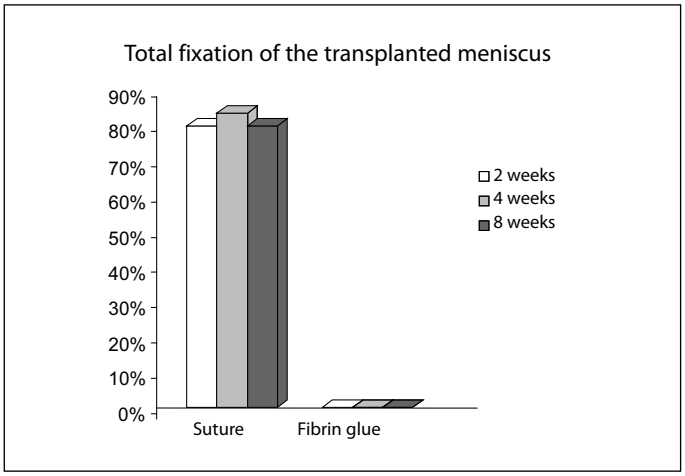

Figure 8 – Distribution of percentages of the menisci in the second, fourth, and eighth weeks of observation, according to the criteria of total fixation.

DISCUSSION

The attempt to restore the biomechanics of the knee and prevent further joint degeneration is the rationale that guides the concept of homologous transplantation. Clinical evaluation of the effectiveness of meniscal transplantation involves some obstacles that have still not been properly overcome, such as the diversity in patient selection, different surgical techniques employed, and the various criteria for postoperative evaluation. Moreover, how much the transplant prevents joint degeneration when the joint dynamics are restored to nearly normal has not been established. A study[28] with 20 years of follow-up of meniscus transplant patients showed that some isolated patients showed satisfactory subjective results, but we must face the fact that the radiographic findings clearly show that in the long run, the medial meniscus transplant had not protected the knee joint from degenerative changes. However, the results are difficult to interpret. A definitive conclusion that the transplantation does not protect against arthritis can not be grounded in only one series of cases[28].

Thus, animal experimentation is a way to test the transplant within the strict limitations of an experimental model. Meniscus transplantation has been investigated in various animals such as sheep, dogs, goats, and rabbits[8,9,13,14,19,26]. The choice of the rabbit was therefore based on frequent reports from the literature that refer to it as appropriate for the study of meniscus transplants. The meniscus of the animal presents a histological pattern very similar to that found in humans, characterized by a fibrocartilaginous tissue interlaced by collagen fibers interposed by fibrochondrocytes[8,9,13,14,22,27]. However, its size of about 1 cm requires a delicate technique for dissection, removal, storage, and reimplantation. Also, due to the tiny dimensions of the tibial plateau, it was not possible to test the technique of tunnels with bone blocks.

There are three commonly used procedures available for the preservation of the menisci for transplantation – cryopreservation, lyophilization, and deep-freezing at temperatures below -70°C. Deep-freezing is considered to be the technique that keeps the meniscus closest to its fresh structure and has the lowest operating cost[9,13,14,20,27,28]. Preservation for 30 days at a temperature of -73°C used in this research showed that the procedure was appropriate and expressed by maintaining the macroscopic size and texture of the meniscus.

Fixation of the meniscus to the recipient can be accomplished by a variety of surgical techniques, from suturing the body and horns to the soft tissues or bone fixation through a tunnel in the tibial plateau with or without bone block, but always associated with meniscus fixation in the adjacent synovial membrane[2,5,6,18,12,27]. Regardless of whether the surgery is video-assisted or open, the techniques are laborious and require considerable operative time to complete. Thus, the proposition of using the adhesive was suggested to test its possible effectiveness and its feasibility to test for a possible decrease in operative time, and any other technical advantages of its application, primarily through videoarthroscopy, making the procedure easier.

The choice was fibrin glue, since the use of cyanoacrylate showed unfavorable results in previous studies, where there was intra-articular caseous necrosis with cutaneous fistula around the 15th day after implantation[22,27]. Resorcinol glue was also extremely harmful to the knee in rabbits in attempting to fix osteochondral defects of articular cartilage[28]. Fibrin glue is widely used with favorable results in several surgical procedures and in various pathological situations[23-27]. Due to its availability, ease of application, absence of rejection or immune reactions and the potential ability to maintain a fibrocartilaginous structure such as the meniscus in a stable position, it was a fixation option. A report on the transplantation of menisci preserved by deep-freezing in dogs using suture or fibrin glue showed no statistically significant differences between the two groups after 12 weeks of observation[26]. The authors analyzed the role of fibrin coagulation on the repair process at the meniscosynovial junction, noting that the use of fibrin glue may be useful in reducing postoperative immobilization and facilitating the rehabilitation process in transplant patients. Despite the satisfactory results, there are no reports of continuing this line of research. This question regarding the literature was certainly a determining factor for the initiation of our study. In our study, the fibrin adhesive promoted excellent fixation immediately after application, maintaining adequate stability of the meniscus in flexion-extension movements of the knee. However, not fixing the two horns of the menisci to the synovial membrane and/or soft tissues of the joint, or partial fixation, was the norm in the three observation times (Table 1). Total fixation was an exception, thus the effectiveness of fibrin glue was less than that of the suture technique, with statistically significant results, not coinciding with the results found by Nabeshima *et al*.[26]

Fibrin is considered to be a stimulant of the healing process in the literature because it is a biological product that is involved in the process of tissue repair. In other tissues, adhesive ability is associated with the ability to stimulate healing, hence the proposal of an in vivo study. There is another ongoing study in which the forces of traction, torsion and compression of the menisci are being tested ex vivo. A special apparatus developed in conjunction with mechanical engineering is undergoing tests to measure these parameters.

Suturing the soft tissues showed similar results in all three assessment periods and a statistically higher percentage of fixation when compared with the fibrin glue technique. Our results agree with the experimental studies in the literature, which also show a high rate of healing of the meniscus to the recipient when suturing to soft tissue[9,12,15,18,28].

The sutured menisci showed no change in the texture of their surfaces and were very similar in appearance to the normal lateral meniscus in all of the observation times considered (Figures 2 and 3). In turn, the meniscus fixed with fibrin showed a thin layer of yellowish secretion covering the surface (Figure 4).

CONCLUSION

Our results showed that over two, four, and eight weeks of observation, the meniscus preserved by deep-freezing fix themselves more adequately by suturing to the soft tissues of the knee joint of rabbits. On the other hand, fibrin glue, although free of inflammatory reaction or processes that indicate rejection, was unable to keep the meniscus fixed to the tibial plateau and thus is not, as supposed, a viable option for this transplant surgery.

ACKNOWLEDGMENTS

The authors thank Professor Maria do Carmo Negrini Fagundes for her revision of the Portuguese and an English version of the abstract.

REFERENCES

1. Lee DH, Kim TH, Lee SH, Kim SW, Kim JM, Bin SI. Evaluation of meniscus allograft transplantation with serial magnetic resonance imaging during the first postoperative year: focus on graft extrusion. Arthroscopy. 2008;24(10):1115-21.
2. Wirth CJ, Peters G, Milachowski KA, Weismeier KG, Kohn D. Long term results of meniscal allograft transplantation. J Sports Med Am. 2002;30(2):174-81.
3. Yamasaki T, Deie M, Shinomiya R, Yasunaga Y, Yanada S, Ochi M. Transplantation of meniscus regenerated by tissue engineering with a scaffold derived from a rat meniscus and mesenchymal stromal cells derived from rat bone marrow. Artif Organs. 2008;32(7):519-24.
4. Ellingson CI, Sekija JK. Current opinion in meniscal allograft transplantation. Curr Opin Orthop. 2004;15(2):79-85.
5. Sgaglione NA, Steadman R, Shafter B, Miller MD, Fu FH. Current concepts in meniscus surgery: resection to replacement. Arthroscopy. 2003;19(10):161-88.
6. Felix NA, Paulos LE. Current status of meniscal transplantation. Knee. 2003;10(1): 13-7.
7. Lewinski G. Meniscal allograft transplantation. Orthopade. 2008;37(8):743-8.
8. Cardoso TP. Prótese meniscal de polímero bioabsorvível: estudo em coelhos [tese]. São Paulo: Faculdade de Medicina, Universidade de São Paulo; 2002.
9. Cury RPL, Camargo OPA, Próspero JD, Botter FCS, Severino NR, Aihara T, *et al*. Transplante homólogo de meniscos: estudo experimental em coelhos. Rev Bras Ortop. 2002;37(8):341-.9.
10. Gelber PE, Gonzáles G, Lloret JL, Reina F, Cáceres E, Monllau JC. Freezing causes changes in the meniscus collagen net: a new ultrastructural meniscus disarray scale. Knee Surg Sports Traumatol Arthrosc. 2008;16(4):353-9.
11. Andersson-Molina H, Karlsson H, Rockborn P. Arthroscopic partial and total meniscectomy: Long-term follow-up study with matched controls. Arthroscopy. 2003;18(2):183-9.
12. Sekiya JK, Ellingson CI. Meniscal allograft transplantation. J Am Acad Orthop Surg. 2006;14(3):164-74.
13. Reckers LJ. A relação entre diferentes temperaturas e períodos de preservação sobre a celularidade de meniscos de coelhos [tese]. São Paulo: Universidade Federal de São Paulo - UNIFESP; 2004.
14. Reckers LJ, Fagundes DJ, Cohen M, Raymundo JLP, Moreira MB, Paiva VC. Effects of different preservation temperatures and periods menisci cellularity in rabbits. Acta Cir Bras. 2005;20(6):428-33.
15. Sgaglione NA, Steadman R, Shafter B, Miller MD, Fu FH. Current concepts in meniscus surgery: resection to replacement. Arthroscopy. 2003;19(10):161-88.
16. Uchio Y, Ochi M, Adachi N, Kawasaki K, Iwasa J. Results of rasping of meniscal tears with and without anterior cruciate ligament injury as evaluated by second-look arthroscopy. Arthroscopy. 2003;19:463-9.
17. Sohn DH, Toth AP. Meniscus transplantation: current concepts. J Knee Surg. 2008;21(2):163-72.
18. Verdonk PCM, Verstraete KL, Almqvist KF, De Cuyper K,Veys EM, Verbruggen G, Verdonk R. Meniscal allograft transplantation: long-term clinical results with radiological and magnetic resonance imaging correlations. Knee Surg Sports Traumatol Arthrosc. 2006;7:1-13
19. Mora G, Alvarez E. Articular cartilage degeneration after frozen meniscus and achilles tendon allograft transplantation: experimental study in sheep. Arthroscopy. 2003;19(8):833-41.
20. Pasa L, Pokorny V, Kalandra S, Melichar I, Bilik A. Transplantation of deep frozen menisci. Acta Chir Orthop Traumatol Cech. 2008;75(1):40-7.
21. Fontes CR, Taha MO, Fagundes DJ. Estudo comparativo do uso de cola de fibrina e cianoacrilato em ferimento de fígado de rato. Acta Cir Bras. 2004;19(1):37-42.
22. Reckers LJ, Fagundes DJ, Cohen M, Raymundo JLP, Moreira MB, Paiva VC. Medial meniscus transplantation using cyanoacrylate in rabbits. Acta Cir Bras. 2006;21(2):92-6.
23. Taha MO, Mueller SF, Fraga MM, Rosseto M, Fagundes DJ, Juliano Y, Caricati-Neto A. Morphologic analysis of the fibular nerve repaired with fibrin adhesive. Transplant Proc. 2004;36(2):401-3.
24. Amaral AT, Taha MO, Fagundes DJ. Estudo morfológico das entero-anastomoses com suturas em pontos separados complementados com adesivo sintético ou biológico em coelho. Acta Cir Bras. 2004;19(4):393-405.
25. Fagundes DJ, Taha MO, Rivoire HC. Adesivos cirúrgicos. Revisão e atualização JBM. 2002; 82(3):101-3.
26. Nabeshima Y, Kurosaka M, Yoshiya S, Mizuno K. Effect of fibrin glue and endothelial cell growth factor on the early healing response of the transplanted allogenic meniscus: a pilot study. Knee Surg Sports Traumatol Arthrosc. 1995;3(1):34-8.
27. Reckers LJ, Fagundes DJ, Cohen M. The ineffectiveness of fibrin glue and cyanoacrylate on fixation of meniscus transplantation in rabbits. Knee. 2009;16(4):290-4.
28. von Lewinski G, Milachowski KA, Weismeier K, Kohn D, Wirth CJ. Twenty-year results of combined meniscal allograft transplantation, anterior cruciate ligament reconstruction and advancement of the medial collateral ligament. Knee Surg Sports Traumatol Arthrosc. 2007;15(9):1072-82.