ANALYSIS OF THE SEGMENTAL IMPACTION OF FEMORAL HEAD FOLLOWING AN ACETABULAR FRACTURE SURGICALLY MANAGED

Rodrigo Pereira Guimarães[1], Camila Cohen Kaleka[2], Carina Cohen[2], Daniel Daniachi[3], Nelson Keiske Ono[4], Emerson Kiyoshi Honda[5], Giancarlo Cavalli Polesello[6], Walter Riccioli Junior[7]

ABSTRACT

Objective: Correlate the postoperative radiographic evaluation with variables accompanying acetabular fractures in order to determine the predictive factors for segmental impaction of femoral head. Methods: Retrospective analysis of medial files of patients submitted to open reduction surgery with internal acetabular fixation. Within approximately 35 years, 596 patients were treated for acetabular fractures; 267 were followed up for at least two years. The others were excluded either because their follow up was shorter than the minimum time, or as a result of the lack of sufficient data reported on files, or because they had been submitted to non-surgical treatment. The patients were followed up by one of three surgeons of the group using the Merle d'Aubigné and Postel clinical scales as well as radiological studies. Results: Only tow studied variables – age and amount of postoperative reduction- showed statistically significant correlation with femoral head impaction. Conclusions: The quality of reduction – anatomical or with up to 2mm residual deviation – presents a good radiographic evolution, reducing the potential for segmental impaction of the femoral head, a statistically significant finding.

Keywords – *Acetabulum/injuries; Hip fractures; Acetabulum /surgery; Femur head necrosis*

INTRODUCTION

With the increasing number of high-energy traumas, caused mainly by car accidents, coupled with improvement in the rescue systems for polytraumatized patients, there has been an increase in the number of patients with acetabular fractures arriving at referral hospitals[1].

The acetabulum is part of the hip joint, and is surrounded by ligaments, muscles, vessels, and nerves. It presents individual anatomical features, which makes access difficult for less experienced orthopedic surgeons. However, starting in 1964 with the studies of Judet *et al*., which correlated anatomical characteristics with radiographic aspects and intraoperative findings, creating a topographical classification capable of guiding the access pathway, the understanding of these lesions became more logical[2,3].

Currently, surgical treatment of deviated acetabular fractures is the consensus. However, the large number of complications inherent in these fractures that accompany surgery may influence the final result[4-10].

1 – Education Teacher, FCMSCSP; Assistant, Hip Group, Department of Orthopedics and Traumatology, School of Medical Sciences, Santa Casa de São Paulo (FCMSCSP), São Paulo, Brazil.
2 – Resident, Department of Orthopedics and Traumatology, FCMSCSP, São Paulo, Brazil.
3 – Orthopedist; Volunteer, Hip Group, Department of Orthopedics and Traumatology, FCMSCSP, São Paulo, Brazil.
4 – Assistant Professor and Physician, FCMSCSP; Head, Hip Group, Department of Orthopedics and Traumatology, FCMSCSP, São Paulo, Brazil.
5 – Education Teacher and Physician, FCMSCSP; Senior Member, Hip Group, Department of Orthopedics and Traumatology FCMSCSP, São Paulo, Brazil.
6 – Assistant Professor and Physician, FCMSCSP; Assistant, Hip Group, Department of Orthopedics and Traumatology, FCMSCSP, São Paulo, Brazil.
7 – Orthopedist; Assistant, Hip Group, Department of Orthopedics and Traumatology, FCMSCSP, São Paulo, Brazil.

Study conducted at the Department of Orthopedics and Traumatology, School of Medical Sciences, Santa Casa de São Paulo (FCMSCSP) – Director: Dr. Osmar Avanzi.
Correspondence: Santa Casa de São Paulo – Departamento de Ortopedia e Traumatologia: Grupo do Quadril. Rua Cesário Motta Junior, 112. São Paulo, SP – Brasil.
E-mail: ddaniachi@hotmail.com

We declare no conflict of interest in this article

One of the complications that appears early is the segmental collapse of the femoral head, referred to as joint wear by some authors and as necrosis by others[2,4,7,10-12].

The objective of this study is to correlate postoperative radiographic changes with the variables that accompany acetabular fractures in order to define what has predictive value in the emergence of segmental collapse of the femoral head.

METHODS

A retrospective evaluation of medical records was performed of 596 patients undergoing treatment of acetabular fractures at the Department of Orthopedics and Traumatology, Santa Casa de Misericórdia de São Paulo, "Fernandinho Simonsen" Pavilion, in the period between 1972 and 2006. Of these, 267 records were analyzed. We excluded patients who underwent nonoperative treatment, those who did not have a minimum postoperative period of two years, or when they did not bring all the necessary information to our study.

Each patient had a single fracture. The left side was affected in 152 cases (56.9%) and the right side in 115 cases (43.1%). The interval between the fracture and fixation varied between one and 90 days, with the average being 13.4 days. The follow-up period was 24 months and we performed the evaluation at the end of this period. The patients' ages ranged from 11 to 87 years with a mean age of 33.9 years at the time of fracture. Regarding gender, 72 (27%) women and 195 (73%) men were treated.

All patients underwent radiographic evaluation, which is a standardized examination in the clinic, with the bulb within one meter from the frame of the film. Radiographs were evaluated in three views: anteroposterior, oblique, and posterior oblique. The initial deviation was measured in the three views and the highest value detected was recorded (Figure 1). The postoperative radiographic evaluation was performed in the same way and the largest deviation observed was recorded (Figure 2).

The collapse of the femoral head was characterized by a loss of sphericity of the femoral head with flattening of the load-bearing area that is usually associated with sclerosis of the subchondral area (Figure 3).

Regarding the type of trauma, 133 (49.8%) were the result of an automobile accident, 50 (18.7%) were run over, 46 (17.2%) fell from a height, and 38 (14.2%) were the result of a motorcycle accident.

The initial deviation observed in 24 fractures (9%) was less than 4 mm, in 94 fractures (35.2%) it was between 4 and 10 mm, and in 149 fractures (55.8%) it was greater than 10 mm.

Dislocation was observed in 91 cases (34.1%), comminution in 95 cases (35.6%), fracture of the pelvis in 55 cases (20.6%), sciatic nerve injury in 29 cases (10.9%), and injury to the femoral head in 13 cases (4.9%).

Surgical treatment was recommended when the initial deviation was greater than 2 mm or when the fracture was unstable. Some fractures with surgical indication, however, were treated using a closed approach because of medical problems associated with the trauma.

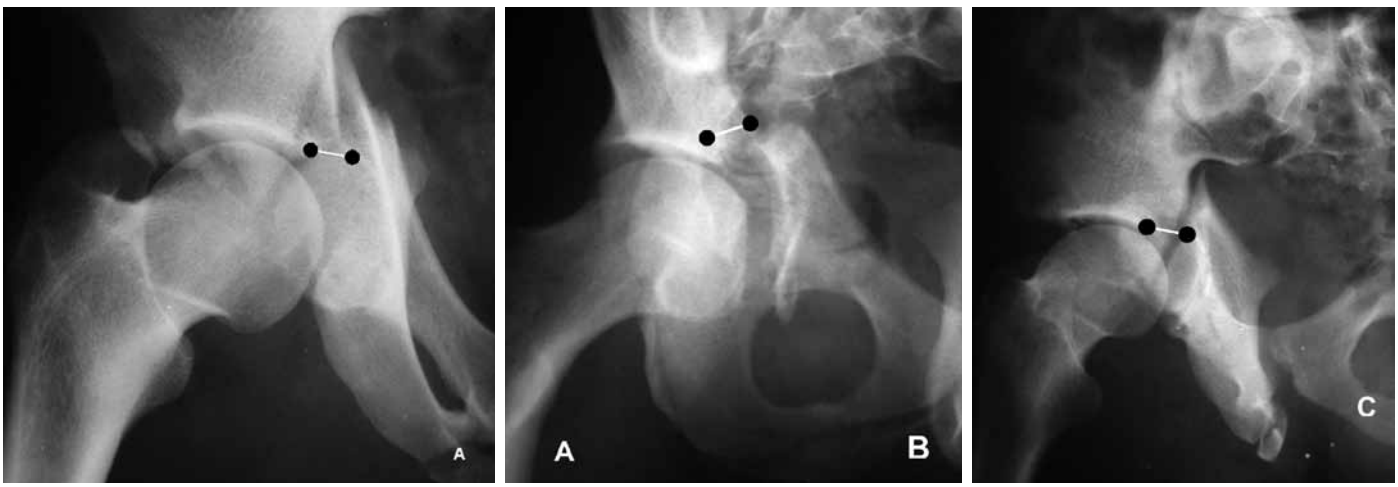

Figure 1 – Measurement of the initial deviation: anteroposterior (A), oblique (B), and posterior oblique (C) views



Figure 2 – Initial reduction of the fracture with maintenance of the deviation



Figure 3 – Segmental collapse of the femoral head

With respect to residual postoperative deviation, anatomical reduction was observed in 151 cases (56.5%), with deviation up to 2 mm in 60 cases (22.4%); the reduction was greater than 2 mm in 56 cases (20.9%).

Outpatient monitoring was performed by one of the group's three surgeons, who made use of the clinical assessment scale of Merle d'Aubigné and Postel[13] and radiological studies during return visits at the end of the first and third months, and every three months from then until one year after surgery. In the second year return visits were scheduled semestrally, and annually after that.

The variables were summarized and represented by the relevant descriptive statistics: mean, standard deviation (SD), median, minimum and maximum values, or absolute and relative frequency (%).

We used the Student's t-test or the Mann-Whitney test for unrelated samples when comparing the groups with and without the presence of collapse in relation to quantitative variables, depending on whether the variables within the groups followed a normal distribution or not.

The qualitative variables of the groups were compared by Pearson's chi-square test or the likelihood ratio chi-square test.

We adopted a significance level of 0.05 or 5% (alpha $\leq$ 0.05, p $\leq$ 0.05) and SPSS version 15.0 for Windows was used for all analyses.

RESULTS

We analyzed 267 complete medical records of patients with acetabular fractures treated surgically, of which 16 (6%) developed collapse of the femoral head.'

The incidence of collapse was correlated with gender, age, type of trauma, the classification of Judet *et al*.[2], deviation, dislocation, comminution, fracture of the femoral head, fracture of the pelvis, sciatic nerve injury, type of treatment, access pathway, and quality of postoperative reduction.

Only two of the variables analyzed, age and postoperative reduction, showed a statistically significant correlation with the collapse of the femoral head. The quality of the reduction is a predictive factor for the emergence of segmental collapse of the femoral head (Table 1).

Table 1 – Statistically significant variables with the collapse of the femoral head (age and postoperative reduction)

Variables	*Collapse*		**Total** *(n = 267)*	**p**
	No (n=251)	**Yes (n=16)**		
Age (years)				
Mean (sd)	*33.6 (12.8)*	*40.7 (15.4)*	*34.0 (13.0)*	
Median	*30*	*37*	*31*	*0.034* *
Minimum – maximum	*14-87*	*11-65*	*11-87*	
Postoperative reduction n (%)				
0	*149 (59.4)*	*2 (12.5)*	*151 (56.6)*	
2	*56 (22.3)*	*4 (25.0)*	*60 (22.5)*	*<0.001**
> 2	*46 (18.3)*	*10 (62.5)*	*56 (21.0)*	

DISCUSSION

Acetabular fractures are classically caused by high-energy traumas. Because these fractures result

from these traumas, they most frequently affect young individuals in the productive phase of life because they are more exposed to this type of event[1,4,14].

The treatment options varied over the years. Until the 1970s, closed treatment was the most commonly used; however, the poor results and the fact that this type of fracture is focused on a young and economically active population encouraged orthopedic surgeons to seek new forms of treatment[4,6,10].

Judet *et al*.[2] fostered a significant change in the approach to these fractures, as their studies allowed for the treatment systematization. Since then, surgical treatment, which had been only one of the options, has become the treatment of choice[4].

Due to the causes of these fractures, they were expected to be accompanied by complications. The primary complication in fractures of the acetabulum is post-traumatic arthritis; other complications include nonunion, shortening of the affected limb, myositis ossificans, neurological and vascular changes, segmental collapse, femoral head necrosis, among others[2,4,5,15-21].

Among the most common complications are osteoarthritis of the hip and avascular necrosis of the femoral head, both of which are diagnosed radiographically[4,10,12,17,22,23]. However, Catto cautions that avascular necrosis is a change in tissue that does not manifest radiographically and that the term necrosis is probably a late recognition of the collapse of the femoral head[24].

Gruen *et al*.[25] report that avascular necrosis of the femoral head secondary to trauma has historically been cited as a complication of acetabular fracture; however, they argue that impingement is the cause of changes in the shape of the head and not avascular necrosis. They report that the so-called "radiographic signs of avascular necrosis of the femoral head" have no clinical correlation. They note that if post-traumatic osteoarthritis develops in the presence of viable acetabular cartilage, it is primarily a result of altered distribution of pressure forces.

The decrease in the area of contact between the articular surface of the femoral head and the acetabulum, caused by poor fracture reduction, leads to increased pressure on the cartilage and the underlying bone. This results in loss of joint space and, sometimes, in wear of the femoral head[25,26].

In our opinion, the general principles of treatment of articular fractures should be applied to the hip joint, even more so because it is a weight-bearing joint with a large range of motion.

The collapse of the femoral head is usually attributed to avascular necrosis, transferring the responsibility of what happened to the initial trauma and to the associated avascular injury.

In the analysis of cases there was a statistically significant correlation between the collapse and poor fracture reduction, and we therefore believe that this is a determining variable of the process. We do not want to exclude avascular necrosis as a factor that may also cause the collapse of the femoral head.

The average age of the group with collapse was significantly higher than the group without collapse, with 40.7 years and 33.6 years, respectively, in our study. Such data should be viewed with caution given the small number of cases with collapse.

CONCLUSIONS

The analysis of the medical records of 267 patients (267 hips) treated for acetabular fractures and a review of the literature allow us to conclude that the quality of the reduction, anatomical or with residual deviation of up to 2 mm, presents satisfactory radiographic progress, decreasing the likelihood of the segmental collapse of the femoral head, a finding that has statistical significance.

REFERENCES

1. Geoghegan JM, Longdon EJ, Hassan K, Calthorpe D. Acetabular fractures in the UK. What are the numbers? Injury. 2007;38(3):329-33.
2. Judet R, Judet J, Letournel E. Fractures of the acetabulum: classification and surgical approaches for open reduction. Preliminary Report. J Bone Joint Surg Am. 1964;46:1615-46.
3. Beaulé PE, Dorey FJ, Matta JM. Letournel classification for acetabular fractures. Assesment of interobserver and intraobserver reliability. J Bone Joint Surg Am. 2003;85(9):1704-9.
4. Giannoudis PV, Grotz MR, Papakostidis C, Dinopoulos H. Operative treatment of displaced fractures of the acetabulum: a meta-analysis. J Bone Joint Surg Br. 2005;87(1):2-9.

5. Aristide RSA, Honda E, Polesello G, Fernandez MS. Fratura em "T" do acetábulo: análise de 45 casos. Rev Bras Ortop. 1996;31(11):919-24.
6. Knop T, Silva LHP, Laghi R. Fraturas acetabulares: resultados de tratamento cirúrgico. Rev Bras Ortop. 1996;31(10):825-30.
7. Matta JM. Fractures of the acetabulum: accuracy of reduction and clinical results in patients managed operatively within three weeks after the injury. J Bone Joint Surg. 1996;78(11):1632-45.
8. Liebergall M, Mosheiff R, Low J, Goldvirt M, Matan Y, Segal D. Acetabular fractures. Clinical outcome of surgical treatment. Clin Orthop Relat Res. 1999;(366):205-16.
9. Barbosa ALH, Schutz PC, Pavan L. Tratamento cirúrgico das fraturas de acetábulo: estudo retrospectivo de 48 casos. Acta Ortop Bras. 2000;8(3):140-3.
10. Laird A, Keating JF. Acetabular fractures: a 16-year prospective epidemiological study. J Bone Joint Surg Br. 2005;87(7):969-73.
11. Letournel E. Acetabulum fractures: classification and management. Clin Orthop Relat Res. 1980;(151):81-106.
12. Köberle G, Miranda JB, Yamanaka E, Grava ALS, Belangero WD. Fraturas do acetábulo: estudo dos resultados clínicos do tratamento cirúrgico precoce e tardio. Rev Bras Ortop. 1993;28(6):361-6.
13. D'Aubgné RM, Postel M. Functional results of hip arthroplasty with acrylic prosthesis. J Bone Joint Surg Am. 1954;36(3):451-75.
14. Glas PY, Fessy MH, Béjui-Hugues J. Surgical treatment of acetabular fractures: outcome in a series of 60 consecutive cases. Rev Chir Orthop Reparatrice Appar Mot. 2001;87(6):529-38.
15. Vaughan GT. Central dislocation of the femur. Surg Gynec Obstet. 1912;15:249-51.
16. Armstrong JR. Traumatic dislocation of the hip joint. Review of one hundred and one dislocations. J Bone Joint Surg Am. 1948;30B(3):430-45.
17. Letournel E. Fractures of the acetabulum. A study of a serie of 75 cases. J Chronic Dis. 1961;82:47-87.
18. Mayo KA. Open reduction and internal fixation of fractures of the acetabulum. Clin Orthop Relat Res. 1994;(305):31-7.
19. Mayo KA, Letournel E, Matta JM, Mast JW, Johnson EE, Martimbeau CL. Surgical revision of malreduced acetabular fractures. Clin Orthop Relat Res. 1994;(305):47-52.
20. Issack PS, Toro JB, Buly RL, Helfet DL. Sciatic nerve release following fracture or reconstructive surgery of the acetabulum. J Bone Joint Surg Am. 2007;89(7):1432-7.
21. Madhu R, Kotnis R, Al-Mousawi A, Barlow N, Deo S, Worlock P, *et al*. Outcome of surgery for reconstruction of fracture of the acetabulum: the time dependent effect of delay. J Bone Joint Surg Br. 2006;88(9):1197-203.
22. Rowe CR, Lowell D. Prognosis of fractures of the acetabulum. J Bone Joint Surg Am. 1961;43(1):30-58.
23. Ruesch PD, Holdener H, Ciaramitaro M, Mast JW. A prospective study of surgically treated acetabular fractures. Clin Orthop Relat Res. 1994;(305):38-46.
24. Catto M. A histological study of avascular necrosis of the femoral head transcervical fracture. J Bone Joint Surg Br. 1965;47(4):749-75.
25. Gruen GS, Mears DC, Tauxe WN. Distinguishing avascular necrosis from segmental impaction of the femoral head following an acetabular fracture: preliminary report. J Orthop Trauma. 1988;2(1):5-9.
26. Olson SA, Bay BK, Chapman MW, Sharkey NA. Biomechanical consequences of posterior wall acetabular fractures and repair. J Bone Joint Surg Am. 1995;77(8):1184-92.