


Postoperative Chronic Osteomyelitis in the Long Bones – Current Knowledge and Management of the Problem*

Osteomielite crônica pós-operatória nos ossos longos – O que sabemos e como conduzir esse problema

Lourenço Galizia Heitzmann¹  Raphael Battisti¹ Ayres Fernando Rodrigues¹
Juliano Valente Lestingi¹ Cinthya Cavazzana¹ Roberto Dantas Queiroz¹

¹ Orthopedics and Traumatology Service, Hospital do Servidor Público Estadual Francisco Morato de Oliveira, São Paulo, SP, Brazil

Address for correspondence Lourenço Galizia Heitzmann, MD, Serviço de Ortopedia e Traumatologia, Hospital do Servidor Público Estadual Francisco Morato de Oliveira, São Paulo, SP, Brasil (e-mail: lourenco@heitzmann.com.br).

Rev Bras Ortop 2019;54:627–635.

Abstract

Chronic postoperative osteomyelitis represents an important health problem due to its significant morbidity and low mortality rate. This pathology is challenging because of difficulties in understanding the pathogenesis and the decision-making involving the treatment. The present article had the goal of reviewing the definition, pathogenesis, clinical aspects, diagnosis, and treatment of chronic postoperative osteomyelitis, and of gathering this information in a single Brazilian updated publication.

Keywords

- ▶ osteomyelitis
- ▶ postoperative complications
- ▶ bacterial infections

The PubMed, LILACS, and the Cochrane Library medical databases were analyzed using pertinent keywords. Current and relevant articles were selected.

The present article gathered the established information, as well as innovations related to chronic osteomyelitis and its treatment, to offer updated data to assist the professionals involved in the management of chronic osteomyelitis.

Resumo

A osteomielite crônica pós-operatória é um problema de saúde importante devido à sua morbidade significativa e baixa taxa de mortalidade. Essa patologia se apresenta como um desafio do ponto de vista de compreensão da patogenia e também de escolha da estratégia de tratamento. O objetivo deste artigo foi revisar o tema proposto quanto à sua definição, patogenia, aspectos clínicos, diagnóstico e tratamento, e reunir todas essas informações em uma única publicação brasileira de caráter de atualização.

Foram feitas buscas nas bases de dados PubMed, Lilacs e Cochrane Library, com palavras-chave pertinentes ao tema, e foram escolhidos trabalhos atuais e de relevância.

Este trabalho permitiu reunir informações clássicas e inovações relacionadas à osteomielite crônica e seu tratamento, e oferecer material de atualização para auxiliar os profissionais envolvidos no tratamento dessa doença na tomada de decisão terapêutica.

Palavras-chave

- ▶ osteomielite
- ▶ complicações pós-operatórias
- ▶ infecções bacterianas

* Originally Published by Elsevier.

received
July 12, 2017
accepted
December 14, 2017

DOI <https://doi.org/10.1016/j.rbo.2017.12.013>.
ISSN 0102-3616.

Copyright © 2019 by Sociedade Brasileira de Ortopedia e Traumatologia. Published by Thieme Revinter Publicações Ltda, Rio de Janeiro, Brazil

License terms



Introduction

As a medical term, osteomyelitis has been present in the specialized literature since its description by Nelaton, in 1844, as an inflammatory process of infectious origin in the bones. However, the clinical manifestation as a secretory wound after injury has been mentioned throughout history since carved plates in Sumer. The treatment was based on keeping the wound open for the elimination of purulent discharge and the local application of ointments and other substances.

The advent of anesthesia and the expansion of surgical procedures, as well as the discovery of antibiotics, resulted in significant changes in the clinical and surgical treatments of osteomyelitis.¹

Chronic osteomyelitis is defined as an infectious disease sustained for more than a month. Its causes include an incorrectly-treated acute infectious process, and contiguous bone infection from chronic adjacent soft tissue infection.

Postoperative chronic osteomyelitis represents a major health problem due to its significant morbidity and low mortality rate.^{2,3} This infection occurs in approximately 5 to 50% of open fractures and in less than 1% of osteosynthetic closed fractures; in addition, 5% result from an acute hematogenous spread.³ The main problem associated with chronic bone infection is the ability of the organisms to stay in necrotic bone tissues with increased survival.

In short, this subject has been continuously revised and updated regarding the understanding of its pathogenesis, classifications and treatment options with the advent of new surgical techniques and drug innovations.

The present paper aims to review the definition, pathogenesis, clinical aspects, diagnosis, and treatment of chronic postoperative osteomyelitis, gathering all of this information in a single Brazilian updated publication.

Materials and Methods

In order to prepare this literature update article, data were collected by querying scientific papers in the PubMed, BVS-LILACS and Cochrane Library databases. Three keywords (MeSH terms) that were relevant to the proposed subject were selected: *osteomyelitis*, *chronic* and *long bones*.

In the PubMed database, the terms were searched in isolation and in combination (*osteomyelitis AND chronic*; *osteomyelitis AND long bones*). The papers filtered for inclusion were mainly overviews and clinical practice guidelines. Studies on vertebral or pelvic chronic osteomyelitis related to joint prosthesis and hematogenous-only infection, or those involving only the pediatric population, were excluded.

In the BVS-LILACS database, the three terms were concurrently applied to the same search, and the same exclusion criteria were applied.

In the Cochrane Library, the term *chronic osteomyelitis* was used to retrieve systematic reviews.

Results

The PubMed database search found 75 papers with the first term combination (*osteomyelitis AND long bones*) and 587 papers with the second combination (*osteomyelitis AND chronic*) when applying the aforementioned inclusion and exclusion criteria. The BVS-LILACS database search resulted in 142 papers. The information used to prepare this review came from the retrieved material, in addition to their cited bibliographic sources through a subsequent direct search. In the Cochrane Library, only two systematic reviews of osteomyelitis were found.

Current papers, in addition to those considered most relevant and of high-quality, were selected to prepare this update.

Discussion

The medical knowledge gathered through the literature search on chronic osteomyelitis in the long bones can be didactically organized in the following topics: definition (as previously explained), classification, pathogenesis and aspects related to disease development, clinical manifestations, clinical diagnosis, armed propaedeutic and treatment.

Osteomyelitis classification

The evolution of the medical understanding on osteomyelitis has resulted in the proposition over time of several classification systems.

Historically, there are the etiological classifications of Kelly, Weiland and May; however, these systems are currently little used and disseminated. The two most widely employed classifications in the medical literature are those of Lew and Waldvogel³ and of Cierny and Mader and Cierny et al.⁵

Lew and Waldvogel³ classify osteomyelitis as having three potential etiologies: hematogenous, contiguous and chronic.

Cierny and Mader⁴ and Cierny et al⁵ considered the bone involvement pattern according to the etiology (types 1 to 4) (► Fig. 1) and the conditions of the host (types A, systemic B, local B, systemic and local B, C). This classification has the aim of guiding treatment decisions.

Type 1–intramedullary lesion, usually due to intramedullary pinning.

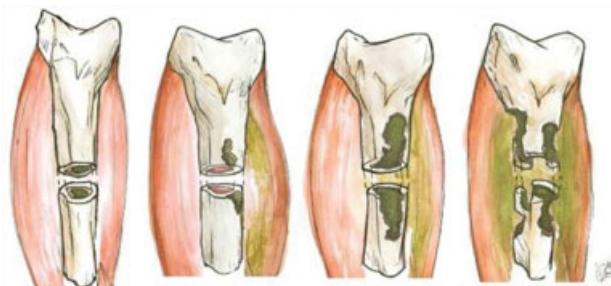

Fig. 1 Cierny and Mader classification for osteomyelitis according to the pattern of bone involvement. Type 1, spinal cord; type 2, superficial; type 3, stable permeative; type 4, unstable permeative osteomyelitis.

Type 2–superficial lesion, usually due to pressure ulcer contiguity.

Type 3–stable permeative lesion, in which the infection penetrates the cortical layer and gains access to the medulla, but the bone remains biomechanically stable (that is, it supports load). This type is usually observed in the postoperative period in cases of infection after plaque osteosynthesis.

Type 4–unstable permeative lesion, in which the infection is extensive, affects the cortical and medullary layers, and the bone is biomechanically unstable. It may occur after aggressive infection or extensive debridement.

Host A – healthy patient and limbs.

Host B, systemic type – history of diabetes mellitus, senility, alcohol or drug use, immunodeficiencies.

Host B, local B type – previous local burn, scar, cellulitis, previous surgery, local vascular disease.

Host B, both systemic and local types – combined systemic and local involvement.

Host C – multiple comorbidities make the patient unable to tolerate the treatment.^{4–6}

Pathogeny and biofilm

The pathogenic understanding has also changed with the knowledge on bacteria behavior in biofilm formation. This knowledge enabled us to understand the phenomena of infection recurrence, antibiotic resistance, and the impact of surgical implantation on the infected site.^{1,7}

There are two forms of biofilm-forming bacteria: planktonic and fixed. In the planktonic (free) form, the bacteria are free outside the extracellular matrix, being isolated and vulnerable to host defense mechanisms. However, in high volumes, planktonic bacteria can migrate into the bloodstream, resulting in septicemia. Planktonic bacteria may

adhere to a surface, such as necrotic tissue or foreign matter (surgical implant), becoming fixed. In the fixed (sessile) form, sessile bacteria usually form a polysaccharide biofilm on the tissue surfaces or implants.

After colonization and biofilm formation, bacteria may remain inert or cause an infection. An infection in the presence of biofilm is more resistant to antibiotics. This is due to the fact that the antibiotic agent is not able to successfully pass through the glycocalyx (outer layer) of the biofilm (that is, there is a low-concentration gradient in the region occupied by bacteria). At the core of the colony, bacteria are in a low metabolic state, hindering the action of certain antibiotics. This may explain the greater antibiotic resistance in chronic infections (with more latent bacteria) compared to acute infections^{7,8} (► Fig. 2).

The interaction between the colony, the host tissue and the immunological response may lead to the formation of encapsulated necrotic bone, which may also be colonized, resulting in bone sequestration.⁷ This collection can protrude, forming a sinus tract up to the skin, leading to a fistula⁹ (► Fig. 3).

Fractures and infection

Fracture-related osteomyelitis usually occurs in cases of bone exposure or after surgical treatment (with or without implant placement). In open fractures, contamination is certain. The determinants associated with the evolution from contamination to infection include the immune response of the host, the ability of the mechanical cleanliness to lower the local bacterial concentration, and debridement to leave healthy and viable wound tissue less susceptible to bacterial adherence.

Microbiology

The bacteria usually identified in acute exposed wounds are not the ones that will cause chronic infection. The most aggressive hospital pathogens gain importance in these open

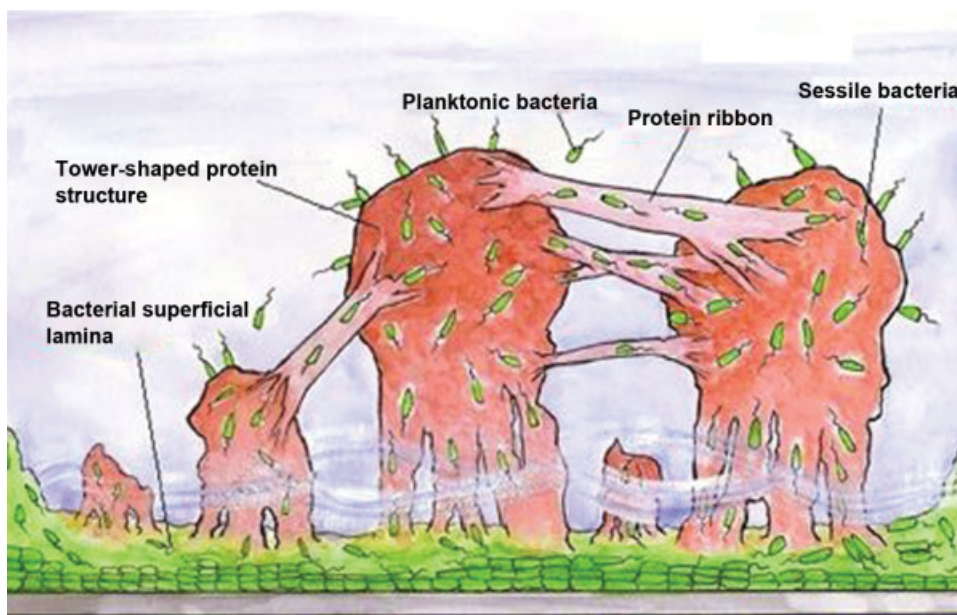


Fig. 2 Structural model of bacterial biofilm. Note the presence of bacterial superficial lamina adhered to the metallic material, the protein tower structure filled with bacteria in transit, the fluid at the base of the towers, and protein strips enabling bacterial transit. Planktonic bacteria are present around the biofilm.

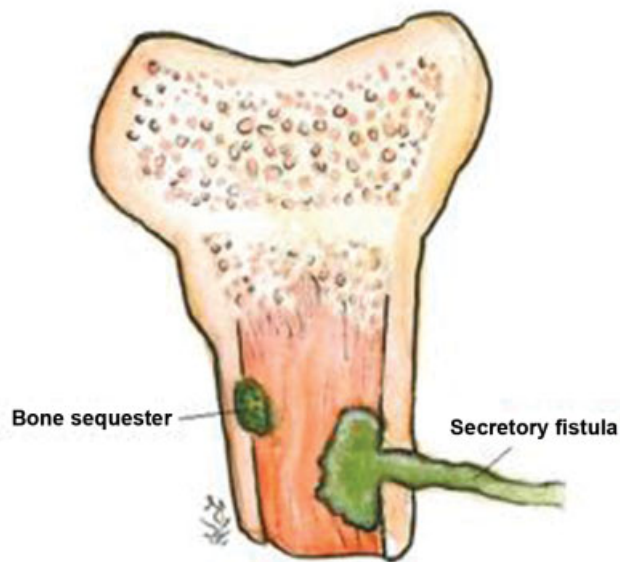


Fig. 3 Interaction phenomena between the infectious tissue and the host result in bone sequestration and fistula formation.

fracture cases, as they can contaminate and cause infection within days of the accident, even after the proper initial treatment with cleaning and debridement.³

Chronic osteomyelitis, usually due to an incorrectly-treated acute infection or a postsurgery infection, may be caused by a pathogen from the typical hospital flora (*Pseudomonas aeruginosa*, other Gram-negative organisms, *Staphylococcus aureus*), or have a polybacterial origin.⁸

Fungal osteomyelitis is more common in immunocompromised or diabetic patients, or those with indwelling catheters. Dissemination can be hematogenous or contiguous, and the most common agent is *Candida sp.*^{1,3}

Evaluation and diagnosis

Patient assessment begins with a detailed anamnesis for the evaluation of the clinical history. Information such as previous focal or systemic infections may raise suspicion of infectious spread to a particular site, whether it is a recent or remote event. History of previous trauma leading to local skin or soft tissue complication is also relevant. The occurrence of fracture and its characteristics, such as degree of exposure and performed treatment (surgery for local cleaning, fracture fixation, debridement, presence of an implant or foreign body) are fundamental during the initial approach.

Specific manifestations may include deep local (bone) pain, heat sensation, edema and skin rash, as well as general symptoms, such as inappetence and fever. Purulent secretory surgical wounds or formation of cutaneous fistulas are also very suggestive findings at inspection.⁷

The relevant laboratory tests include complete blood counts (CBCs), since leukocytosis is the main suggestive marker in acute infections. In chronic osteomyelitis, however, white blood cell (WBC) counts may be normal. Inflammatory markers, such as erythrocyte sedimentation rate (ESR) and serum C-reactive protein (CRP), increase in the acute phase of the infection and after surgical manipulation; CRP and ESR

levels peak on the third and fifth days after manipulation respectively. C-reactive protein levels return to baseline within three weeks, while ESR normalization takes longer. A new peak in CRP three days after surgical manipulation or the beginning of the antibiotic therapy is suggestive of reinfection or treatment failure. Normal values on both tests are excellent predictors of absence of osteomyelitis. These tests are useful during the follow-up of osteomyelitis through serial analysis. The CRP is the first marker to return to normal values in response to a successful treatment.^{7,10,11}

Blood culture is not very useful because its results are negative even in the presence of osteomyelitis, especially when there is no septicemia.¹

The radiological findings are usually normal in the acute phase of the disease, especially during the first two weeks of hematogenous osteomyelitis. The presence of fracture, bone callus or surgical implant may mask specific infectious findings. In the late phase of chronic osteomyelitis, the findings may be atypically well-localized local bone rarefaction or lytic lesions (arising after the destruction of 50 to 75% of the bone matrix). Other abnormalities include formation of visible bone sequestration, bone sclerosis, neoformation and cortical thickening, and periosteal reaction.^{10,12}

Bone scintigraphy with technetium-99 or indium-labeled red blood cells or gallium-67-labeled WBCs or with bone marrow activity markers have been a useful resource for osteomyelitis screening and early diagnosis. These bone scans highlight areas of inflammatory activity; however, there is no consensus on which marker would be the most sensitive for the early detection of osteomyelitis (screening and increased sensitivity).^{10,13,14}

Gallium-67 scintigraphy highlights areas of WBC concentration, usually infection sites, but also tumors. The gallium-67 examination is best suited for osteomyelitis complications, except for the spine.^{13,15} Bone marrow activity can be assessed indirectly by local labeling with technetium-99m colloid in a three-phase examination.

Other markers have been proposed to offer more specific tests for chronic osteomyelitis diagnosis and follow-up, including in biotin for vertebral infections. Radio-labelled ubiquicidin fragments show promise in enhancing bacteria-infected tissues.¹⁴

Computed tomography (CT) may help establish the extension of the bone fragments to the soft tissues, and provide a better characterization of bone sequestration, besides offering detailed images of the cortical bone layer, enabling the evaluation of axial stability.

Magnetic resonance imaging (MRI) enables a detailed study of the extent of the infection, including the soft tissues. The affected areas are often highlighted in T2-weighted hypersignal, such as muscle or subcutaneous tissue secretory collection and bone edema, which characterize an increased inflammatory activity at this site. The MRI enables the earlier detection of acute changes when simple segmental radiographs are normal. In chronic infections, periosteal reactions can be more accurately verified by visualizing lamellar thickening ("onion skin" formation) or, if this process is stopped, it leads to the formation of a "Codman triangle".¹⁰

The test may suffer interference from surgical manipulation and present artifacts due to the presence of metallic implants.^{1,10}

The positron emission tomography (PET) scan with the [18F]-fluoro-2-deoxy-D-glucose (FDG) marker is another promising imaging modality, with high sensitivity (approximately 95%) and specificity (75-99%). This method is limited by its low availability and high cost.¹⁵

In many cases, culture from wound secretion, open fracture and fistula material do not agree with the etiological agent of the osteomyelitis. There is no consensus in the literature if this is a relevant diagnostic method. Treatment based on "wrong" bacteria (identified through culture) can harm the patient, resulting in ineffective antibiotic use, which stimulates the development of resistance.^{9,10}

Affected bone biopsy is the preferred method, especially in chronic osteomyelitis, in which pathogen isolation in the blood is very unlikely.¹⁰ Another diagnostic method is the sonication of surgical implants (including prostheses) removed from infected sites. The material is submitted to preparation and application of ultrasonic waves that structurally break the bacterial biofilm, enabling the molecular identification of the infectious agent.^{16,17} Other microbiology techniques, such as polymerase chain reaction, are also used, but mainly restricted to the academic and research settings.¹⁰

Treatment

Chronic osteomyelitis treatment must be multiphasic, involving three combined strategies: 1) clinical stabilization; 2) antibiotic therapy; and 3) surgical approach.

1. Clinical stabilization

The first step after diagnosis is the improvement of the clinical conditions of the patient, aiming at the control of systemic diseases such as diabetes, malnutrition, immunosuppression and vascular disease.

2. Antibiotic therapy

The antibiotic agent to be used must be inexpensive, convenient in terms of administration and dosage, and offer high serum and bone tissue concentration.^{2,8}

Antibiotics can be used in three ways: systemic, either as prophylaxis or treatment; in an irrigation solution for surgical cleaning; and in a device introduced during the surgical procedure.

Systemic antibiotic therapy

Since systemic antibiotic therapy in open fractures is based on empirical recommendations, studies supporting specific drug classes and treatment duration are required. The literature supports the use of cephalosporin in low contamination fractures and its association with aminoglycosides in more contaminated lesions presenting soft-tissue injury and higher energy trauma. The duration of the treatment is controversial: antibiotics are usually used for one to three days, and extended use is reserved for cases with signs of infection at wound inspection.¹⁰

In a systematic review of the literature, there is no consensus on the use of systemic antibiotics to treat a chronic infection regarding therapy duration and medication choice.¹⁸ Two- to six-week regimen schedules are recommended to enable local wound improvement and revascularization. However, according to other authors, there are guidelines to extend the treatment time to several months.^{1,8}

There are many options of drugs, but there are recommendations based on clinical observations, efficacy studies, accumulated clinical experience, and outcome analyses. Some options have already been established among experts, and are guided by protocols that are widespread in the scientific environment, such as the one developed by Lima and Zumiotti,² in Brazil, and the 2014 Korean Society for Chemotherapy antibiotic therapy protocol for bone and joint infections¹⁹ (–Table 1).

In cases of chronic infection with no sepsis, systemic or limb involvement, the use of antibiotics can be discontinued one week before surgical cleaning and the collection of culture material. An empirical medication is initiated immediately after surgery, and replaced by a specific therapy following the culture and sensitivity results.

In septic patients, antibiotic therapy should be initiated during anesthetic induction for the surgical procedure to be performed (surgical cleaning, which will be discussed later in the present paper), aiming to reduce the risk of bacteremia and its complications, without compromising the results of the bacterial culture from the collected material.^{2,8}

Direct application of antibiotics in surgical wounds

The use of diluted antibiotics in irrigation solutions has shown controversial results, and it represents a considerable increase in treatment cost; as such, it is not routinely recommended.^{1,10}

Antibiotics can be loaded in devices made with surgical polymethyl methacrylate (PMMA) cement. It should be noted that many antibiotics are not heat-resistant, and, therefore, are not suitable for this use because of diminished action. These devices can be used as pearls or cemented rods. Once the antibiotic is absorbed and acts at the infectious site, the PMMA residual device should be removed in a new surgical procedure, since it may serve as a host for a secondary contamination, constituting a new focus for the maintenance of the infection.^{15,20}

Calcium sulfate devices are also a vehicle option for antibiotics, but their results are not consistent.²¹

Another option for PMMA pearls or devices is the antibiotic-loaded artificial biodegradable bone. Researchers from Toronto, Canada have reported it as equivalently effective as PMMA, in addition to being safe and not requiring a new surgery for removal.²²

The medications that can be combined with cement include aminoglycosides and vancomycin; the latter is the most useful in managing operative infections caused by resistant Gram-positive bacteria.⁸

Regarding the concentration of antibiotic released by the device to the tissue, vehicles with larger contact surface (such as small cement beads) enable a better local

Table 1 Main bacterial etiological agents in osteomyelitis and respective antibiotics for treatment

Organism	First-line antibiotic agent	Optional antibiotic agents
<i>Staphylococcus aureus</i> or methicillin-sensitive, coagulase-negative staphylococci	Oxacillin or ceftazolin.	Vancomycin or clindamycin or ampicillin/sulbactam.
Methicillin-resistant <i>S. aureus</i> (MRSA) or methicillin-resistant, coagulase-negative staphylococci	Vancomycin (associated or not with rifampicin) or teicoplanin.	Linezolid or sulfamethoxazole/trimethoprim (associated or not with rifampicin) or daptomycin (associated or not with rifampicin) or tigecycline or clindamycin or fluoroquinolone (associated or not with rifampicin).
<i>Streptococcus spp.</i>	Penicillin or ceftriaxone or ceftazolin or vancomycin.	Clindamycin or vancomycin or fluoroquinolone.
<i>Enterococcus spp.</i>	Penicillin or ampicillin + gentamycin (association).	Ampicillin/sulbactam or linezolid or daptomycin or tigecycline associated with rifampicin.
<i>Pseudomonas spp.</i>	Cefepime or meropenem or imipenem.	Fluoroquinolone.
Extended-spectrum beta-lactamase (ESBL) producing enterobacteria	Ertapenem or imipenem or meropenem.	Ceftriaxone.
Non-ESBL enterobacteria	Ceftriaxone or fluoroquinolone.	Ceftriaxone.
Anaerobic agents	Amoxicillin/Clavulanate or ampicillin/sulbactam or piperacillin/tazobactam.	Metronidazole or clindamycin or meropenem or imipenem.
Aerobic and anaerobic polymicrobial infection	Amoxicillin/Clavulanate.	Ertapenem.

Note: Adapted from Lima and Zumiotti² and from the Korean Society for Chemotherapy¹⁹ antibiotic therapy protocol for bone and joint infections.

distribution of the medication. The peak concentration is usually reached in the first 24 to 48 hours, and it is followed by a steady reduction. Most antibiotics remain at local effective minimum concentration for at least 30 days.²³

Nonabsorbable devices are usually removed in a new surgical procedure after four to eight weeks^{23,24} (→ **Table 2**).

Additional therapies

Hyperbaric oxygen therapy has been used for over 60 years worldwide.²⁵ The treatment involves 100% oxygen respiration under hyperbaric conditions, promoting oxygen entry into the bloodstream and tissue arrival under pressure. Tissue hyperoxygenation has specific therapeutic effects, including the stimulation of bacterial lysis by WBCs, increased proliferation of fibroblasts and collagen in the wound, neovascularization of ischemic or irradiated tissues, immunomodulation with reduction of proinflammatory mediators, and reduction of ischemia-reperfusion effects in ischemic tissues.²⁶ As a result, hyperbaric therapy promotes direct effects for infection control and indirect improvement of wound tissue conditions and healing.²⁵

Surgical treatment

Surgical approaches in chronic osteomyelitis aim to mechanically remove infected and devitalized tissues. In some situations, the patient does not have clinical conditions to continue the surgical treatment (type-C host in the classification of Cierny and Mader).^{3,4,10} It is important to highlight that bone axial stability maintenance must be preserved whenever possible.

Cierny and Mader type 1 (medullary chronic osteomyelitis)

Intramedullary milling followed by canal washing is a recommended therapeutic technique (reamer-irrigator-aspirator, RIA). The use of antibiotic-impregnated intramedullary cement nails has promising results, as does the association with previous milling.²⁷ Bharti et al²⁰ have recently proposed a form of PMMA stem that allows an easier insertion through even the narrowest spinal canal.

The Lautenbach procedure involves the combination of debridement with intramedullary milling and placement of a double-lumen tube/probe, which enables the introduction of antibiotics at the approached site and material collection for laboratory analysis and culture.²⁸

Cierny and Mader type 2 (superficial osteomyelitis)

The main treatment consists of mechanical removal of tissues accompanied by exhaustive cleaning with saline solution to dilute bacterial populations in planktonic form at the site and impair the process of new bacterial adhesion to the surface. Soap-like substances are promising for improved cleanliness, in addition to being harmless.¹⁰ Pulsatile irrigation has the best potential for the mechanical removal of bacteria attached to the site of infection. However, high-pressure irrigation is deemed harmful because it can damage local tissues and lead bacteria to deeper sites.¹ Low pressure irrigation could offer the benefits of cleaning without damage to the site, but there are divergences as to its effectiveness compared to conventional gravity jet cleaning. Some papers report a lower

Table 2 Main antibiotics used with internal devices (including surgical cement) for osteomyelitis treatment, their respective peaks of wound local concentration and duration of available effective dose²³

Antibiotic	Vehicle	Peak concentration	Duration
Gentamicin 10%	Polymethyl methacrylate	3 days	> 30 days with effective dose
Vancomycin 10%	Polymethyl methacrylate	1 day	> 30 days with effective dose
Cefepime 10%	Polymethyl methacrylate	2 days	8 to 9 days with effective dose
Tobramycin 10%	1-tricalcium phosphate-silicate-xerogel	1 day	9 days with effective dose
Ertapenem/ Meropenem 10%	Polymethyl methacrylate	1-2 days	> 30 days, but the dose is below the effective level starting at the 4 th day

cleaning capacity compared to high pressure devices.^{29,30} The use of oxidizing substances is also controversial, as it also results in local tissue damage.¹ Soft tissue coverage must be a priority, and it is often obtained with no difficulty.

Cierny and Mader type 3 (stable, permeative osteomyelitis)

The surgical treatment aims at broad resection of any infected or devitalized bone or soft tissue. This aggressive multidisciplinary surgical approach involves extensive debridement, grafting to cover bone loss and soft tissue coverage with skin flaps, and it has shown good results in some cases, such as in restricted or extensive permeative infections. Internal or external fixation may be required, depending on the volume of resected tissue, in order to maintain axial segment/limb stability. Despite the aggressiveness of the approach and the resources required for this multidisciplinary treatment, researchers from Sydney³¹ and Istanbul³² have obtained good results in infection eradication, with patients resuming work and daily life activities.

Another option recently proposed for cases requiring extensive resection or debridement is the use of PMMA to fill up dead space. The induced membrane or Masquelet technique is a two-step surgical procedure used in the treatment of pseudarthrosis, bone defects and osteomyelitis. The host body forms a membrane around the spacer through a membrane phenomenon followed by increased vascularization and growth factor production (vascular endothelial growth factor [VEGF], transformation growth factor [TGF] beta and bone morphogenetic protein [BMP]-1 and -2). The spacer is then removed in a second surgery, after six to eight weeks, and a cancellous bone graft is introduced to fill the space delimited by the new biological membrane. Stabilization can be achieved with internal fixation with plates and screws, as well as external fixation. Soft tissue coverage can be achieved with a myocutaneous flap if necessary.³³⁻³⁶

Several authors have introduced variants of this technique, including the use of antibiotic-coated spacers, internal fixation during the first step, use of the RIA technique, iliac crest grafting, bone substitutes, and growth factors.^{32,33} However, patients submitted to this technique for bone infections presented a higher risk of surgical complications in other clinical observations.³³

The Papineau technique,³⁷ originally described in 1973, once again became part of the therapeutic arsenal for chronic osteomyelitis treatment since 2006 with the addition of vacuum dressing to the procedure. Such association increases local blood flow, enables interstitial fluid removal, and results in a decrease in bacterial counts in the bed formed after osteomyelitic tissue resection.³⁸

Bioglass is a novel available material that has been used in the surgical treatment of osteomyelitis to manage bone dead space after curettage or resection. It is advocated that changes in tissue pH promoted by bioglass result in an environment that is more favorable to the control of chronic infections.³⁹

Cierny and Mader type 4 (unstable, extensive, permeative osteomyelitis)

Surgical treatment with resection can result in a high volume of tissue loss, requiring microsurgical and bone reconstruction techniques to ensure bone axial stability, soft tissue coverage, and wound closure.⁴⁰ In extreme cases, limb amputation may be necessary for life preservation.¹

A possible option is to install a circular external fixator after resection, enabling bone stretching. Bone transport by distraction osteogenesis is the method of choice for residual bone defects larger than 4 cm in length. Reconstructive and muscle flap techniques enable better bone coverage, and can be used together with the external fixator.^{41,42}

A modern approach to bone transport is its association with the Masquelet technique, which adds the advantages of dead space filling, and the formation of a path for transport; moreover, it prevents graft absorption, and stimulates defect consolidation.³⁶

The use of vascularized fibular grafts is also reported in the literature as an option to manage 5- to 6-cm long tibial bone defects in a poor local vascularization environment such as extensive infection sites.^{43,44}

Final considerations

Osteomyelitis has been the subject of new updates in the medical literature and knowledge accumulation, especially regarding a better understanding of the pathogenic phenomena and the development of postoperative chronic infections, as well as new techniques and options for surgical treatment.

The definition, the historical and the most recently used classifications are well-established and described in the present paper, as well as the pathogenic theories.

The suggestive clinical diagnosis is already well-documented. However, there are new developments regarding the use of laboratory, imaging and microbiological tests for diagnostic confirmation, disease follow-up and collection of important information to guide the treatment. The treatment of chronic osteomyelitis in the long bones presents divergences in clinical and drug management, mainly because many recommendations are not yet based on solid scientific evidence. However, protocols and isolated studies show successful treatment combinations. The surgical treatment has evolved significantly in recent years, with the introduction of new techniques for infectious tissue cleaning, the use of bone substitutes for dead space management and stability maintenance, new fixation implants, and the local use of associated antibiotics.

The knowledge gathered allows us to establish promising combined clinical and surgical treatment strategies that have satisfactory results in various settings. As a result, the mastery of this theme by experts in orthopedics and in infectious diseases enables a better management of patients with chronic osteomyelitis in the long bones.

The present work has gathered the classic information and innovations related to chronic osteomyelitis and its treatment. It offers updated material to assist professionals involved with the treatment of chronic osteomyelitis during the decision-making process.

Conflicts of Interest

The authors have none to declare.

References

- Mast NH, Horwitz D. Osteomyelitis: a review of current literature and concepts. *Oper Tech Orthop* 2002;12(04):232–241
- Lima ALLM, Zumioti AV. Aspectos atuais do diagnóstico e tratamento das osteomielites. *Acta Ortop Bras* 1999;7(03):135–142
- Lew DP, Waldvogel FA. Osteomyelitis. *Lancet* 2004;364(9431):369–379
- Cierny G, Mader JT. Adult chronic osteomyelitis. A review. In: D'Ambrosia RD, Marier RL, editors. *Orthopaedic infections*. Thorofare, NJ: Slack; 1989:31–48
- Cierny G III, Mader JT, Penninck JJ. A clinical staging system for adult osteomyelitis. *Clin Orthop Relat Res* 2003;(414):7–24
- Mader JT, Shirliff M, Calhoun JH. Staging and staging application in osteomyelitis. *Clin Infect Dis* 1997;25(06):1303–1309
- Hake ME, Oh JK, Kim JW, et al. Difficulties and challenges to diagnose and treat post-traumatic long bone osteomyelitis. *Eur J Orthop Surg Traumatol* 2015;25(01):1–3
- Jorge LS, Chueire AG, Rossit ARB. Osteomyelitis: a current challenge. *Braz J Infect Dis* 2010;14(03):310–315
- Mackowiak PA, Jones SR, Smith JW. Diagnostic value of sinus-tract cultures in chronic osteomyelitis. *JAMA* 1978;239(26):2772–2775
- Lazzarini L, Mader JT, Calhoun JH. Osteomyelitis in long bones. *J Bone Joint Surg Am* 2004;86(10):2305–2318
- Alrashidi Y, Galhoun AE, Wiewiorski M, et al. How to diagnose and treat infection in totalankle arthroplasty. *Foot Ankle Clin* 2017;22(02):405–423
- Butt WP. The radiology of infection. *Clin Orthop Relat Res* 1973;96(96):20–30
- Sapienza MT, Hironaka F, Lima ALLM, et al. Avaliação de atividade inflamatória na osteomielite crônica. Contribuição da cintilografia com anticorpos policlonais. *Rev Assoc Med Bras* (1992) 2000;46(02):106–112
- Love C, Palestro CJ. Nuclear medicine imaging of bone infections. *Clin Radiol* 2016;71(07):632–646
- Hogan A, Heppert VG, Suda AJ. Osteomyelitis. *Arch Orthop Trauma Surg* 2013;133(09):1183–1196
- Trampuz A, Piper KE, Jacobson MJ, et al. Sonication of removed hip and knee prostheses for diagnosis of infection. *N Engl J Med* 2007;357(07):654–663
- Piper KE, Jacobson MJ, Cofield RH, et al. Microbiologic diagnosis of prosthetic shoulder infection by use of implant sonication. *J Clin Microbiol* 2009;47(06):1878–1884
- Conterno LO, Turchi MD. Antibiotics for treating chronic osteomyelitis in adults. *Cochrane Database Syst Rev* 2013;(09):CD004439
- Korean Society for Chemotherapy. Korean Society of Infectious Diseases; Korean Orthopaedic Association. Clinical guidelines for the antimicrobial treatment of bone and joint infections in Korea. *Infect Chemother* 2014;46(02):125–138
- Bharti A, Saroj UK, Kumar V, Kumar S, Omar BJ. A simple method for fashioning an antibiotic impregnated cemented rod for intramedullary placement in infected non-union of long bones. *J Clin Orthop Trauma* 2016;7(Suppl 2):171–176
- Luo S, Jiang T, Yang Y, Yang X, Zhao J. Combination therapy with vancomycin-loaded calcium sulfate and vancomycin-loaded PMMA in the treatment of chronic osteomyelitis. *BMC Musculoskelet Disord* 2016;17(01):502
- McKee MD, Li-Bland EA, Wild LM, Schemitsch EH. A prospective, randomized clinical trial comparing an antibiotic-impregnated bioabsorbable bone substitute with standard antibiotic-impregnated cement beads in the treatment of chronic osteomyelitis and infected nonunion. *J Orthop Trauma* 2010;24(08):483–490
- Nandi SK, Bandyopadhyay S, Das P, et al. Understanding osteomyelitis and its treatment through local drug delivery system. *Biotechnol Adv* 2016;34(08):1305–1317
- Gálvez-López R, Peña-Monje A, Antelo-Lorenzo R, et al. Elution kinetics, antimicrobial activity, and mechanical properties of 11 different antibiotic loaded acrylic bone cement. *Diagn Microbiol Infect Dis* 2014;78(01):70–74
- Calzia E, Oter S, Muth CM, Radermacher P. Evolving career of hyperbaric oxygen in sepsis: From augmentation of oxygen delivery to the modulation of the immune response. *Crit Care Med* 2006;34(10):2693–2695
- Marx RE, Ehler WJ, Tayapongsak P, Pierce LW. Relationship of oxygen dose to angiogenesis induction in irradiated tissue. *Am J Surg* 1990;160(05):519–524
- Kanakaris N, Gudipati S, Tosounidis T, Harwood P, Britten S, Giannoudis PV. The treatment of intramedullary osteomyelitis of the femur and tibia using the Reamer-Irrigator-Aspirator system and antibiotic cement rods. *Bone Joint J* 2014;96-B(06):783–788
- Hashmi MA, Norman P, Saleh M. The management of chronic osteomyelitis using the Lautenbach method. *J Bone Joint Surg Br* 2004;86(02):269–275
- Fry DE. Pressure Irrigation of Surgical Incisions and Traumatic Wounds. *Surg Infect (Larchmt)* 2017;18(04):424–430
- Bhandari M, Thompson K, Adili A, Shaughnessy SG. High and low pressure irrigation in contaminated wounds with exposed bone. *Int J Surg Investig* 2000;2(03):179–182
- Campbell R, Berry MG, Deva A, Harris IA, Harris IA. Aggressive management of tibial osteomyelitis shows good functional outcomes. *Eplasty* 2011;11:e3
- Gülabi D, Erdem M, Ceçen GS. Treatment of chronic osteomyelitis of the femur with combined technique. *Ekleml Hastalik Cerrahisi* 2014;25(03):173–178

- 33 Giannoudis PV, Harwood PJ, Tosounidis T, Kanakaris NK. Restoration of long bone defects treated with the induced membrane technique: protocol and outcomes. *Injury* 2016;47(47, Suppl 6):S53–S61
- 34 Wang X, Wang Z, Fu J, Huang K, Xie Z. Induced membrane technique for the treatment of chronic hematogenous tibia osteomyelitis. *BMC Musculoskelet Disord* 2017;18(01):33
- 35 Masquelet AC, Fitoussi F, Begue T, Muller GP. [Reconstruction of the long bones by the induced membrane and spongy autograft]. *Ann Chir Plast Esthet* 2000;45(03):346–353
- 36 Marais LC, Ferreira N. Bone transport through an induced membrane in the management of tibial bone defects resulting from chronic osteomyelitis. *Strateg Trauma Limb Reconstr* 2015;10(01):27–33
- 37 Papineau LJ. L'excision-greffe avec fermeture retardée délibérée dans l'ostéomyélite chronique. *Nouv Presse Med* 1973;2(41):2753–2755
- 38 Archdeacon MT, Messerschmitt P. Modern papineau technique with vacuum-assisted closure. *J Orthop Trauma* 2006;20(02):134–137
- 39 Drago L, Romanò D, De Vecchi E, et al. Bioactive glass BAG-S53P4 for the adjunctive treatment of chronic osteomyelitis of the long bones: an in vitro and prospective clinical study. *BMC Infect Dis* 2013;13:584
- 40 Wu H, Shen J, Yu X, et al. Two stage management of Cierny-Mader type IV chronic osteomyelitis of the long bones. *Injury* 2017;48(02):511–518
- 41 Kojima T, Kohno T, Ito T. Muscle flap with simultaneous mesh skin graft for skin defects of the lower leg. *J Trauma* 1979;19(10):724–729
- 42 Lowenberg DW, Buntic RF, Buncke GM, Parrett BM. Long-term results and costs of muscle flap coverage with Ilizarov bone transport in lower limb salvage. *J Orthop Trauma* 2013;27(10):576–581
- 43 Malizos KN, Zalavras CG, Soucacos PN, Beris AE, Urbaniak JR. Free vascularized fibular grafts for reconstruction of skeletal defects. *J Am Acad Orthop Surg* 2004;12(05):360–369
- 44 Zalavras CG, Femino D, Triche R, Zions L, Stevanovic M. Reconstruction of large skeletal defects due to osteomyelitis with the vascularized fibular graft in children. *J Bone Joint Surg Am* 2007;89(10):2233–2240