

# Intramedullary Flexible Nailing for Diaphyseal Fractures of Forearm Bones in Children\*

## Fixação intramedular flexível para fraturas diafisárias dos ossos do antebraço em crianças

Balakrishnan M. Acharya<sup>1</sup> Pramod Devkota<sup>1</sup>  Abhishek K. Thakur<sup>1</sup> Bidur Gyawali<sup>1</sup>

<sup>1</sup>Department of Orthopedics and Trauma Surgery, Patan Academy of Health Sciences, Patan Hospital, Lalitpur, Nepal

**Address for correspondence** Pramod Devkota, MBBS, MS (Ortho), Department of Orthopaedics and Trauma Surgery, Patan Academy of Health Sciences, Patan Hospital, Lalitpur, Nepal (e-mail: devkotap@gmail.com).

Rev Bras Ortop 2019;54:503–508.

### Abstract

**Objectives** Most of the fractures of the bones of the forearm in children are successfully treated conservatively with closed reduction and casting. The outcomes remain variable and the patients may require additional fracture manipulation or formal surgical intervention due to residual angulations. The present study assesses the radiological and functional outcomes of treating displaced forearm fractures in children with intramedullary flexible titanium elastic nailing.

**Methods** A total of 31 patients aged between 7 and 15 years old with displaced forearm fractures underwent flexible titanium elastic nailing. The patients were followed-up for a mean period of 8.51 months (range: 6–12 months) and were assessed for radiological and functional outcomes. The Price criteria were used to assess the functional outcome.

**Results** Out of 31 patients, 21 patients underwent closed reduction, and 10 required a minimal opening of the fracture site during reduction. A total of 29 patients had excellent results with normal forearm and elbow range of motion (ROM), and 2 patients had good results. In all patients, good radiological union was seen at an average time of 7.9 weeks. Five patients had minor complications, such as skin irritation over the prominent ulnar nail ( $n = 2$ ), superficial nail insertion site infection ( $n = 2$ ), and backing out of the ulnar nail ( $n = 1$ ), requiring early removal.

**Conclusion** Flexible nailing is an efficient application of internal fixation for shaft fractures of both bones of the forearm in children, enabling early mobilization and return to the normal activities of the patients, with low and manageable complications.

### Keywords

- ▶ children
- ▶ forearm injuries
- ▶ fracture fixation intramedullary
- ▶ ulna fractures
- ▶ radius fractures
- ▶ bone nails

### Resumo

**Objetivos** A maioria das fraturas dos ossos do antebraço em crianças é tratada com sucesso de forma conservadora com redução fechada e imobilização gessada. No

\* Study conducted at the Department of Orthopaedics and Trauma Surgery, Patan Academy of Health Sciences, Patan Hospital, Lalitpur, Nepal.

**Palavras-chave**

- ▶ crianças
- ▶ traumatismos do antebraço
- ▶ fixação intramedular de fraturas
- ▶ fraturas da ulna
- ▶ fraturas do rádio
- ▶ pinos ortopédicos

entanto, alguns pacientes podem necessitar de manipulação adicional da fratura ou intervenção cirúrgica devido a angulações residuais. O presente estudo avalia o resultado clínico e radiológico do tratamento de fraturas com desvio do antebraço em crianças fixadas com haste elástica intramedular de titânio.

**Métodos** Um total de 31 pacientes com idades entre 7 e 15 anos com fraturas com desvio do antebraço foram submetidos a haste elástica de titânio flexível. Os pacientes foram acompanhados por um período médio de 8,51 meses (variação: 6–12 meses) e avaliados quanto aos resultados funcionais pelos critérios de Price e radiológicos.

**Resultados** Dos 31 pacientes, 21 foram submetidos a redução fechada e 10 necessitaram de abertura mínima do local da fratura durante a redução. Um total de 29 pacientes tiveram excelentes resultados com arco de movimento normal, e 2 pacientes apresentaram bons resultados. Em todos os pacientes, a consolidação ocorreu em um tempo médio de 7,9 semanas. Cinco pacientes tiveram complicações menores, como irritação da pele sobre a haste proeminente ( $n = 2$ ), infecção superficial do local de inserção no rádio ( $n = 2$ ) e recuo da haste ulnar ( $n = 1$ ), que exigiu remoção precoce.

**Conclusão** A haste flexível é um método eficiente para tratamento da fratura do antebraço em crianças, permitindo mobilização precoce e retorno às atividades normais dos pacientes, com baixas e tratáveis complicações.

**Introduction**

Forearm fractures are the most common long bone fractures in children, comprising ~ 40% of all pediatric fractures.<sup>1</sup> Although fractures of the bones of the forearm are successfully treated conservatively, outcomes remain variable, and, subsequently, some cases may require additional fracture manipulation or formal surgical intervention due to residual angulations.<sup>2–6</sup> Previous studies have shown that the failure of nonoperative treatment of midshaft fractures in pediatric populations ranges between 39 and 64%.<sup>3</sup> Alternatives include closed remanipulation and casting, pins and plaster, closed or mini-open reduction, intramedullary (IM) nailing, and open reduction and internal fixation (ORIF) with plates and screws.<sup>2</sup>

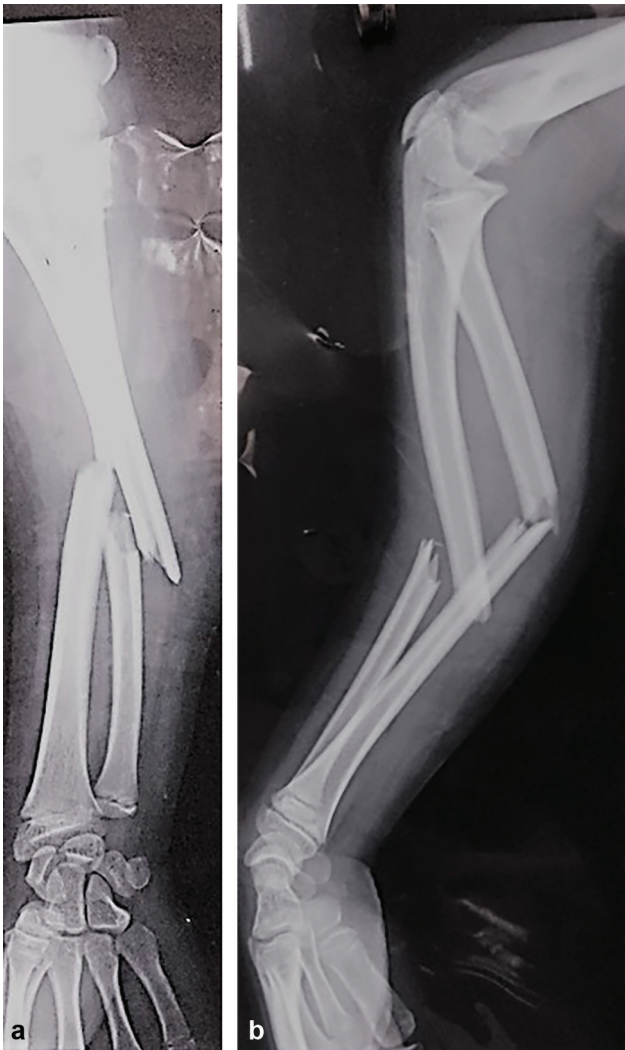Good to excellent results have been reported in several series, leading to widespread enthusiasm regarding IM fixation.<sup>4,7</sup> A number of IM devices, such as Rush nails, Kirshner wires (K-wires), or Ender nails, are available for the treatment of these fractures, but titanium elastic nails have gained wide popularity due to their greater elasticity and better rotational stability than other steel nails.<sup>8,9</sup>

The surgical intervention with flexible nailing has also been increasingly applied in our setup. The present study was performed in order to assess the radiological and functional outcomes, as well as the complications associated with fractures of the bones of the forearm treated with titanium elastic nails in children (► **Fig. 1**).

**Materials and Methods**

This is a retrospective observational study conducted at the Department of Orthopedics and Trauma Surgery of the Patan Hospital, Patan Academy of Health Sciences (PAHS), Lalitpur,

Nepal, from March 2015 to February 2017. The present study was approved by the Institutional Review Committee (IRC) of the Patan Academy of Health Sciences, Patan Hospital, and a written informed consent form was obtained from all of the parents of the patients. The inclusion criteria were children < 15 years old, of both genders, with closed or type I<sup>10</sup> open diaphyseal radius and ulna fractures after failed closed reduction and completely displaced or complete fractures of both bones with angulation > 30° prior to reduction. The exclusion criteria were open fractures other than type I,<sup>10</sup> fractures associated with neurovascular injuries, fractures > 1 week old, greenstick fractures, Monteggia fractures, and pathological fractures. All of the fractures of the bones of the forearm were fixed with titanium elastic nails both for the radius and the ulna using the standard surgical technique and principles using C-arm fluoroscopy. Above elbow plaster was applied for 6 weeks. The cases were followed-up at 2 weeks, 6 weeks, 12 weeks, 24 weeks, and 9 months or 1 year postoperatively. The clinical outcomes were graded according to the system described by Price at the final follow-up.<sup>11</sup> The Price criteria are widely used in the literature to assess the cosmetic and functional outcome of fractures of the bones of the forearm of children. Excellent results are considered those without any complaints on strenuous activities and/or < 10° of loss of forearm rotation; good results are those with mild complaints on strenuous activities and/or a loss between 11° and 30° of forearm rotation. Fair results are those with mild subjective complaints during daily activities and/or a loss between 31° and 90° of forearm rotation; and all others are regarded as poor results. The statistical analysis was performed with IBM SPSS Statistics for Windows, Version 20.0 (IBM Corp., Armonk, NY, USA).



**Fig. 1** (a) Anteroposterior (AP) view and 1(b) lateral view of a 10-year-old boy who sustained both bone forearm fracture of the right side.

## Surgical Technique

The surgery was performed under C-arm fluoroscopy using general anesthesia or regional block, using the operative technique described by Lascombes et al.<sup>12</sup> A skin incision was made 1 cm proximal to the distal radial physis along the wrist crease. The nail was slightly bent at 1 inch from the tip for ease of insertion if the passage across the fracture site was difficult. The radial IM nail was introduced in a retrograde fashion just proximal to the Lister tubercle. Optimal care was taken to protect the extensor tendons and the superficial radial cutaneous nerve. When unable to insert the nail closely, a small incision was made at the fracture site in order to expose the ends of the fracture and achieve the reduction. The ulnar IM nail was introduced in an antegrade fashion through a longitudinal incision made 1 cm distal to the olecranon apophysis. After the insertion of the IM nail, limitation of the forearm pronation and supination was examined intraoperatively to avoid potential rotational malunion. The length of the nail was measured from the proximal to the distal epiphysis under C-arm fluoroscopy,

and the diameter of the nail varied from 2 to 3 mm depending upon the diameter of the medullary cavity at the level of the isthmus. The distal ends of the nails were buried under the skin in all of the cases.

## Results

A total of 31 children, 22 (71.96%) male and 9 (29.03%) female, with fractures of the bones of the forearm, were included in the present study. There were a total of 55 patients who had fractures of both bones of the forearm during the period comprised by the study, and only 43 met the inclusion criteria. However, due to various reasons, such as financial and time constraints of the parents, only 31 patients were operated for IM flexible nail fixation. The mean age of the patients was 12.90 years old (range: 7–15 years old); A total of 25 (80.64%) patients had fractures of the bones of the forearm on the right side, and 6 (19.35%) had fractures on the left side.

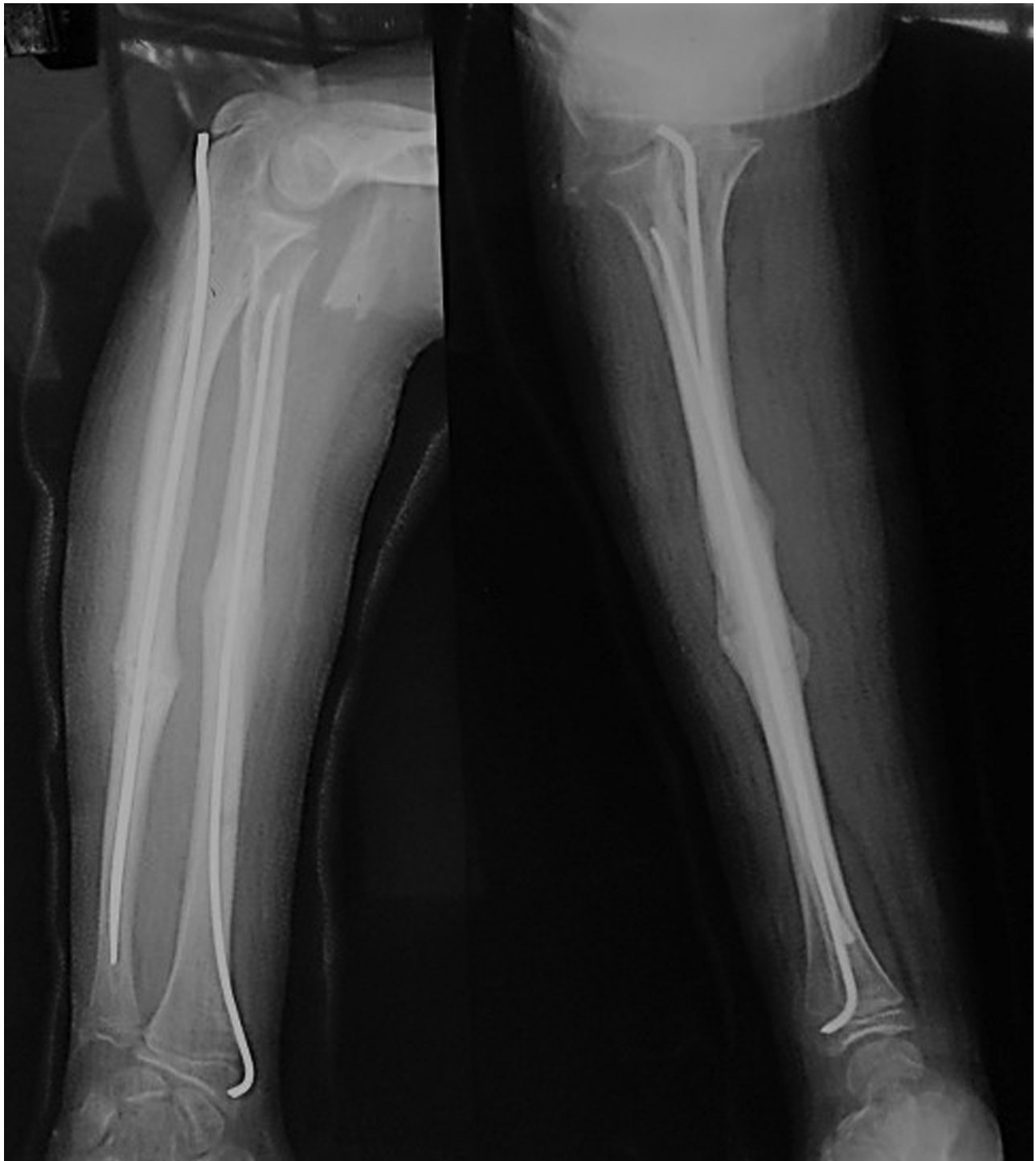
A total of 28 (90.32%) patients had closed fractures, and 3 (9.67%) patients had type I open fractures.<sup>10</sup> The fracture pattern was transverse in 19 (61.29%) patients, oblique in 8 (25.8%) patients, comminuted in 3 (9.68%) patients, and spiral in 1 (3.22%) patient. The fracture location was middle third in 22 (70.97%) patients, proximal third in 6 (19.35%) patients, and distal third in 3 (9.67%) patients. A minimal opening of the fracture site during reduction was required in 10 (32.23%) patients, of whom 6 (19.35%) patients required it only for the ulna, 2 (6.45%) patients required it only for the radius, and 2 (6.45%) patients required it both for the radius and for the ulna.

The patients were followed-up for a mean duration of 8.51 months (range: 6–12 months). The average time to fracture union, which is defined as presence of a bridging callus<sup>13</sup> on anteroposterior (AP) and lateral views of radiographs, was 7.9 weeks (range: 6–12 weeks). According to the Price criteria, excellent results were obtained in 29 (93.55%) patients, and good results were obtained in 2 (6.45%) patients. Among the patients with good outcomes, both had restriction of forearm supination of  $\sim 20^\circ$  in the last follow-up. Out of the 31 patients, 5 (16.12%) patients had minor complications, such as skin irritation over the prominent ulnar hardware in 2 (6.45%) patients, superficial nail insertion site (in the radius) infection in 2 (6.45%) patients, and backing out of the ulnar nail, requiring early removal, in 1 (3.22%) patient. Major complications, such as limb length discrepancy affecting the extremity functions, angular or rotational deformity, synostosis, or restricted elbow movement, were not encountered.

Removal of the implants was performed in 10 patients (32.3%), and the remaining cases are still under follow-up. The average time of removal was 7 months (range: 6–10 months) (→ Fig. 2).

## Discussion

Most pediatric forearm fractures can be managed nonoperatively by closed reduction and casting.<sup>13–16</sup> Midshaft



**Fig. 2** Anteroposterior and lateral view - the good union of the fracture of the same child 6 weeks after the operation.

diaphyseal fractures and those that are proximal do not remodel predictably; therefore, these require a more anatomic reduction.<sup>14</sup> Controversy exists as to which amount of angulation, displacement, and rotation constitutes an acceptable reduction. Younger patients can tolerate more deformity than older children.<sup>16-18</sup>

In the present study, the majority of children were boys and had fractures on the right side, which is in line with other studies.<sup>14,19</sup> The mean age of the patients was 12.9 years old

in our study; Flynn et al reported 10.6 years old, and Yalcinkaya et al reported 10 years old.<sup>14,19</sup>

A minimal opening of the fracture site during reduction was required in 32.23% of the cases; Parajuli et al<sup>20</sup> reported that 38% cases needed open reduction, and Borges et al<sup>21</sup> reported that 13.33% cases needed open reduction. The mean follow-up period in our study was of 8.5 months, and the average time for union was of 7.9 weeks. Yalcinkaya et al<sup>19</sup> reported between 6 and 8 weeks, and Flynn et al<sup>14</sup> reported 6.9 to 8 weeks; these



results were similar to those of our study. We used the Price criteria for the functional evaluation, and obtained 93.55% excellent results and 6.45% good results. Other authors have also reported similar results.<sup>13,19,20</sup> Using the Price criteria, Shoemaker et al<sup>13</sup> reported 96.8%, Yalcinkaya et al<sup>19</sup> reported 82.2%, and Parajuli et al<sup>20</sup> reported 94% excellent results, respectively. Until now, the removal of the implants has been done on an average of 7 months after the operation; Parajuli<sup>20</sup> reported the removal of the implants 6 months after the operation, which is comparable to our study.

Parameters for accepting rotational malalignment range from 30° to 45° to none, and some authors have noted that rotational remodeling is not predictable.<sup>2,13,18,22</sup> Daruwalla<sup>23</sup> recommended operative intervention for midshaft and proximal forearm fractures with angulations > 10° due to the limited remodeling potential in these areas of the bone. Residual deformities can affect the motion of the forearm. Mathews et al showed in a cadaveric study that forearm angular deformities of 10° will not result in significant loss of forearm pronation/supination, but that an angulation of 20° will restrict the rotation of the forearm in ~ 30%.<sup>24</sup> Another cadaveric study by Tarr et al<sup>25</sup> demonstrated that a fracture angulation between 5° and 10° at the midshaft of the forearm can lead to a pronation deficit of between 5 and 27%. Given the potential failure of nonoperative management (from 1.5 to 31%) and the importance of minimizing angular deformity to preserve the normal rotation of the forearm, operative management of pediatric fracture of the forearm has been increasingly popular.<sup>25</sup>

When indicated, operative fixation of pediatric forearm fractures is usually effective, regardless of the method of fixation.<sup>13,14,22,24,26</sup> Flexible IM nailing is the preferred fixation method for pediatric forearm fractures. Most series show good to excellent results using this method.<sup>13,14,19,24,26</sup> Closed reduction or open reduction before IM nailing yield similar functional results, with a similar complication profile in pediatric diaphyseal fractures.<sup>19</sup> In the present study, 10 patients required a minimal opening of the fracture site during reduction due to an interposition of soft tissue or to difficult cannulation due to callus formation. Although we did not compare the results of closed versus open technique, we have included both techniques, for which the results are good to excellent.

The complications in the present study are comparable to those observed in other several studies. Yalcinkaya et al reported that the complications rate ranged from 4 to 38% in patients treated with IM nailing, and Flynn et al showed that the overall complication rate in patients undergoing IM nailing was of 14.6%.<sup>14,19</sup> The most common complication occurring in their series were delayed union, compartment syndrome, infection, skin irritation by hardware, and pin back out. In our series, minor complications were noted in 5 (16.12%) patients. No nonunion or malunions occurred, and no deep infections were noted, which was in line with other studies.<sup>13,14,19,20</sup>

One limitation of the present study is its noncomparative nature. A similar study with a nonoperative control group or a comparative study with another operative technique with a longer follow-up would be ideal for a definite conclusion.

## Conclusion

Flexible nailing is a versatile and efficient application of internal fixation for shaft fractures of both bones of the forearm in children, enables early mobilization and consolidation, has an excellent functional outcome, and manageable complications. It is a valid alternative for the treatment of displaced shaft fractures of both bones of the forearm in children.

## Conflicts of Interests

The authors have no conflicts of interests to declare.

## References

- 1 Beaty JH, Kasser JR. Rockwood and Wilkins fractures in children. 7th ed. Philadelphia: Lippincott Williams & Wilkins; 2010
- 2 Smith VA, Goodman HJ, Strongwater A, Smith B. Treatment of pediatric both-bone forearm fractures: a comparison of operative techniques. *J Pediatr Orthop* 2005;25(03):309-313
- 3 Bowman EN, Mehlman CT, Lindsell CJ, Tamai J. Nonoperative treatment of both-bone forearm shaft fractures in children: predictors of early radiographic failure. *J Pediatr Orthop* 2011; 31(01):23-32
- 4 Reinhardt KR, Feldman DS, Green DW, Sala DA, Widmann RF, Scher DM. Comparison of intramedullary nailing to plating for both-bone forearm fractures in older children. *J Pediatr Orthop* 2008;28(04):403-409
- 5 Volpon JB. Osteossíntese das fraturas diafisárias da criança com hastes intramedulares flexíveis. *Rev Bras Ortop* 2008;43(07): 261-270
- 6 Alvachian Fernandes HJ, Saad EA, Reis FB. Osteosynthesis with intramedullary nails in children. *Rev Bras Ortop* 2015;44(05): 380-385
- 7 Westacott DJ, Jordan RW, Cooke SJ. Functional outcome following intramedullary nailing or plate and screw fixation of paediatric diaphyseal forearm fractures: a systematic review. *J Child Orthop* 2012;6(01):75-80
- 8 Wall L, O'Donnell JC, Schoenecker PL, et al. Titanium elastic nailing radius and ulna fractures in adolescents. *J Pediatr Orthop B* 2012; 21(05):482-488
- 9 Barry M, Paterson JM. A flexible intramedullary nails for fractures in children. *J Bone Joint Surg Br* 2004;86(07):947-953
- 10 Gustilo RB, Anderson JT. Prevention of infection in the treatment of one thousand and twenty-five open fractures of long bones: retrospective and prospective analyses. *J Bone Joint Surg Am* 1976;58(04):453-458
- 11 Price CT, Scott DS, Kurzner ME, Flynn JC. Malunited forearm fractures in children. *J Pediatr Orthop* 1990;10(06):705-712
- 12 Lascombes P, Prevot J, Ligier JN, Metaizeau JP, Poncelet T. Elastic stable intramedullary nailing in forearm shaft fractures in children: 85 cases. *J Pediatr Orthop* 1990;10(02):167-171
- 13 Shoemaker SD, Comstock CP, Mubarak SJ, Wenger DR, Chambers HG. Intramedullary Kirschner wire fixation of open or unstable forearm fractures in children. *J Pediatr Orthop* 1999;19(03): 329-337
- 14 Flynn JM, Jones KJ, Garner MR, Goebel J. Eleven years experience in the operative management of pediatric forearm fractures. *J Pediatr Orthop* 2010;30(04):313-319
- 15 Rodríguez-Merchán EC. Pediatric fractures of the forearm. *Clin Orthop Relat Res* 2005;(432):65-72
- 16 Wilkins KE. Operative management of children's fractures: is it a sign of impetuosity or do the children really benefit? *J Pediatr Orthop* 1998;18(01):1-3
- 17 Schmittbecher PP. State-of-the-art treatment of forearm shaft fractures. *Injury* 2005;36(Suppl 1):A25-A34

- 18 Teoh KH, Chee YH, Shortt N, Wilkinson G, Porter DE. An age- and sex-matched comparative study on both-bone diaphyseal paediatric forearm fracture. *J Child Orthop* 2009;3(05):367–373
- 19 Yalçinkaya M, Doğan A, Ozkaya U, Sökücü S, Uzümcügil O, Kabukçuoğlu Y. Clinical results of intramedullary nailing following closed or mini open reduction in pediatric unstable diaphyseal forearm fractures. *Acta Orthop Traumatol Turc* 2010;44(01):7–13
- 20 Parajuli NP, Shrestha D, Dhoju D, Dhakal GR, Shrestha R, Sharma V. Intramedullary nailing for paediatric diaphyseal forearm bone fracture. *Kathmandu Univ Med J (KUMJ)* 2011;9(35):198–202
- 21 Borges JLP, Silva VC, Penteadó LH. Fixação intramedular das fraturas do antebraço em crianças. *Rev Bras Ortop* 1996;31(01):41–45
- 22 Richter D, Ostermann PA, Ekkernkamp A, Muhr G, Hahn MP. Elastic intramedullary nailing: a minimally invasive concept in the treatment of unstable forearm fractures in children. *J Pediatr Orthop* 1998;18(04):457–461
- 23 Daruwalla JS. A study of radioulnar movements following fractures of the forearm in children. *Clin Orthop Relat Res* 1979;(139): 114–120
- 24 Matthews LS, Kaufer H, Garver DF, Sonstegard DA. The effect on supination-pronation of angular malalignment of fractures of both bones of the forearm. *J Bone Joint Surg Am* 1982;64(01):14–17
- 25 Tarr RR, Garfinkel AI, Sarmiento A. The effects of angular and rotational deformities of both bones of the forearm. An in vitro study. *J Bone Joint Surg Am* 1984;66(01):65–70
- 26 Garg NK, Ballal MS, Malek IA, Webster RA, Bruce CE. Use of elastic stable intramedullary nailing for treating unstable forearm fractures in children. *J Trauma* 2008;65(01):109–115